

Giant Prolactinoma –A Case Report

Nanda Patil¹, Parneet Kaur², Parin Upadhyay^{2*}

¹Professor, Department of Pathology, Krishna Institute of Medical Sciences, Karad, Maharashtra, India

²Tutor, Department of Pathology, Krishna Institute of Medical Sciences, Karad, Maharashtra, India

DOI: [10.36347/sjmcr.2020.v08i09.009](https://doi.org/10.36347/sjmcr.2020.v08i09.009)

| Received: 28.08.2020 | Accepted: 04.09.2020 | Published: 12.09.2020

*Corresponding author: Dr. Parin Upadhyay

Abstract

Case Report

Nonfunctioning pituitary tumors though detected frequently, they are diagnosed late when they grow large in size producing pressure effects and compression syndrome as headache, visual disturbances and hypopituitarism. These tumors can reach enormous size and infiltrate adjacent structures like brain tissue, dura, sphenoid bone and cavernous sinus. We report a case of Giant Prolactinoma in a fifty years old postmenopausal patient.

Keywords: Prolactinoma, Giant, Hypopituitarism.

Copyright @ 2020: This is an open-access article distributed under the terms of the Creative Commons Attribution license which permits unrestricted use, distribution, and reproduction in any medium for non-commercial use (NonCommercial, or CC-BY-NC) provided the original author and source are credited.

INTRODUCTION

Prolactinoma is a benign pituitary neoplasm which comprise 40% of pituitary tumors [1].

These tumors exhibit lactotrophs which secrete excess prolactin resulting in hyperprolactinemia. We report a case of Giant Prolactinoma to emphasis its mass effect.

CASE REPORT

A 50 years old female patient presented with headache and visual disturbances since 3 weeks. Patient had history of hysterectomy 10 years back. MRI revealed a large well defined sellar and suprasellar mass producing mass effect on optic chiasma with further extensions (Fig-1).

Hormonal status of patient was done. Prolactin levels were 47.14 ng/ml (4.79-23.30 ng/ml).

FSH levels, Serum Cortisol levels and Growth Hormone levels were 3.86 IU/L (25.8-134 IU/L), 0.77um/dl (4.30-22.4 um/dl) and <0.05 ng/ml (0.02-18ng/ml) respectively.

The tumor was partially excised to reduce the mass effect and sent for histopathological diagnosis.

Histopathological Examination

The tumor was received in a form of multiple grey white soft tissue bits aggregate measuring 4.7 x3 x 3 cm and weighs 50 gms (Fig-2). Histopathological examination revealed bits of tumor tissue composed of

uniform round to polygonal neoplastic cells arranged in sheets and cords with round regular nuclei and scant to moderate eosinophilic cytoplasm. Focal areas revealed microcysts and calcification (Fig-3). Considering these features the diagnosis was given as Giant Prolactinoma.

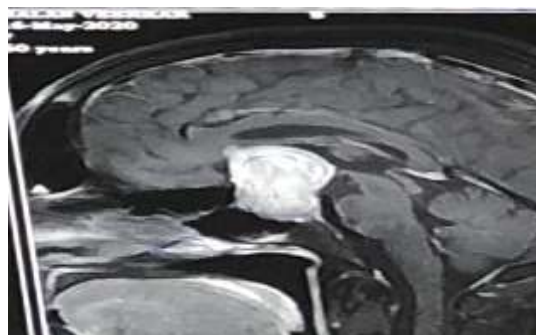


Fig-1: Large well defined sellar and suprasellar mass



Fig-2: Gross examination. Multiple grey white soft tissue bits of tumor

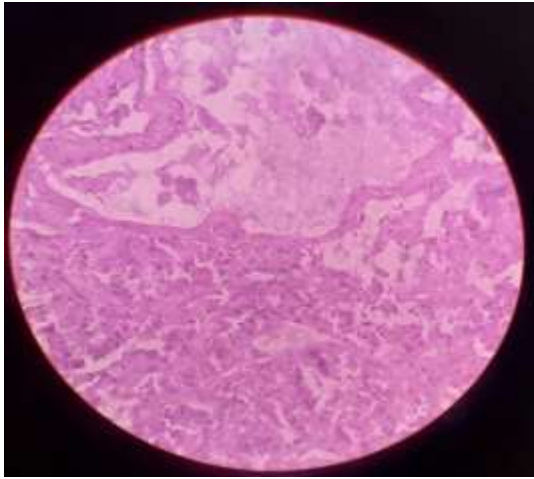


Fig-3: Neoplastic cells arranged in cords and microcystic areas (100X H &E)

DISCUSSION

Pituitary adenoma represent 10-15 % of all primary brain tumors [2]. Although benign, some tumors can produce mass effect because of their size such as headache, visual disturbances and impaired pituitary function such as hypopituitarism [3]. Our case also presented with similar clinical features. Prolactinomas are benign pituitary tumors accounting for 40% of pituitary tumors. They can be microadenoma (<10 mm diameter) or macroadenoma (>10 mm diameter). Most of them are intrasellar, in few cases, they invade surrounding structures. They are called giant when >30 mm suprasellar extension is seen [4].

Our case also revealed a large tumor producing mass effect compressing optic chiasma. Prolactinomas secrete excess prolactin resulting in hyperprolactinemia. Increase prolactin levels lead to gonadal dysfunction, infertility, amenorrhoea and galactorrhea. Large prolactinomas cause compression of adjacent pituitary tissue and hypopituitarism [5, 6]. Postmenopausal women often do not present with these typical symptoms but rather of symptoms of mass effect with large tumors [7]. Similar observation was seen in our case.

The diagnosis of prolactinoma requires endocrinological investigations with evidence of hyperprolactinemia and radiologic evidence of pituitary adenoma [8]. Transsphenoidal resection is the treatment of choice for large prolactinomas. These tumors may recur after surgery hence proliferative markers like Ki67 and hormonal status are useful for follow up. Ki67 and P53 are referred as indicators for aggressive behavior [9, 10].

Although medical management plays role in the treatment of some functioning adenomas, this is not helpful for non functioning tumors.

CONCLUSION

Prolactinomas are pituitary adenomas which cause hyperprolactinemia. They can be microadenomas or macroadenomas. Giant Prolactinomas produce mass effects and surgical removal is the treatment of choice. Ki67 & P53 are useful prognostic markers for aggressive behaviour and recurrence.

REFERENCES

1. Sisam DA, Sheehan JP, Sheeler LR. The natural history of untreated microprolactinomas. *Fertil Steril.* 1987;48(1), 67-71.
2. Ambrosi B, Fagila G, Multicenter Pituitary Tumor Study Group, Lombardia Region. Epidemiology of pituitary tumors. In: Fagila G, Beck-Peccoz P, Ambrosi A, Travaglini P, Spada A, editors. *Pituitary Adenomas: New Trends in Basic and clinical Research.* Amsterdam: Excerpta Medica; 1999: 159-68.
3. Buchfelder M. Management of aggressive pituitary adenomas: Current treatment strategies. *Pituitary.* 2009; 12:256-60.
4. Knosp E, Steiner E, Kitz K, Matula C. Pituitary adenomas with invasion of the cavernous sinus space: A magnetic resonance imaging classification compared with surgical findings. *Neurosurgery.* 1993; 33:610-7.
5. Dorrington J, Gore-Langton RE. Prolactin inhibits oestrogen synthesis in the ovary. *Nature.* 1981; 290(5807):600-602.
6. Moulton PJ, Rees LH, Besser GM. Pulsatile gonadotrophin secretion in hyperprolactinaemic amenorrhoeas and the response to bromocriptine therapy *Clin. Endocrinol. (Oxf.).* 1982; 16(2):153-162.
7. Nassiri F, Cusimano MD, Scheithauer BW, Rotondo F, Fazio A, Syro LV, Kovacs K, Lloyd RV, Sisam, Dorrington, Moulton. Prolactinomas: diagnosis and treatment. *Expert review of endocrinology & metabolism.* 2012 Mar 1;7(2):233-41.
8. Melmed S, Casanueva FF, Hoffman AR, Kleinberg DL, Montori VM, Schlechte JA, Wass JA. Diagnosis and treatment of hyperprolactinemia: an Endocrine Society clinical practice guideline. *The Journal of Clinical Endocrinology & Metabolism.* 2011 Feb 1;96(2):273-88.
9. Dubois S, Guyetant S, Menei P, Rodien P, Illouz F, Vielle B, Rohmer V. Relevance of Ki-67 and prognostic factors for recurrence/progression of gonadotropic adenomas after first surgery. *European journal of endocrinology.* 2007 Aug 1;157(2):141-7.
10. Gejman R, Swearingen B, Hedley-Whyte ET. Role of Ki-67 proliferation index and P53 expression in predicting progression of pituitary adenomas. *Hum Pathol.* 2008; 39:758-66.