

Research Article**Prevalence of Benign Lesions of Vocal Cord in Patients with Hoarseness – A Cross Sectional Study****Kiran Kumar Chinthapeta¹, M.K. Srinivasan², K Muthu Babu³, Asim Pa⁴, G. Jeeva⁵, C. Sampath⁶**¹Senior Resident, ENT Department, Rajiv Gandhi Institute of Medical Sciences, Ongole, A.P²Professor of ENT, Meenakshi Medical College and Research Institute, Kanchipuram, T.N³Assistant professor of ENT, Meenakshi Medical College and Research Institute, Kanchipuram⁴⁻⁵PG Student, Meenakshi Medical College and Research Institute, Kanchipuram, Tamilnadu⁶Consultant Eye Surgeon, Sampath Eye Clinic, Sri Kalahasti, Andhra Pradesh***Corresponding author**

Dr Kiran Kumar Chinthapeta

Email: drckiranent@gmail.com

Abstract: Hoarseness of voice due to vocal lesions has deep impact on the emotional and work-related aspects of survival. Various studies opined that true benign neoplastic lesions are uncommon and occur in a ratio of 1:6 to the non-neoplastic lesions. To this rationale we studied the prevalence of different benign lesions in vocal cords causing hoarseness in patients attending ENT OPD clinic in a tertiary care hospital. The method in this study was conducted at Meenakshi Medical College And Research Institute, during the period 2012 – 2014. Fifty patients of age between 5 years to 50 years attending the outpatient department of ENT were enrolled. Patients having hoarseness of voice and or dysphagia were included. All the patients with hoarseness of voice were evaluated for benign lesions by using Flexible video laryngoscopy and data was studied. Statistical analysis was performed using Chi – square test and student’s “t” test. A p value less than 0.05 was considered statistically significant. In results the highest incidence of hoarseness was observed between the groups of 41 – 50 years. There were 17 females and 33 males. 36/50 patients had a history of vocal stress, among them 28 patients had benign lesions on the vocal cord. 50/50 patients were having hoarseness of voice, dysphagia was found in 26 patients and 34 patients were with benign lesions (structural abnormality). The most prevalent type of lesion found is vocal nodule (24%). The conclusion in the present study of prevalence of benign lesions on the vocal cord with hoarseness, benign lesions constituted up to 68%. Vocal stress is the most common underlying etiologic factor. Teaching profession appeared to be the common occupational group having the benign lesions of the vocal cord presenting as hoarseness. The maximum incidence of benign lesions was found in the age group of 41 - 50 years, Males had higher incidence of hoarseness when compared to females. Hoarseness was present in all the patients with benign lesions of the vocal cord. Non - neoplastic lesions appeared to be common among benign lesions with hoarseness. Bilateral Vocal cord nodules appeared to be the most prevalent type of benign lesion presenting with hoarseness.

Keywords: Hoarseness of voice, Vocal cord nodules, teaching profession

INTRODUCTION

Speech is one of the exclusive characters that place humans apart from all other living organisms [1]. Hoarseness of voice due to vocal lesions has deep impact on the emotional and work-related aspects of survival. It becomes easy to appreciate the act of phonation and vocal cord abnormalities with advancement of microscope and stroboscope [2]. The benign laryngeal lesions occur in a ratio of 2:3 to the malignant lesions. Various studies opined that true benign neoplastic lesions are uncommon and occur in a ratio of 1:6 to the non-neoplastic lesions [3]. Some of these tumors may even undergo malignant changes like papilloma (4%), granular cell tumor (2%) [4-5]. To this rationale we studied the prevalence of different benign

lesions in vocal cords causing hoarseness in patients attending ENT OPD clinic in a tertiary care hospital.

METHODS

This study was conducted at Meenakshi Medical College And Research Institute, Kanchipuram during the period 2012 – 2014. Fifty patients of age between 5 years to 50 years attending the outpatient department of ENT were enrolled. Patients having hoarseness of voice and or dysphagia were included. Patients with hoarseness and other symptoms, Professional voice users and singers with hoarseness were also included. Patients with laryngeal malignancies, critically ill patients, children below 5 years, older than 50 years, patients who have undergone laryngeal surgeries or tracheostomy, patients with

history neck injuries were excluded. All the patients involved were explained about the procedure and involvement in this study and a voluntary informed consent was obtained for the same. Each patient underwent physical examination and ENT examination which includes indirect laryngoscopy, flexible video laryngoscopy and if necessary micro-laryngeal surgery and biopsy. Other laboratory, radiological examination as judged by clinician was also performed. Among the fifty patients studied, 34 patients with structural abnormality underwent Micro laryngeal surgery under general anesthesia. 16 were treated conservatively, among them, 9 patients were treated by medical management which included Proton pump inhibitors, antibiotics and life style modifications. 7 patients with normal study were managed by voice therapy.

Statistical Analysis

Data was presented as mean & SD, actual numbers and percentages. Statistical analysis was performed using Chi – square test and student’s “t” test. A p value less than 0.05 was considered statistically significant.

RESULTS

The highest incidence of hoarseness was observed between the group of 41 – 50 years (21 cases out of 50 cases studied), followed by the 31 – 40 years age group. There were 17 females and 33 males. 36/50 patients had a history of vocal stress, among them 28 patients had benign lesions on the vocal cord. 50/50 patients were having hoarseness of voice, dysphagia was found in 26 patients and 34 patients were with benign lesions (structural abnormality). The most prevalent type of lesion found is vocal nodule (12 patients). Nine patients were having GERD, 2 patients with dysphonia plica ventricularis, 1 patient with muscle tension dysphonia, 1 patient with right vocal cord palsy and 3 patients were having normal study results. The incidence of benign lesions was more in higher age group p value=0.045. 33 patients with benign lesions on the vocal cord were found to be males p<0.05. 22 patients with dysphagia had benign lesions on the vocal cord, p=0.009. And hence this test signifies the association between dysphagia and structural abnormality.

Table-1: Demographic and Clinical parameters

	Cases	%
Age Group (Yrs)		
11-20	2	4
21 - 30	10	20
31 - 40	17	34
Total	50	100
Gender		
Male	33	66
Female	17	34
Vocal Stress		
Yes	36	72
No	14	28
Hoarseness		
Only Hoarseness	50	100
Hoarseness + Dysphagia	26	52
Hoarseness +Stridor	1	2
Structural Abnormality		
Yes	34	68
No	16	32
Other Etiologies		
Dysphonia Plica Ventricular is	2	12.5
GERD	9	56.3
Muscle Tension Dysphonia	1	6.3
Right Vocal Cord Palsy	1	6.3
Normal Study	3	18.8
Benign Lesions		
Vocal Cord Nodule	12	24
Vocal Cord Polyp	9	18
Vocal Cord Cyst	5	10
Sulcus Vocalis	1	2
Chronic Laryngitis	2	4
TB Laryngitis	2	4
Leukoplakia	1	2
Respiratory Papillomatosis	1	2
Reinke'S Edema	1	2
Total	34	100

Table-2-Correlation between Benign Lesions

Sex	Yes	No	Total	P =0.023
Males	26	7	33	
Females	8	9	17	
Total	34	16	50	
Vocal Stress				
	Yes	No	Total	P =0.017
	28	8	36	
	6	8	14	
	34	16	50	
Dysphagia				
	Present	Absent	Total	P =0.009
	22	4	24	
	12	12	26	
	34	16	50	

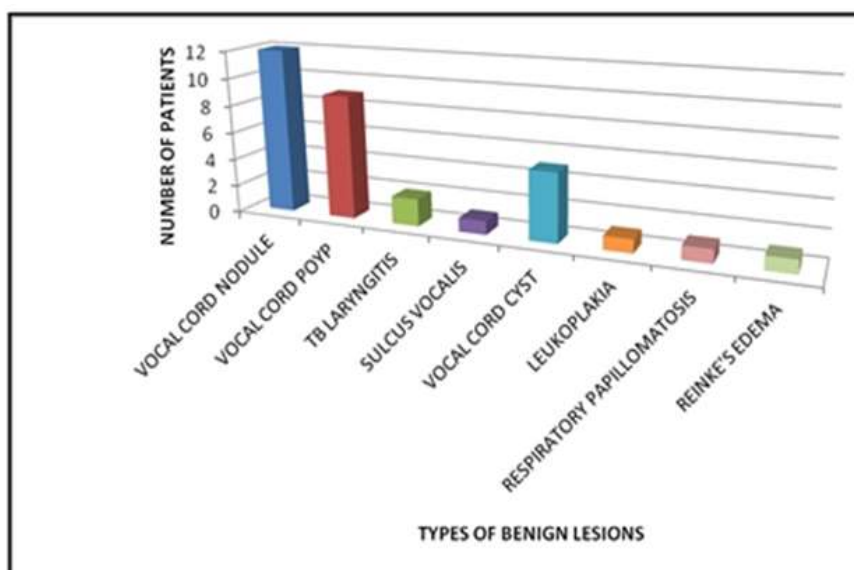


Fig 1: Types of benign lesions

DISCUSSION

New GB and Erich GB [6] have published in the Mayo Clinic, the experiences of 722 patients presenting with benign laryngeal pathology. Since then, some authors have revised the concept, classifying vocal fold nodules, polyps, cyst and nonspecific granulomas to be mucosal reactive inflammatory disorders and therefore non-neoplastic in nature. Hegde MC *et al.*; [7] and Singhal P *et al.*; [8] in their study reported maximum number of the patient in the age group of 20 to 40 years. Whereas in our study the maximum incidence of benign lesions were found in the age group of 41 - 50 years which is considered important period of life.

In our study 76% of cases Males had higher incidence of hoarseness when compared to females, which was supported by Stewart JP *et al.*; (9), Chopra *et al.*; [10] and Batra *et al.*; [11] who also showed male preponderance. Singhal P *et al.*; [7] in his study found the most common occupation of suffering with hoarseness with benign lesions were imams of mosque and temple singers which are housewives in a study by

but in our study teaching profession appeared to be the common occupational group having the benign lesions of the vocal cord presenting as hoarseness.

CONCLUSION

In the present study of prevalence of benign lesions on the vocal cord with hoarseness, benign lesions constituted up to 68%. Vocal stress is the most common underlying etiologic factor. Teaching profession appeared to be the common occupational group having the benign lesions of the vocal cord presenting as hoarseness.

Maximum incidence of benign lesions were found in the age group of 41 - 50 years followed by the 31-40 years age group, together accounting for 76% of cases Males had higher incidence of hoarseness when compared to females. Hoarseness was present in all the patients with benign lesions of the vocal cord. Non - neoplastic lesions appeared to be common among benign lesions with hoarseness. Bilateral Vocal cord nodules appeared to be the most

prevalent type of benign lesion presenting with hoarseness.

Limitations of the study

Light transport and magnification of the image are inferior to those of rigid endoscopy. There is also a distortion of the periphery of the image and a trade-off between adequate focus and light fiber mismatch, so that when the image was in focus, there was a moiré or honeycomb effect that was enhanced by the edge-detection software of digital imaging systems. In addition, many patients find the flexible examination to be more invasive than the rigid examination, and the flexible technique carries the risks of nose bleed, adverse reactions to the anesthetic and vaso vagal reaction.

REFERENCES

1. Benign vocal fold mucosal disorders: Cummings the otolaryngology Head Neck Surgery, Volume 1, 5 edition, No 859 – 882
2. Julian McGlashan; Disorders of Voice; Scott Brown's Otorhino laryngology, Head and Neck Surgery, 7 edition, Vol 2, 2190-2205.
3. Doloi PK, Khanna S; A Study of Management of Benign Lesions of the Larynx. International Journal of Phonosurgery and Laryngology, 2011; 1(2):61-64
4. Winston P, Epstein SS; Papilloma of the larynx: A clinico pathological study. J Laryngol Otol 1958; 72:452-64.
5. Sataloff RT, Ressue JC, Portell M, Harris RM, Ossoff R, Merati AL, *et al.*; Granular cell tumors of the larynx. J Voice Mar, 2000; 14(1):119-34.
6. New GB, Erich JB; Dermoid cysts of the head and neck. Surg Gynecol Obstet.1937; 65:48.
7. Hegde MC, Kamath PM, Bhojwani K, Peter R, Babu PR; Benign lesions of the larynx: A clinical study. IJLO, 2005; 57(1):35-38.
8. Singhal P, Bhandari A, Chouhan M, Sharma MP, Sharma S; Benign tumors of the larynx: A clinical study of 50 cases. IJLO, 2009; 61(1):26-30.
9. Stewart JP; The histopathology of benign tumors of the larynx. J Laryngol Otol, 1957; 71:718-29.
10. Chopra H, Kapoor M; Study of benign glottic lesions undergoing micro laryngeal surgery. Indian Journal of Otolaryngology and Head and Neck Surgery, 1997; 49(3):276-79.
11. Batra K, Motwani Ani G, Sagar PC; Functional voice disorders and their occurrence in 100 patients of hoarseness as seen in oil fibreoptic laryngoscopy. Indian J Otolaryngol Head and Neck Surgery, 2004; 56(21):91-95.