

Intrusion of Maxillary Incisors with Mini Implants

Sharath Kumar Shetty¹, Mahesh Kumar Y², P.K. Saksharaa Priyadarshini³, Kiran Kumar C⁴¹Professor and Head, Department of Orthodontics and Dentofacial Orthopaedics, KVG Dental College and Hospital, Sullia²Professor, Department of Orthodontics and Dentofacial Orthopaedics, KVG Dental College and Hospital, Sullia³Postgraduate Student, Department of Orthodontics and Dentofacial Orthopaedics, KVG Dental College and Hospital, Sullia⁴Professor, Department of Orthodontics and Dentofacial Orthopaedics, KVG Dental College and Hospital, Sullia

Case Report

*Corresponding author

PK Saksharaa
Priyadarshini

Article History

Received: 12.02.2018

Accepted: 19.02.2018

Published: 28.02.2018

DOI:

10.21276/sjds.2018.5.2.9



Abstract: In recent years, the integration of mini implants into intrusion mechanics has been proposed as an alternative technique to conventional mechanics. The present article tries to give an insight on the versatility of mini implants in intrusion and gain clarity regarding the amount of intrusion obtained relative to the position of mini implants. Though there are many studies documented, their results remain inconclusive. Hence, this article tries to give a comprehensive review of the use of mini implants in correcting deep bite.

Keywords: Intrusion, mini implants, deep bite, gummy smile.

INTRODUCTION

A deep bite is a complex orthodontic problem that is a common feature of many malocclusions [1]. The deep bite could be the result of reduced lower facial height and lack of eruption of the posterior teeth or due to over eruption of the anterior teeth [2]. Non-surgical treatment strategy for deep bite correction includes intrusion of anteriors, extrusion of posteriors or both [3].

Depending on the diagnosis and treatment objectives, a deep bite can be corrected by intruding the incisors, extruding the buccal segments, or combining these treatments [4]. The treatment for patients with normal vertical development and gummy smiles involves maxillary incisor intrusion [5].

Conventional methods of incisor intrusion usually involve 2 × 4 appliances such as utility arches, 3-piece intrusion arches, or reverse curved arches [5].

It is a well-known fact that correction of deep bite by extrusion of posterior teeth is difficult to accomplish in non-growing individuals having a hypodivergent skeletal pattern than on those with 'appreciable' growth remaining. Also, the results might not be stable as the tooth extrusion is counteracted by posterior occlusion and muscle stretching unless suitable growth occurs [6].

Anchorage control, especially in the vertical dimension, is of paramount importance if bite opening has to be achieved by genuine intrusion of the anterior teeth. Although extraoral appliances provide sufficient anchorage, they require excessive patient cooperation [6].

The introduction of skeletal anchorage as a source of stationary anchorage to orthodontic forces has made most complex tooth movements simple [5]. In the

past decade, skeletal anchorage systems such as mini-plates, palatal implants, mini-implants and screws have revolutionized orthodontic anchorage and biomechanics by making anchorage more stable [6].

Of those, mini-implants or screws can solve some problems associated with conventional intrusion devices, besides having other advantages. Their simple design makes them comfortable to the patient; side effects, such as extrusion of adjacent teeth, are minimized, so that results are more reliable; and the implantation technique is relatively simple, as is controlling the direction and amount of force. Additionally, the small size of the implants ensures that they can be inserted in most of the anatomic locations of the oral cavity, including the alveolar bone between dental roots. However extreme caution needs to be exercised while placing the implants at these sites so as

to avoid inflicting injury on delicate anatomic structures such as vessels, nerves or dental roots [6].

DISCUSSION

Maxillary incisor overeruption can be determined by using lateral cephalometric radiographs. The position of the maxillary incisors, especially with the upper lip, is a key factor in determining the type of treatment, since overbite correction with maxillary incisor intrusion in patients with insufficient incisor display leads to flattening of the smile arc and reduces smile attractiveness. However, deepbite patients with at least a 4-mm closure of the maxillary incisors with the lower lip and a gummy smile need to be treated with intrusion of the maxillary incisors [5].

Conventional methods of incisor intrusion usually involve 2 × 4 appliances such as utility arches, 3-piece intrusion arches, or reverse curved arches. Labial tipping of the anterior teeth is commonly the outcome of these arches and gives the impression of deep bite correction from the change in the vertical incisal edge positions[1].The counteracting moments in the molars are frequently inevitable. Reinforcement of posterior teeth by using rigid stainless steel arches was recommended to minimize the movement of the posterior anchorage unit by Burstone .However, anterior protrusion during intrusion still can hardly be avoided[5].

The application of intrusion forces directly from miniscrews offers an efficient alternative to 2 × 4 arches, and it has been shown that intrusion with minimal protrusion can be achieved [5].

Incisal edge and root apex are not good reference points because they are not independent of tooth inclination changes. The incisor centroid, defined as a point on the longitudinal axis of the tooth that is independent of any change in inclination, is the reference point of choice. Different approaches to localize the centroid have been reported that make some theoretical assumptions [7].

A reference plane relative to the centroid must also be used to evaluate whether true intrusion has been achieved; for the maxillary incisors, the palatal plane and, for the mandibular incisors, the mandibular plane are used as craniofacial reference structures [7].

Several factors like mini implant location, force magnitude and force direction determine the success of true intrusion. The selection of the point of application of the intrusive force with respect to the center of resistance (Cres) of the anterior segment is also an important consideration in the placement of the implants so that the nature of tooth movement that would occur could be predicted more accurately[6].

True intrusion without axial inclination change can only be obtained by directing the intrusive force through the Cres of the anterior teeth [5]. In vitro studies using different methods such as the laser reflection technique and holographic interferometry, photo elastic stress analysis, and the finite element method as well as in-vivo studies have been performed to determine the CR of the incisors. The results show that the CR of the four incisor teeth lies 8 – 10 mm apical and 5 – 7 mm distal to the lateral incisors [1,5].

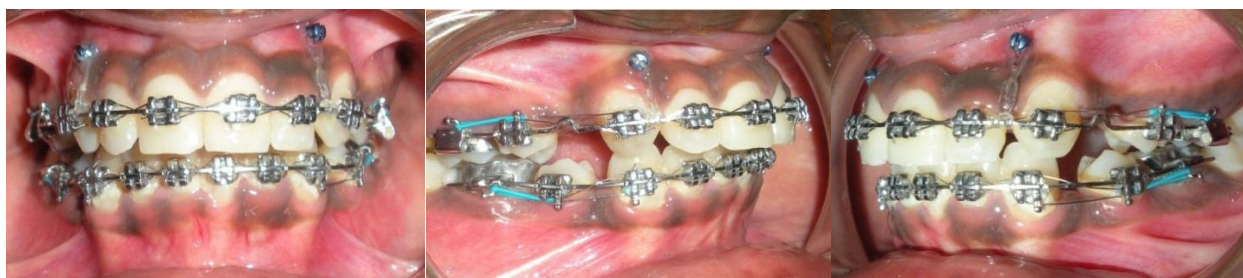

Fig-1: Mini implants placed between lateral incisors and canine for intrusion

Omur Polat-Ozsoy *et al.*[1] reported true incisor intrusion can be achieved using an intrusive force of 80 g by closed coiled springs applied from miniscrews between lateral and canine incisors where the mean upper incisor intrusion obtained was 1.92 mm and not statistically significant upper incisor angulation change.

Neslihan Ebru Senisik *et al* [4] aimed at comparing the effects of 2 maxillary intrusion systems involving Connecticut intrusion arches and mini-implants. The only applied force was the maxillary intrusion force to evaluate the genuine treatment

efficiency of the 2 intrusion systems. The mean amounts of genuine intrusion were 2.20mm in the Connecticut intrusion arch group and 2.47 mm in the implant group. During intrusion both systems led to protrusion of maxillary incisors (5 degree in the Connecticut intrusion arch group, 8 degree in the implant group), but protrusion of the incisors was preferred because of their initial retruded position. In the Connecticut intrusion arch group, the maxillary molars were extruded by moving the crown distally and the root medially which led to the loss of sagittal and vertical anchorages during intrusion of the incisors

whereas these anchorages were maintained in the implant group.

With the help of miniscrew anchorage, it is now possible to distalize molars and intrude and retract the incisors simultaneously.

A study by Deguchi *et al* [8] Analyzed the force vector where implants were used for maxillary incisor intrusion and reported that in addition, a horizontal component of force was evident which could be beneficial in retracting the incisors and distalizing the maxillary dentition. Simultaneous distalization and intrusion have also been documented in a case report by Park *et al* [9].

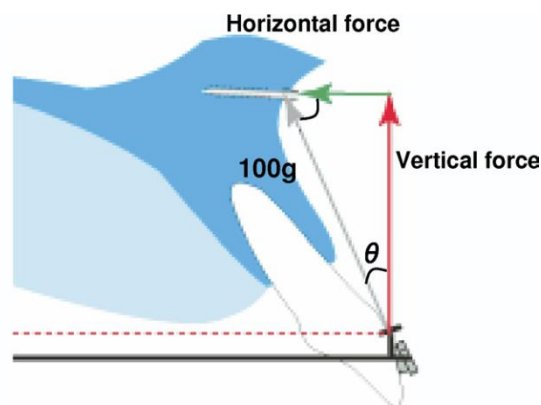


Fig-2: Intrusion force divided into vertical and horizontal directions. The horizontal line was determined as a parallel line to the arch wire; the vertical line was determined as a line perpendicular to the arch wire

Mini implants when placed distal to the canine can be used for simultaneous intrusion of the six anterior teeth. The vertical vector of force from the mini implant to the hook on the arch wire will be effective in en masse intrusion of the six anterior teeth, and the horizontal component of force can distalize the dentition to correct the molar relation.

Previous study by Isil Aras, Ali V. Tuncer[10] compared the treatment efficiency of two different mini implant assisted modalities-anterior mini implant and posterior mini implant in intruding the maxillary incisors. The study concluded that the four maxillary incisors were effectively intruded on sectional archwires with forces of 40 g per side from anteriorly or posteriorly located mini-implants. The rate of intrusion was higher using the anteriorly placed mini-implants supported incisor intrusion method compared with intrusion rate resulting from the posteriorly placed mini-implants. Because of larger vertical component of intrusive force in anterior mini implant group. Intrusion anchored from posterior mini implants yielded more labial flaring because of horizontal component of intrusive force which was greater in this group.

TAD's placed in the buccal segment have been used to simultaneously retract and intrude the incisors but the intrusion component has not yet been adequately reported. In patients with over erupted incisors and reduced facial height where intrusion and retraction is contemplated, in addition to miniscrew in the interradicular area between the second premolar and first molar, an additional miniscrew can be placed in the upper anterior region. The placement of a miniscrew between the roots of the maxillary central incisors will

produce a vector of force that counteracts the occlusal plane rotation and preserve anterior torque [11].

The location of the miniscrew will determine the vectors of force and its effectiveness. It is suggested that intrusive force should be constant, and low load deflection mechanisms should be used during incisor intrusion[4]. Regarding the optimum force for intrusion, Burstone suggested 20 g of force for intruding anterior tooth and Gianelly and Goldman recommended 15– 100 g of force for small teeth [6].

Creekmore and Eklund were the first to report intrusion of incisors using metal implant where they placed a surgical vitallium bone screw just below the anterior nasal spine and used elastic thread to elevate the maxillary central incisors approximately 6mm and tip them labially 25°, without infection, pain, or other complications from the screw [12].

Ohnishi *et al* presented a deep overbite case treated with a mini-implant by intruding the maxillary incisors; this also improved the gummy smile [12]. Shroff *et al.* and Zachrisson emphasized that In-sion-Stomion(In -Sto) distance should be respected when the intrusion of upper incisor is adopted as treatment for deep overbite. They recommended avoiding the reduction of (In-Sto) less than 3mm, for the sake of the esthetic lip and incisor relationship, particularly in young adults [13].

Kim *et al.* showed segmental intrusion of 4mm of only the maxillary incisors in a class 2 division 2 subject using skeletal anchorage by placing a mini-

implant between the central incisors below the ANS [6,12].

Chun YS *et al.* stated that bone densities in the maxillary central / central incisors interradicular site, where mini-implants are commonly placed for the purpose of intrusion, significantly decreased from the alveolar crest toward the basal bone. It has been reported that intrusive forces result in the highest failure rates. Thus, special consideration may be required when placing a mini-implant up to 6 mm apical to the alveolar crest or in the central / lateral incisors interradicular site if loosening occurs during the intrusion process. Additionally, the maxillary 2nd premolar / 1st molar interradicular site showed the lowest bone densities at the alveolar crest. Placing a miniimplant more than 2 mm level apical to the alveolar crest in this site is recommended to avoid possible loosening[15].

However, long term stability of tooth intrusion with mini implants has not been thoroughly investigated. A 30% relapse rate for upper incisor has been reported 14 months after treatment[16]. The available evidence suggest that the relapse rate may be anywhere between 20 to 60 % [17].

CONCLUSION

True intrusion can be achieved by application of intrusive forces close to the centre of resistance using miniscrews. When the upper anterior teeth are retracted and intruded at the same time, accurate mount, and precise point of application of intrusive and retrieve orthodontic forces are crucial factors for true intrusion and bodily translation of upper anterior teeth, without proclination. However, studies with a larger number of subjects and long-term follow-up are necessary and to provide additional insights on this subject.

REFERENCES

1. Polat-Ozsoy O, Arman-Ozçirpici A, Veziroglu F. Miniscrews for upper incisor intrusion. The European Journal of Orthodontics. 2009 Mar 16;31(4):412-6.
2. Ghafari J, Street KW. Dental development in children with Class II, Division 2 malocclusion—four types of the malocclusion defined. In: Biological Mechanisms of Tooth Eruption, Resorption, and Replacement by Implants 1998 (pp. 589-596). The Harvard Society for the Advancement of Orthodontics, Boston.
3. Parker CD, Nanda RS, Currier GF. Skeletal and dental changes associated with the treatment of deep bite malocclusion. American Journal of Orthodontics and Dentofacial Orthopedics. 1995 Apr 1;107(4):382-93.
4. Şenışık NE, Türkkahraman H. Treatment effects of intrusion arches and mini-implant systems in deepbite patients. American Journal of Orthodontics and Dentofacial Orthopedics. 2012 Jun 1;141(6):723-33.
5. Polat-Özsoy Ö, Arman-Özçirpici A, Veziroğlu F, Çetinşahin A. Comparison of the intrusive effects of miniscrews and utility arches. American Journal of Orthodontics and Dentofacial Orthopedics. 2011 Apr 1;139(4):526-32.
6. Upadhyay M, Nagaraj K, Yadav S, Saxena R. Mini-implants for en masse intrusion of maxillary anterior teeth in a severe Class II division 2 malocclusion. Journal of orthodontics. 2008 Jun 1;35(2):79-89.
7. Ng J, Major PW, Heo G, Flores-Mir C. True incisor intrusion attained during orthodontic treatment: a systematic review and meta-analysis. American journal of orthodontics and dentofacial orthopedics. 2005 Aug 1;128(2):212-9.
8. Pongracz C. Comparison of the intrusion effects on the maxillary incisors between implant anchorage and J-hook headgear, T. Deguchi, T. Murakami, S. Kuroda, T. Yabuuchi, H. Kamioka, T. Takano-Yamamoto, in: Am J Orthod Dentofacial Orthop, 133.(2008), 654.
9. Park HS, Bae SM, Kyung HM, Sung JH. Simultaneous incisor retraction and distal molar movement with microimplant anchorage. World journal of orthodontics. 2004 Jun 1;5(2).
10. Aras I, Tuncer AV. Comparison of anterior and posterior mini-implant-assisted maxillary incisor intrusion: Root resorption and treatment efficiency. The Angle Orthodontist. 2016 Jan 7;86(5):746-52.
11. Jung MH, Kim TW. Biomechanical considerations in treatment with miniscrew anchorage. Part 3: clinical cases. J Clin Orthod. 2008; 42(6):329-37.
12. Kim TW, Kim H, Lee SJ. Correction of deep overbite and gummy smile by using a mini-implant with a segmented wire in a growing Class II Division 2 patient. American journal of orthodontics and dentofacial orthopedics. 2006 Nov 1;130(5):676-85.
13. Shroff B, Yoon WM, Lindauer SJ, Burstone CJ. Simultaneous intrusion and retraction using a three-piece base arch. The Angle Orthodontist. 1997 Dec;67(6):455-61.
14. Nanda R. Biomechanics and esthetic strategies in clinical orthodontics. Elsevier Health Sciences; 2005 Apr 12.
15. Chun YS, Lim WH. Bone density at interradicular sites: implications for orthodontic mini-implant placement. Orthodontics & craniofacial research. 2009 Feb 1;12(1):25-32.
16. Kaku M, Kojima S, Sumi H, Koseki H, Abedini S, Motokawa M, Fujita T, Ohtani J, Kawata T, Tanne K. Gummy smile and facial profile correction using miniscrew anchorage. The Angle Orthodontist. 2011 Jun 17;82(1):170-7.
17. Hsu SP, Liou EJ. Stability evaluation of en masse maxillary retraction and intrusion by using miniscrew: one year follow up. Proceedings of the Taiwan Association of Orthodontics. 2005:17-8.

18. Lindauer SJ, Lewis SM, Shroff B. Overbite correction and smile aesthetics. *Semin Orthod* 2005;11:62-6.
19. Eberhart BB, Kuftinec MM, Baker IM. The relationship between bite depth and incisor angular change. *Angle Orthod* 1990;60:55-8
20. Uribe F, Nanda R. Treatment of Class II Division 2 malocclusion in adults: biomechanical considerations. *J Clin Orthod* 2003;37: 599-606.
21. Burstone CJ. The biomechanics of tooth movement. In: Kraus BS, editor. *Vistas in orthodontics*. Philadelphia: Lea & Febiger; 1962.p. 197-213.
22. Sarver DM, Ackerman MB. Dynamic smile visualization and quantification and its impact on orthodontic diagnosis and treatment planning. In: Romano R, editor. *The art of the smile*. Surrey, United Kingdom: Quintessence; 2005. p. 101-39.
23. Kanomi R. Mini-implant for orthodontic anchorage. *J Clin Orthod* 1997; 31: 763–67.
24. Ohnishi H, Yagi T, Yasuda Y, Takada K. A mini-implant for orthodontic anchorage in a deep overbite case. *Angle Orthod* 2005; 75: 444–52.
25. Burstone CR. Deep overbite correction by intrusion. *Am J Orthod* 1977; 72: 1–22.
26. Carrillo R, Buschang PH, Opperman LA, Franco PF, Rossouw PE. Segmental intrusion with mini-screw implant anchorage: a radiographic evaluation. *American Journal of Orthodontics and Dentofacial Orthopedics*. 2007 Nov 1;132(5):576-e1.
27. Upadhyay M, Yadav S, Patil S. Mini-implant anchorage for en-masse retraction of maxillary anterior teeth: a clinical cephalometric study. *Am J Orthod Dentofacial Orthop* 2008;134: 803-10.
28. Van Steenberg E, Burstone CJ, Pahl-Andersen B, Aartman IH. Influence of buccal segment size on prevention of side effects from incisor intrusion. *American journal of orthodontics and dentofacial orthopedics*. 2006 May 1;129(5):658-65.
29. Goel P, Tandon R, Agrawal KK. A comparative study of different intrusion methods and their effect on maxillary incisors. *Journal of oral biology and craniofacial research*. 2014 Sep 1;4(3):186-91.
30. Van Steenberg E, Burstone CJ, Pahl-Andersen B, Aartman IH. The influence of force magnitude on intrusion of the maxillary segment. *The Angle Orthodontist*. 2005 Sep;75(5):723-9.