

The Puerperal Hematoma or Genital Thrombosis: A Case Report and Literature Review

Nadia Ch'michi*, Mariyam Benayada, Nada Douraidi, Soukaina Khalta, Najia Zerai, Ibrahim Rhrab, Amina Lakhdar, Aziz Baydada, Aicha Kharbach

Gynaecology-Obstetrics and Endocrinology Department, Maternity Souissi, University Hospital Center IBN SINA, University Mohammed V, Rabat, Morocco

DOI: [10.36347/sjmcr.2020.v08i11.001](https://doi.org/10.36347/sjmcr.2020.v08i11.001)

| Received: 14.10.2020 | Accepted: 28.10.2020 | Published: 05.11.2020

*Corresponding author: Nadia CH'MICHI

Abstract

Case Report

The puerperal hematoma is a dreaded complication of postpartum hemorrhage, caused by a vascular rupture, most often a venous one. The main known risk factors are fetal macrosomia and instrumental extractions. Depending on the location of the puerperal hematoma, a variety of symptoms ranging from vulvar swollen to an abdominal pain can be seen. The diagnosis is often clinical; a CT scan can locate the vessel causing the hematoma. The management of the puerperal hematoma is multidisciplinary with a tendency toward arterial embolization in most cases. Through a clinical observation, we will try to focus on this pathology and especially discuss the different therapeutic options.

Keywords: Puerperal hematoma, transcatheter arterial embolization, postpartum hemorrhage.

Copyright © 2020 The Author(s): This is an open-access article distributed under the terms of the Creative Commons Attribution 4.0 International License (CC BY-NC 4.0) which permits unrestricted use, distribution, and reproduction in any medium for non-commercial use provided the original author and source are credited.

INTRODUCTION

The puerperal hematoma (or the genital thrombosis) is a rare dreaded hemorrhagic complication of the postpartum which the maternal prognosis can be engaged. A puerperal hematoma is a special form of postpartum hemorrhage.

The objective of our work is to study the modalities of management of puerperal hematoma in a case in the gynecological and obstetrical department the Souissi maternity hospital Rabat.

CASE REPORT

Mrs. K.F, 25 years old, with was no significant past, obstetric, or surgical history, primitive, gives birth to a newborn male, weighing 3700g by vaginal delivery. An instrumental extraction by Forceps and an episiotomy were necessary for extraction and a lateral vaginal tear occurred during delivery. Two hours after childbirth, the patient claims very intense, unbearable pain in the perineal region with an urge to push.

On examination, we find a patient with a stable hemodynamic state, a good safety globe, with an externalization several blood clots, the blood loss was estimated to be 600 g and a very painful swelling in the vulva of 6 cm, the diagnosis of genital thrombosis was made.

The patient was urgently transferred to the operating room with monitoring, 102bpm, a blood pressure of 110/60 mmHg and the blood count showed an Hb level of 10.7g/dl. Under general anesthesia a wide incision was made with evacuation of the hematoma by cleaning-draining, hemostasis was ensured by the realization of an X stitches, a corrugated blade of delbet was left in place for 24 h to ensure the draining.

The patient left the hospital five days after the operation, and a complete disappearance of the hematoma after 5 weeks. She was followed up after 2 month and she did not have any complaints. The patient's consent and the institutional ethical board's permission were taken for the publication of this case report.

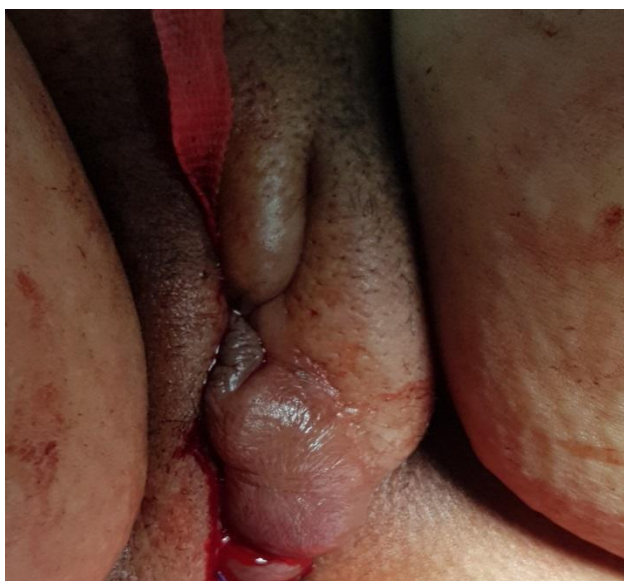

Fig-1: Vulvar puerperal hematoma

DISCUSSION

The incidence of genital hematomas is of the order of 4/5132 or 1/1283 deliveries [1]. Due to a vascular rupture a blood collection is formed within the cellular tissues of the vulva, the vagina, or the parameter and tending to diffuse towards the pelvis or towards the perineum. The vascular rupture is most often venous. Formed in the thickness of the vaginal walls after the rolling of the tissues undoubtedly related to the rotation of the fetal head and the instrumental extractions. A forced cleavage is formed and very often the rupture of the visceral fascia. The hematoma continues its spreading along the various fasciae and progressively dissects the vaginal wall. It can also extend below the levator ani muscle, distend the perineum and push back the rectum, the anus, and extend above, upward into the broad ligament base and retroperitoneum [2-4]

Vascular wounds within tissue detachment have no tendency to hemostasis and the hemorrhage will be complicated by DIC very quickly [5].

There are four main types of genital hematoma according to an anatomical classification: [6]

- Vulvar hematoma,
- the vaginal hematoma itself
- vulvovaginal hematoma
- pelvi-abdominal hematoma

A chronological classification describes: [5]

Immediate hematoma: occurs immediately after delivery and directly secondary to obstetric trauma. The bleeding is often of venous origin, cannot be collected as long as the fetal head is still not expelled compressing the virtual cavity. This hematoma only becomes apparent after delivery. If the bleeding is

arterial, it will collect very quickly, which may interfere with the delivery of the placenta.

Delayed hematoma: it is most often discovered a few days, even a few weeks after childbirth, probably secondary to necrosis by hyperpressure of the pelvic vessels, which can be the evolution of an immediate hematoma not previously recognized.

The main risk factors are primiparity, instrumental extractions, toxemia of pregnancy, fetal macrosomia, prolonged labor, difficult or insufficient hemostasis mainly by inadequate repair, or a vascular wound during a pudental block, multiple pregnancies and vulvar vaginal varicose veins [7, 8].

The role of episiotomy is controversial, protective for some [9] promoting for others [7]. Vulvar vaginal hematomas often develop on the ipsilateral side of the episiotomy site. However, hematomas can also be formed on the contralateral side of the episiotomy [10]

In the 2006 CNGOF recommendations on the practice of episiotomy, the restrictive practice of episiotomies does not modify the rate of perineal hematomas [5].

In our patient, the risk factors are represented by primiparity and instrumental extraction. The symptoms vary depending on the location of the hematoma, its size and whether it is extensive or not, immediate or delayed, an externalized hemorrhage or not. The pain is the master symptom; it is often very intense, throbbing and unbearable. It is usually associated with a tenesmus, a urge to push, its unusual exacerbated character, with agitation contrasting with the usual lull of postpartum and must quickly alert to perform an immediate examination [1]. These symptoms are accompanied by more or less marked signs of internal bleeding up to hypovolemic shock [5].

The inspection shows a very painful swelling in case of vulvar hematoma, and the large lip is rapidly oedemated, tense, hyperalergic to the touch and purplish. In case of vaginal hematoma, the diagnosis is less easy, the external examination is normal appearance, it is the internal vaginal examination that will authenticate the swelling and its volume. Examination reveals swelling of the side wall of the vagina [11]. Concerning the hematoma under peritoneal, the clinical picture is that of an unexplained internal bleeding, it is often underestimated [11]. We find a defense, a deviated uterus, a voussure above the crural arcade.

Depending on the location, the differential diagnosis is made with a vulvar or vaginal cyst, Bartholinitis, uterine inversion, uterine prolapse, uterine rupture, uterine atony, hernial tumors, vulvar varices complicated during childbirth (thrombosis superficial, rupture) [2, 4].

The management must be rapid taking into account the prognosis, the intensity of the pain, and the blood loss with the risk of consumption coagulopathy.

Once the postpartum hematoma is diagnosed, it is necessary to stabilize the hemodynamic state of the patient, the search for secondary anemia due to the hemorrhage, and choose an adequate treatment as soon as possible. At the start, the therapeutic management of puerperal hematoma was carried out according to its size:

If the hematoma is less than 3-5 cm, an expectation can be performed with local application of ice, prescription of analgesics, and careful monitoring. If the hematoma has remained stable for several hours and without maternal repercussions, nothing else will be offered [5].

In the event of a medium-sized hematoma 5 to 10cm in diameter, the incision-cleaning-draining appears to be the best compromise; embolization may come to the aid of a resumption of bleeding [8].

When the hematoma is large, in particular more than 10 cm long, rapidly extensive or recurrent, elective embolization appears to be the most appropriate technique. In the event of failure of

embolization, conventional surgery must be performed, especially the ligation of the hypogastric arteries [8].

Currently other strategies have been proposed depending on the authors

Takaji *et al.* proposed to perform, if the patient is hemodynamically stable, as a first-line CT scan to identify the type of hematoma and determine the origin of the bleeding, if an actively bleeding vessel is confirmed, emergency arterial embolization should be selected as the first-line treatment to obtain hemostasis. After hemostasis has been obtained, the hematoma should be opened and drained [10].

Tsumagari *et al.* created an algorithm for the management of postpartum hematoma by taking into account the anatomical location of the hematoma and proposing several treatment options. They therefore insisted on the fact that the location of the puerperal hematoma must constitute the basis for the choice of treatment. Specifically, TAE (Transcatheter Arterial Embolization) (TAE) should be the first treatment offered for hematoma of the upper vaginal wall. Hematomas of the lower vaginal wall can be treated using surgery, but when it is difficult to achieve hemostasis, TAE should be considered. For hematomas of the lower vaginal wall or vulva, abstention from therapy may be considered if the patient's hemodynamic state is stable [12].

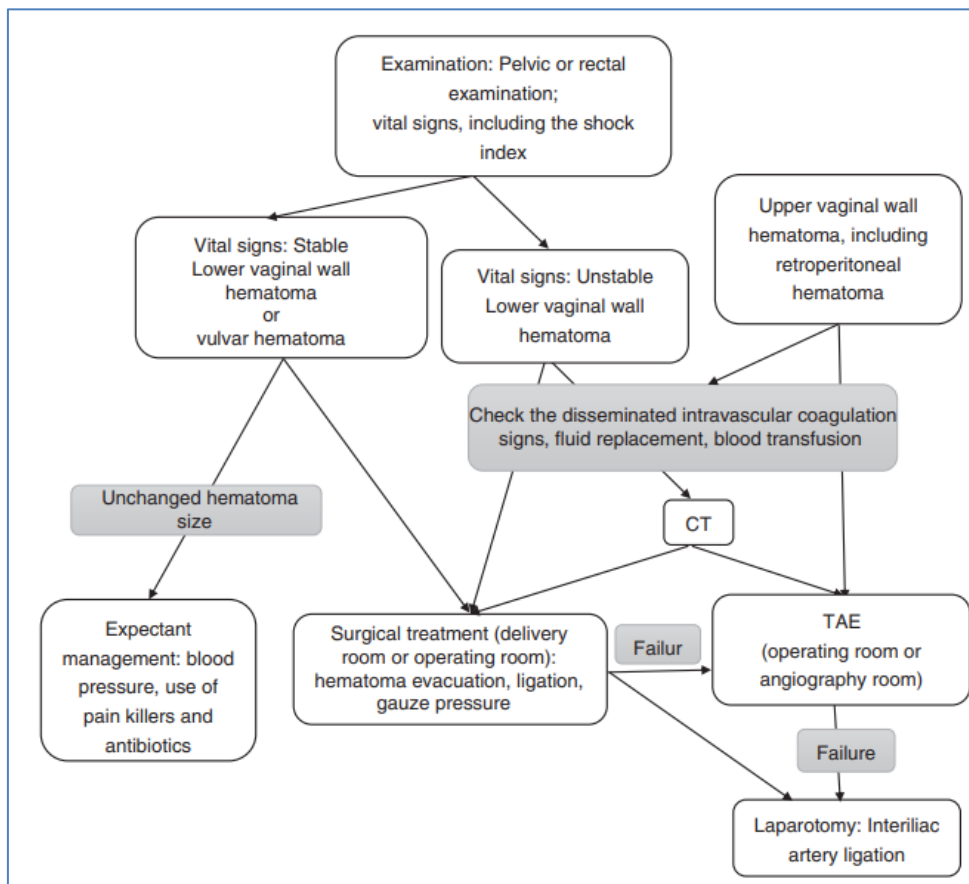


Fig-2: Algorithm for post-partum hematoma treatment of Tsumagari *et al.* [12]

CONCLUSION

The puerperal hematoma is a serious complication of the immediate post-partum that should not be ignored, the management must be fast and adapted according to the location of the hematoma and the hemodynamic state of the patient, the use of Transcatheter arterial embolization should be the first treatment offered for hematoma of the upper vaginal wall.

DECLARATIONS

Guarantor of Submission

The corresponding author is the guarantor of submission.

Availability of data and materials

Supporting material is available if further analysis is needed.

Competing interests

The authors declare that they have no competing interests.

REFERENCES

- Zeghal D, Kehila M, Mahjoub S, Ben Brahim F, Rajhi H, Zouar F. L'hématome Périgénital: Diagnostic et prise en charge. *La Tunisie Médicale*. 2010;88(02):99-101.
- Barot S, Tardif D. Déchirures obstétricales anciennes. *EMC (Elsevier Masson, Paris). Gynécologie*. 2010: 200-A-10
- Genre L, Tanchoux F, Parant O. Hématome puerpéral pelvien: étude sur cinq années de suivi. *Journal de gynécologie obstétrique et biologie de la reproduction*. 2012 May 1;41(3):290-7.
- Bienstman-Pailleux J, Huissoud C, Dubernard G, Rudigoz RC. Prise en charge des hématomes puerpéraux. *Journal de gynécologie obstétrique et biologie de la reproduction*. 2009 May 1;38(3):203-8.
- Université virtuelle médicale de francophonie UVMF; *Complication traumatique de l'accouchement*; 2014
- Benali S, Kouach J. A rare cause of postpartum hemorrhage: the genital thrombus. *The Pan African Medical Journal*. 2019 Jul 19;33:241-.
- Riethmuller D, Pequegnot-Jeannin C, Rabenja CA, Koeberle P, Schaal JP. Une cause rare d'hémorragie du post-partum: le thrombus génital. *Journal de gynécologie obstétrique et biologie de la reproduction*. 1997;26(2):154-8.
- Jacquetin B, Boulleret C, Fatton B. Thrombus génitaux. In: *CNGOF. Mises à jour en gynécologie obstétrique tome XXII*; 1998:347.
- Subtil D, Sommé A, Ardiet E, Depret-Mosser S. Hémorragies du post-partum: fréquence, conséquences en termes de santé et facteurs de risque avant l'accouchement. *Journal de gynécologie obstétrique et biologie de la reproduction*. 2004 Dec 1;33(8):9-16.
- Takagi K, Akashi K, Horiuchi I, Nakamura E, Samejima K, Ushijima J, Okochi T, Hamamoto K, Tanno K. Managing vulvovaginal hematoma by arterial embolization as first-line hemostatic therapy. *Taiwanese Journal of Obstetrics and Gynecology*. 2017 Apr 1;56(2):224-6.
- Barot S, Tardif D. Déchirures obstétricales anciennes. *EMC (Elsevier Masson, Paris). Gynécologie*; 2010, 200-A-10
- Tsumagari A, Ohara R, Mayumi M, Yagi H, Nagai Y, Obata- Yasuoka M, Hamada H, Satoh T. Clinical characteristics, treatment indications and treatment algorithm for post- partum hematomas. *Journal of Obstetrics and Gynaecology Research*. 2019 Jun;45(6):1127-33.