

Case Report

Extrasosseous Ewing's sarcoma of the leg: A case report

**Moncef Boufettal*, Mohamed.Azouz, Amine.H.Rouhi, Mustapha.Mahfoud, Ahmed.El Bardouni,
Mohamed.S.Berrada, Moradh.El Yaacoubi**

Orthopedic surgery department of Ibn Sina hospital, University Mohamed V, Rabat, Morocco

***Corresponding author**

Dr Boufettal Moncef

Email: moncef.bof@gmail.com

Abstract: Ewing's sarcoma (ES) is the second most common malignant bone tumor in children and young adults. Most cases are reported in the bone, and extrasosseous Ewing's sarcoma (ESS) is an extremely rare disease. We present a case of 36 year old female with extrasosseous Ewing's sarcoma developing at the soft tissue in the leg. Their diagnosis was radiological and essentially histological. The Treatment is multidisciplinary consisting in a collaborative approach between (orthopedist, oncologist, radiotherapist and histopathologist), and it requires a radical excision as soon as possible. In the literature, there have been only a few case reports of ESS located in the leg. We conclude that, although this is an unusual location, EES should be contemplated in the differential diagnosis of soft tissue tumors in the limbs.

Keywords: Ewing's sarcoma; extrasosseous;

INTRODUCTION

Ewing's sarcoma is a rare malignant tumor and represents a family of morphologically similar small round-cell neoplasms [1]. These tumors generally originate in bone tissue, but they can occasionally originate in soft tissue, known as extraskeletal Ewing's sarcoma (EES). It mainly affects very young people. Adult patients are very rare and constitute only 5% of all cases [1, 2]. Only approximately 16% of all Ewing's sarcomas are extrasosseous [1, 3]. This report describes in detail a case of EES of the leg with extensive involvement of soft tissues without erosion of the bone.

CASE REPORT

A 36-year-old female presented with a painless palpable mass on the proximal third of her right leg. Her family history was non contributory. She initially noticed a small swelling which eventually increased in size. Physical examination revealed a 90 × 60 mm, painful and firm mass in the third upper of the right leg which had gradually worsened. The skin over the mass was unremarkable. The patient had no history of radiation or trauma. Motor and sensory examinations were normal and there was no lymphadenopathy in the inguinal areas. No other acute symptoms were reported by the patient. Hematological and biochemical investigations were normal, including white cell count, Erythrocyte sedimentation rate and C-reactive protein. Plain radiography was objectified an opacity in the third upper of the right leg. Magnetic resonance imaging (MRI) showed a subcutaneous soft tissue mass measuring 110×65 mm (fig 1, 2). There was no

calcification or ossification objectified. Adjacent bone and periosteum were normal. Biopsy of the lesion was done and confirmed the diagnosis of Ewing's sarcoma. A large resection of the tumour was performed (fig 3, 4) after the biopsy result. Following surgery, the patient underwent adjuvant chemotherapy which includes 6 cycles of VIDT (vincristine, ifosfamide, doxorubicin and etoposide) and radiotherapy sessions. She experienced no recurrence or distant metastasis for 2 years after the surgery.

DISCUSSION

Ewing sarcoma (ES) is a malignant tumour of bone which is composed of small round tumour cells. It accounts for 6-8% of all primary malignant bone tumours and predominantly affects children, adolescents and young adults [4]. It is seldom seen in soft tissue and known as extraskeletal Ewing's sarcoma (EES) [5]. The EES develops preferentially on the trunk and axial soft tissues in 50-60% of cases and secondarily in the limbs in 20-25% of cases [6]. Pain and swelling are the leading symptoms that help discover the disease; associated with general symptoms (fever, asthenia and weight loss). MRI also gives useful information regarding tumor extent, anatomical location, tumor size, and for appropriate planning of surgical therapy and preoperative diagnosis. It mainly allows an accurate assessment of the chemotherapy response [6]. Biopsy is essential for definitive diagnosis. The most commonly used is open biopsy technique [7]. Microscopically, the tumor had a small, round, and blue cells with abundant glycogen and an

absence of cytoplasmic filaments [1]. It is rather easy to confuse ESS with embryonic neuroblastoma, lymphoma or rhabdomyosarcoma. This is due to the fact that EES shares the histopathologic and immunohistochemistry findings with Ewing's sarcoma. Confirmation of the diagnosis should be based on positive staining for CD99 during immunohistochemistry [8].

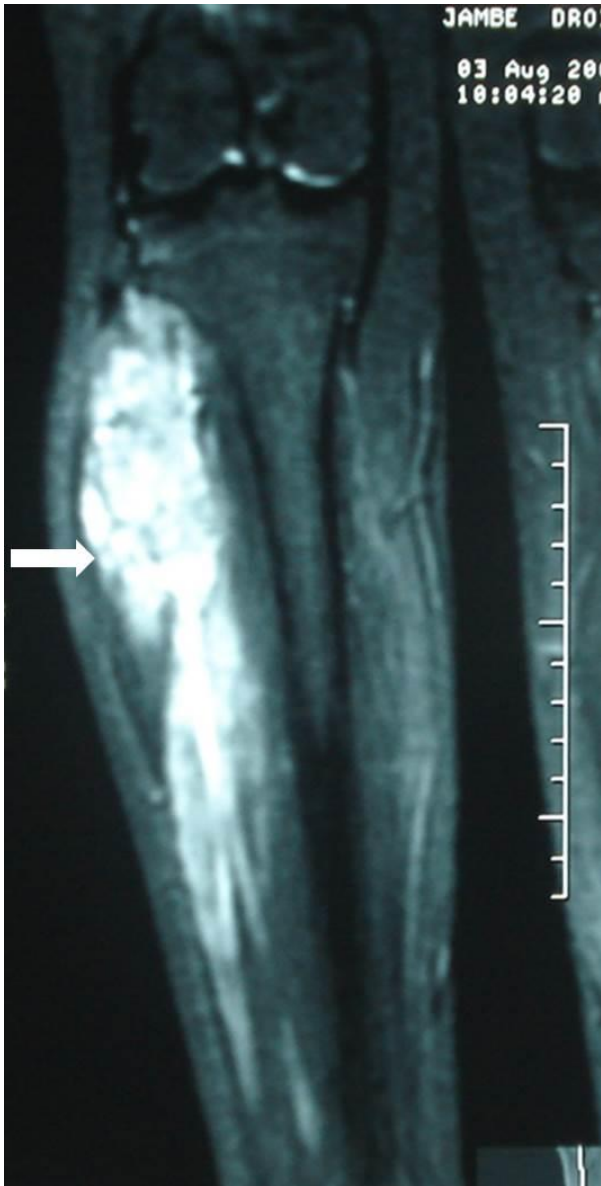


Fig-1: T2-weighted frontal MRI image showing a heterogeneous and hyper intense tumoral process occupying the upper third of the right leg.

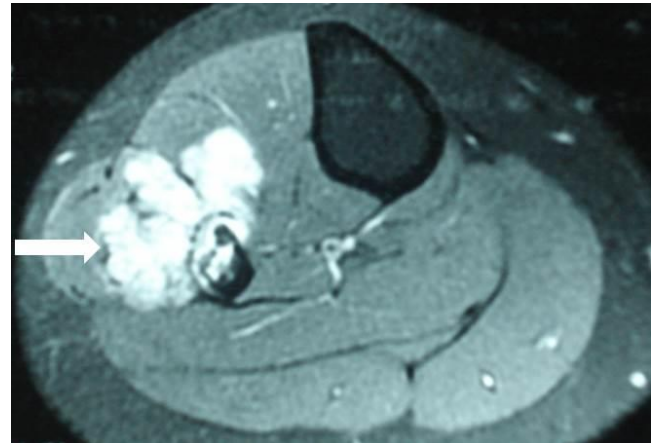


Fig-2: T2-weighted axial MRI image showing extraskeletal tumour at the anterior and lateral part of the right leg.

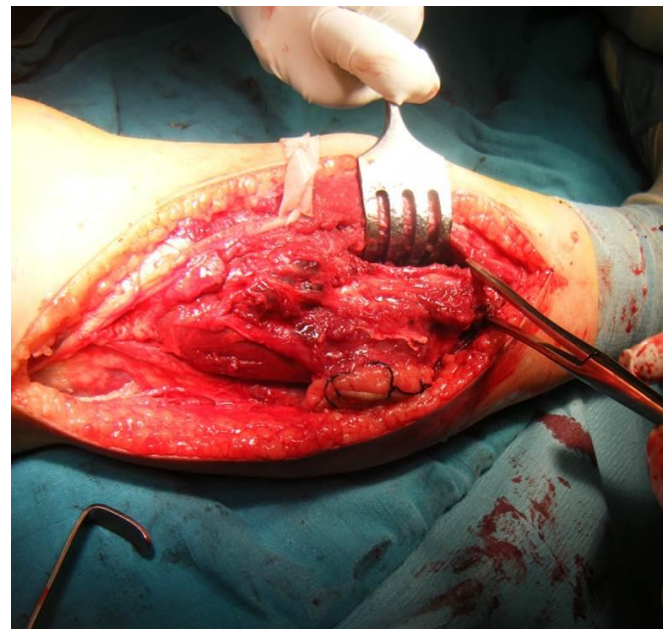


Fig-3: Intraoperative aspect of extraskeletal Ewing's sarcoma of the right leg.

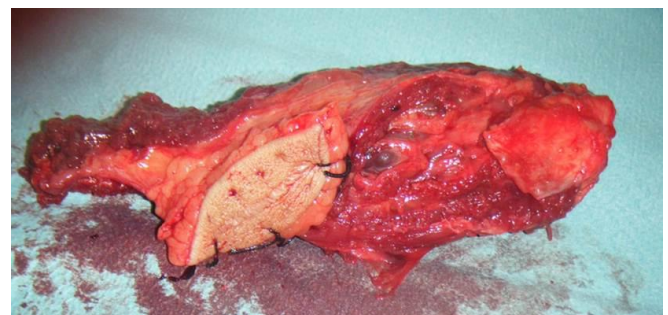


Fig-4: Operative specimen of the tumor.

Clinically and radiologically, it is difficult to distinguish this disease from other soft tissue malignancy, so diagnosis of EES is based on histopathology [8]. Extraskeletal Ewing's sarcoma is a curable disease. The disease-free survival rate has been significantly increased by managing these tumors with

aggressive surgical resection in combination with multi-agent chemotherapy, with or without radiotherapy [1]. For localized SE, the treatment of choice is chemotherapy: 3-6 cycles followed by local treatment then a 6 to 10 cycles through 6 week intervals; the most active drugs are: Doxorubicin, Cyclophosphamide, Ifosfamide, Vincristine, Dactinomycin and Etoposide; most protocols are based on the combination of 4 to 6 of these drugs [6].

Generally, the SE is a very aggressive tumor with a high risk of metastasis (40% are localised in the lungs, 30% in bone) and frequent recurrences (30%) [9]. Rhythm of surveillance is every 2-3 months during the first three years; once every 6 months to 5 years and at least once a year beyond 5 years [6]. In a retrospective study of 24 patients with EES, a global 5-year survival rate of 61% was seen. Another study estimated a 5-year disease-free survival rate of 60%-70% for localized disease when treated with chemotherapy based on multiple antineoplastic drugs and surgical exeresis [3, 8].

CONCLUSION

Most cases of Ewing's sarcoma are reported in the bone, and extraosseous Ewing's sarcoma is an extremely rare disease. Despite its rarity, it is always necessary to consider EES in the differential diagnosis of soft tissue sarcomas for early diagnosis and therapeutic management, because his identification in localized stage is often associated with a good prognosis.

Competing interests

The authors declare no competing interest.

Authors' contributions

All authors participated in the literature search, interpretation of the articles reviewed and analysis of the data and review of the manuscript. All the authors have read and approved the final version of the manuscript.

REFERENCES

1. Hwang SK, Kim DK, Park SI, Kim YH, Kim HR; Primary Ewing's Sarcoma of the Lung. The Korean journal of thoracic and cardiovascular surgery, 2014; 47(1):47-50.
2. Shimada H, Newton WA, Soule EH, Qualman SJ, Aoyama C, Maurer HM; Pathologic features of extraosseous Ewing's sarcoma: a report from the Intergroup Rhabdomyosarcoma Study. Human pathology, 1988; 19(4):442-453.
3. Raney RB, Asmar L, Newton WA Jr, Bagwell C, Breneman JC, Crist W, et al.; Ewing's sarcoma of soft tissues in childhood: a report from the Intergroup Rhabdomyosarcoma Study, 1972 to 1991. Journal of clinical oncology, 1997; 15(2):574-582.

4. Kashima TG, Gamage NG, Dirksen U, Gibbons CL, Ostlere SJ, Athanasou NA. Localized Ewing sarcoma of the tibia. Clin Sarcoma Res, 2013; 3:2.
5. En-Nafaa I, El Ounani F, Latib R, Jroundi L, Boujjida N, Chami I ; Une localisation rare de sarcome d'Ewing au niveau médiastinal antérieur: Ewing sarcoma of the anterior mediastinum: a rare tumor localization. Journal de radiologie, 2010; 91(12):1287-1288.
6. Ayadi L, Chaari C, Kallel R, Ayadi K, Khabir A, Jlidi R, et al. Sarcome d'Ewing Osseux et Extra Osseux: Etude anatomo-clinique de 29 cases. Tunisie médicale. 2010; 88(5):301-305.
7. Geens L, Van Robays J, Geert V, Van der Speeten K. An Unusual Location of Extraosseous Ewing's Sarcoma. Case reports in oncology, 2013; 6(2):293-302.
8. Halefoglu AM; Extraskelatal Ewing's Sarcoma Presenting as a Posterior Mediastinal Mass. Archivos de Bronconeumología (English Edition). 2013; 49(2):82-84.
9. Leavey PJ, Collier AB; Ewing sarcoma: prognostic criteria, outcomes and future treatment. Expert Review of Anticancer Therapy, 2008; 8:617-624.