

Case Report

Tubular Adenoma of Breast Mimicking as Fibroadenoma: A Rare Case Presentation

Ch. Krishna Reddy¹, K. Mahesh Kumar², V. Indira³, P. V. Patil⁴, K. Swetha⁵

^{1,2,5}Assistant Professor, Malla Reddy Institute Of Medical Sciences (MRIMS), Suraram, Hyderabad, Telangana - 500055, India

³Professor, Malla Reddy Institute Of Medical Sciences (MRIMS), Suraram, Hyderabad, Telangana - 500055, India

⁴Professor and HOD, Malla Reddy Institute Of Medical Sciences (MRIMS), Suraram, Hyderabad, Telangana - 500055, India

*Corresponding author

Ch. Krishna Reddy

Email: krishnareddy.chr@gmail.com

Abstract: Tubular adenomas are rare benign epithelial tumors of the breast, occur commonly in young women of reproductive age. Very few cases were reported in the literature. Preoperative diagnosis is often difficult as they mimic fibroadenomas both clinically and radiologically. Histopathological examination is necessary for correct diagnosis. Tubular adenoma must be differentiated from other benign and malignant lesions, which are closely related such as fibroadenoma and tubular carcinoma respectively. We reported such a rare case of tubular adenoma in young female who presented with gradually enlarging breast lump. Other systemic examination was insignificant. Clinical diagnosis was given as fibroadenoma. Surgical excision was done and on histopathological examination, diagnosis of tubular adenoma was made. They are associated with good prognosis and recurrence after surgery is rare.

Keywords: Benign, Fibroadenoma, Histopathological, Tubular adenoma

INTRODUCTION

Tubular adenomas or pure adenomas are rare benign epithelial tumors of the breast accounts for 0.13 - 1.7% of benign breast lesions [1], that are common in the young women with mean age of 10-20 years [2]. Clinically pure adenomas are indistinguishable from fibroadenomas. Preoperative diagnosis is difficult as both radiologic and cytologic examinations performed before surgery is often not diagnostic [3]. These rare tumors must to be differentiated from other benign and malignant lesions of breast of the breast.

CASE REPORT

A 18 year old female patient came with complaints of swelling in the right breast since 1year, which was gradually increasing in size. There was no history of pain or fever and it was not associated with menstrual irregularities. On examination lump measuring 3 x 2 cms was noted in the inner upper quadrant, which was non tender, firm in consistency and freely mobile. Clinical diagnosis of fibroadenoma was made. Routine investigations revealed normal study. Ultrasound of breast revealed fibroadenoma. Patient was subjected for lumpectomy and specimen was sent for histopathological examination.

Gross

We received irregular nodular grey white soft tissue mass measuring 2.5 x 2 x 1 cms. Cut section showed a well encapsulated solid homogenous grey white mass (Fig. 1).

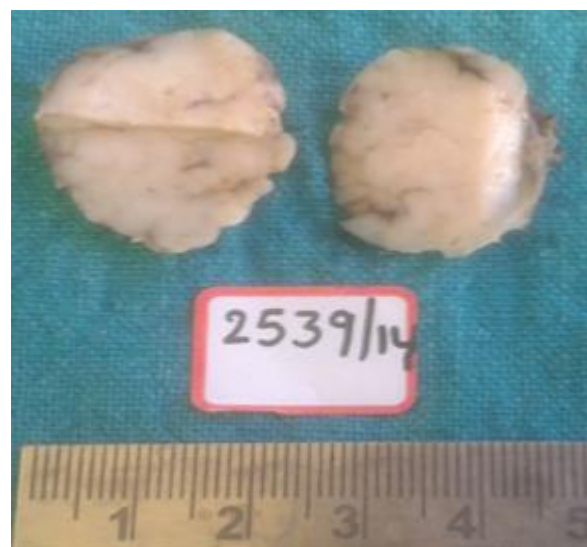

Fig. 1: Gross showing the homogenous grey white nodular mass

Microscopy

Multiple sections studied showed closely packed tubular structures lined by the inner cuboidal epithelium and outer attenuated myoepithelial layer surrounded by the scant intervening stroma (Fig. 2-4). Based on these findings diagnosis of Tubular adenoma was confirmed.

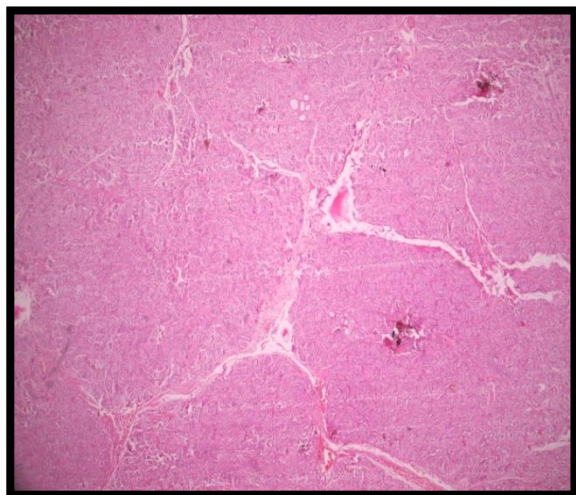


Fig. 2: H & E 4X with the tumor tissue arranged in nodular pattern

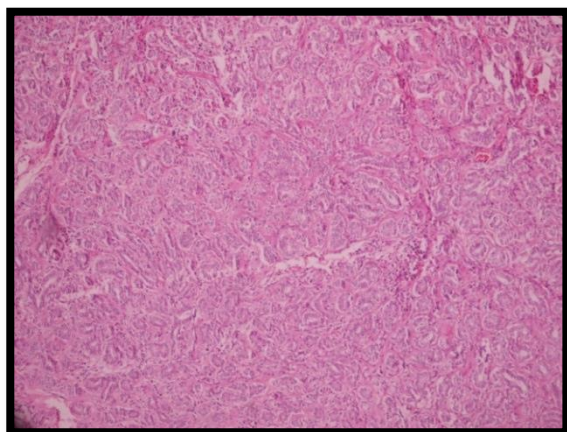


Fig. 3: H&E 10X showing the tightly packed tubules with little intervening stroma

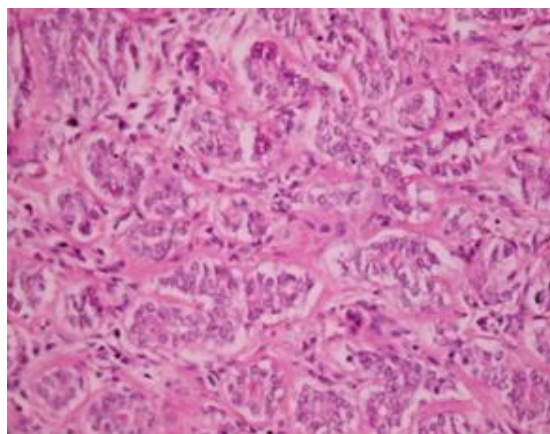


Fig. 4: H&E 40X showing double layered tubules with scant stroma.

DISCUSSION

Tubular adenoma is a rare benign epithelial tumor of the breast, first described as a distinctive entity in 1968 by Persaud *et al.* [4, 5]. They are considered variants of pericanalicular fibroadenomas with an exceptionally prominent or florid adenosis like epithelial proliferation. Tubular breast adenomas most often affect young women of reproductive age, but not associated with oral contraceptive treatment or pregnancy; rare in postmenopausal women. Clinically they may be asymptomatic, may be detected occasionally during mammography or during a physical examination as a palpable mass and are gradually increasing. Preoperative diagnosis of them is often difficult because clinical and radiological studies are non specific and are similar to fibroadenomas [5]. Histopathological examination is the definitive test for confirming the diagnosis.

In gross, tubular adenoma is well circumscribed with solid homogenous to finely nodular tan yellow cut surface and firm consistency, and tends to be softer than fibroadenoma. Histologically, it is characterized by the presence of closely packed homogenous acinar and tubular epithelial components with sparse intervening stroma [6]. These lesions are to be differentiated from other benign lesions like fibroadenoma and lactating adenomas and malignant lesion like tubular carcinoma. Fibroadenomas are composed of ducts surrounded by the abundant fibromyxoid stroma in contrast, tubular adenomas are composed of tightly packed tubules with scant stroma. Lactating adenomas are associated with pregnancy and lactation and are easily differentiated from tubular adenomas based on relevant clinical history and composed of the luminal epithelial cells of the enlarged acini have vacuolated cytoplasm and enlarged round nuclei and luminal secretion. The cells have prominent nucleoli and increase mitotic activity which are common in lactation. There is no intraluminal epithelial proliferation [7]. Tubular carcinomas are differentiated from tubular adenomas by invasion into the stroma.

The true nature of the neoplasm remains controversial. Some researchers supported a common histogenesis for Tubular adenoma, Lactating adenoma and Fibroadenoma reporting that the lesion is simply an extreme variant of Fibroadenoma. An immunohistochemical study of both lesions reported that several cell components of both epithelial and mesenchymal origin were involved in the genesis of tubular adenomas [8]. Combined tubular adenoma and fibroadenoma account for 4% of all benign lesions and around 11% of breast adenomas. Surgical excision is the choice of treatment that is often necessary even for the confirmation of the diagnosis [9]. Recurrence after complete excision is rare and hence has good prognosis.

CONCLUSION

Tubular adenomas are rare benign epithelial tumors of breast, seen most commonly in the young women of reproductive age group. Preoperative diagnosis is often non specific and inconclusive and most cases are similar to fibroadenomas both clinically and radiologically. Histopathological examination is gold standard and is definitive for confirming the diagnosis. Surgical excision is the treatment of choice. Recurrence after surgery is rare hence, prognosis is excellent.

REFERENCES

1. Sengupta S, Pal S, Biswas BK, Phukan JP, Sinha A, Sinha R; Preoperative Diagnosis of Tubular Adenoma of Breast - 10 years of experience. N Am J Med Sci., 2014; 6(5): 219-223.
2. Mudholkar VG, Kawade SB, Mashal SN; Histopathological study of neoplastic lesions of breast. Indian Medical Gazette, 2012; 9: 353-364.
3. Rovera F, Ferrari A, Carcano G, Dionigi G, Cinquepalmi L, Boni L *et al.*; Tubular adenoma of the breast in an 84-year-old woman: report of a case simulating breast cancer. Breast J., 2006; 12(3): 257-259.
4. Persaud V, Talerman A, Jordan R; Pure adenoma of the breast. Arch Pathol., 1968; 86(5): 481-483.
5. Salemis NS, Gemenetzi G, Karagkiouzis G, Seretis C, Sapounas K, Tsantilas V *et al.*; Tubular adenoma of the breast: a rare presentation and review of the literature. J Clin Med Res., 2012; 4(1): 64-67.
6. Soo MS, Dash N, Bentley R, Lee LH, Nathan G; Tubular adenomas of the breast: imaging findings with histologic correlation. AJR Am J Roentgenol., 2000; 174(3): 757-761.
7. Hamza AA, Idris SA; Lactating adenoma of the breast a diagnostic difficulty in pregnancy and rewarding natural history during lactation: A case report and review of literature. Medicine Journal, 2014; 1(1): 13-16.
8. Fu Y, Miao LY, Ge HY, Mei F, Wang JR; Can ultrasound be used to differentiate tubular adenomas of breast from fibroadenomas or carcinoma? Asian Pac J Cancer Prev., 2014; 15(3): 1269-1274.
9. Zuhair AR, Maron AR; Tubular adenoma of the breast: A case report. Case Reports in Clinical Medicine, 2014; 3: 323-326.