

Case Report

Unilateral Absence of Pectoralis Major

Dr Ughade Jaideo Manohar¹, Dr Kardile Poorwa Baburao²

¹Associate Professor, ²Assistant Professor, Department of Anatomy, Shri Vasantrao Naik Government Medical College, Yavatmal – 445001, Maharashtra.

***Corresponding author**

Dr Ughade Jaideo Manohar

Email: drjaideoughade@gmail.com

Abstract: During our routine dissection we noted a case of complete absence of pectoralis major with compensatory hypertrophy of pectoralis minor muscle and absence of medial pectoral nerve on the right side. Partial absence of pectoral muscles is not infrequent, however complete absence of pectoral major muscle is rare. There were no other associated anomalies. Though pectoralis major plays an important role in wide range of movements of shoulder joint, there is no significant loss in function of routine activities in case of absence of pectoralis major muscle because of compensation by surrounding muscles.

Keywords: Pectoralis Major, Pectoralis Minor, Poland's syndrome, Pectoral nerve.

INTRODUCTION

The two pectoralis major muscles of either side, commonly referred to as the "pecs," are the muscles that form the bulk of the chest. The muscle is more prominent in case of males as in females it is hidden by breast [1]. It is the muscle which form the anterior axillary fold, an important surface landmark [2].

Pectoralis major is a thick, fan shaped muscle and form the regular contour of chest wall. It arises from anterior surface of the sternal end of the clavicle, from half the breadth of anterior surface of sternum upto sixth costal cartilage, second to sixth costal cartilage, from the sternal end of sixth rib and from the aponeurosis of obliquus externus abdominis. The muscle converges to form a flat tendon which is attached to the lateral lip of intertubercular sulcus of the humerus. The tendon is bilaminar with thick anterior lamina formed by fibres from manubrium which are joined superficially by clavicular fibres and deeply by fibres from sternal margin and second to fifth costal cartilages. Posterior lamina receives fibres from sixth costal cartilage, sixth rib, sternum, aponeurosis of obliquus abdominis externus. Posterior lamina gives off an expansion that blends with the capsular ligament of the shoulder joint. Pectoralis major as a whole muscle assist adduction and medial rotation of the humerus against resistance[2].

Pectoralis minor lies deep to pectoralis major. It arises from outer surface of third to fifth ribs and from the fascia adjoining external intercostal muscle. It converges in a flat tendon which is attached to medial border and upper surface of coracoid process of

scapula. It is innervated by medial and lateral pectoral nerve. Pectoralis minor assist in protraction and depression of shoulder. Medial pectoral nerve is derived from eighth cervical and first thoracic ventral rami. It normally pierces pectoralis minor and end in pectoralis major. The pectoralis major and minor both are supplied by medial and lateral pectoral nerves[2].

Knowledge of these anatomical variations in muscles and brachial plexus are essential while planning surgery in the axilla and arm. It is also useful for anaesthetologist applying various nerve blocks for surgeries over upper limb and breast[3].

CASE REPORT

Observation

A 36 years old, embalmed male cadaver had assymetrical configuration of chest wall. The well developed curved anterior axillary fold was absent on right side. On routine dissection of pectoral region we found

1. Complete absence of pectoralis major muscle on right side (figure 1)
2. pectoralis minor origin extended from 2nd rib to sixth rib on the right side and is more bulky than of left side. (figure 2)
3. Medial pectoral nerve is absent and pectoralis minor is supplied by lateral pectoral nerve on right side. (figure 3)

No specific procedure was performed on him. No incision or scar mark was seen on anterior chest wall. There was no other associated anomaly. Other side was normal.

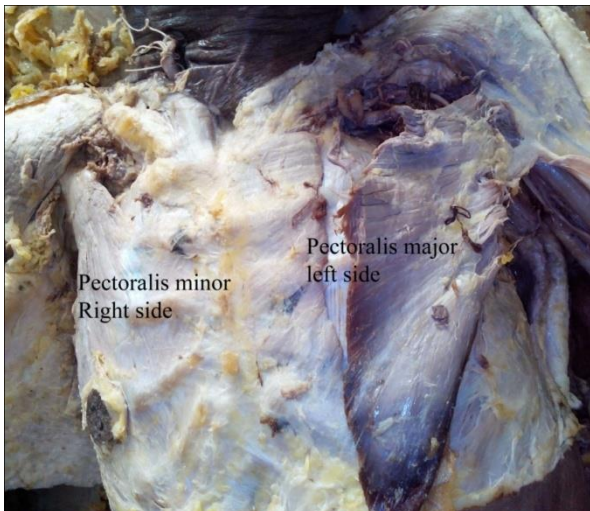


Fig-1: Absence of Pectoralis Major Muscle on Right side

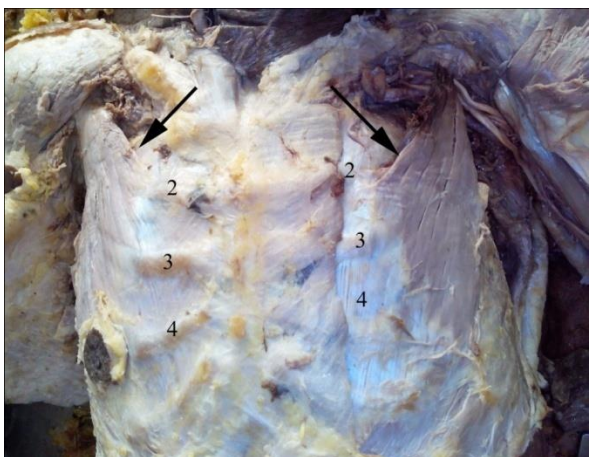


Fig-2: Higher origin of Pectoralis minor on right side compared to left side.

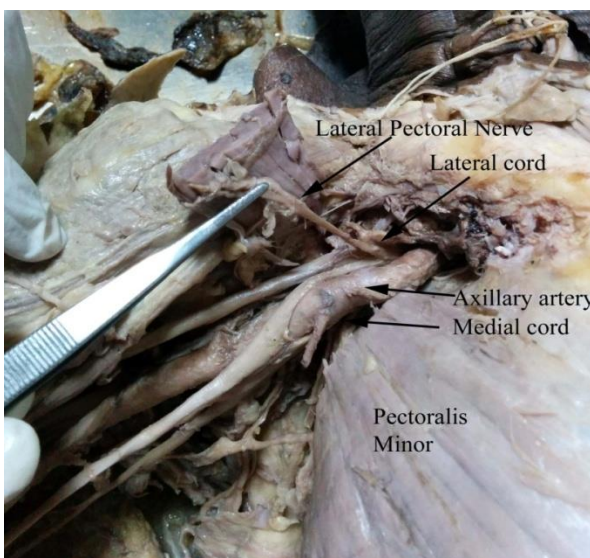


Fig-3: Lateral pectoral nerve supplying pectoralis minor.

DISCUSSION

Defects of the pectorals usually cause little or no functional disability and are often unnoticed by the patients or relatives[4]. Complete or partial absence of pectoralis major is more frequent as a part of Poland's syndrome but complete absence of pectoralis major without Poland's syndrome is rare, as in this case. Flint *et al* [6] found lack of functional disturbance in movement of shoulder joint due to absence of pectoralis major. Bing [5] reviewed cases of congenital absence of pectoralis major. According to his review pectoralis major was the most frequent muscle to be absent followed by trapezius.

In the above case the pectoralis major is completely absent. There is no other deformity pertaining to Poland's syndrome specially hand abnormalities, such as syndactyly, and hypoplasia of the ipsilateral nipple, areola, chest wall structures and scoliosis [7]. The pectoralis minor had tried to compensate the absence of pectoralis major by extending its origin from normal limit on the abnormal side. The compensatory hypertrophy can be visible grossly.

The above finding can be explained on the basis of failure of primitive pectoral mass to attach itself on clavicle, ribs sternum might cause its non differentiation into its normal component parts. Its absence may be attributed to vascular injury which compromises the circulation in this region during limb bud formation. Of the several theories advanced to the etiology of pectoral defects, the most quoted is that of Lewis [8]. He found that in the 9 mm embryo the pectoral muscle mass is largely above first rib. In the 11 mm embryo it extends lower but it is still undifferentiated into its component parts and it is not attached to the rib or humerus. The embryologic pathosis of the deformity is explained by faulty development of the upper limb bud. The possibilities are

- 1) These structures fail to develop in the embryo.
- 2) The muscles develop partially and fail to attach to the bone and subsequently atrophy
- 3) The pectoral pre-muscle mass which in normal development is going to form pectoralis major, pectoralis minor muscle fails to differentiate into its separate parts.

Similar case of absence of pectoral muscles has been reported by Rahbari H[8] without mentioning about pectoral nerves. Mosconi T *et al* [9] reported complete absence of pectoralis major muscle on right side and deficient sternal part of sternocostal head on the left side, without being part of Poland syndrome. They also reported bilateral absence of lateral pectoral nerve. But medial pectoral nerve was absent in our case.

Absence of medial pectoral nerve can be explained by nerve root dysgenesis theory postulated by Goldberg and Mazzel [10]. They put forward concept of local injury occurring in the 6-7 week old embryo, at the time when immature hand is juxtapositioned next to differentiating pectoralis major mass.

Variations are common in the formation of the brachial plexus. The prevalence of variations ranges from 12.8 up to 53%. Chiarapattanakom *et al* [11] described that the limb muscles develop from the mesenchyme of local origin, while axons of spinal nerves grow distally to reach the muscles. Guidance for the developing axons is regulated by expression of chemo-attractants and chemo-repellants in a highly coordinated site specific fashion, any alteration in signaling between mesenchymal cells and neuronal growth cones can lead to significant variations. The early contact between nerve and muscle cell is a prerequisite for their complete functional differentiation. Significant variations in nerve patterns may be a result of altered signaling between mesenchymal cells and neuronal growth cones or circulatory factors at the time of fusion of brachial plexus cords [11].

Whether the absence of pectoralis muscle is identified genetically is not known. If genetic determination is the case, the gene must be recessive and manifest itself rarely [8].

CONCLUSION

Clinically this anomaly can be diagnosed by appropriate check for the functions of these muscles. Isokinetic analysis of shoulder motion can detect its absence [12]. Clinical importance of such variations is seen while giving anaesthetic blocks, performing surgical procedures in axillary region, interpreting tumour or traumatic nerve compressions. The absence of pectoralis major also cut down the option of using pectoral myofascial flap for head and neck reconstructive surgery [13].

REFERENCES

1. Rijnberg WJ, Linge BV; Rupture of the pectoralis major muscle in body-builders. *Archives of Orthopaedic and Trauma Surgery*, 1993; 112(2): 104-105.
2. Standring S; *Gray's Anatomy: The Anatomical Basis of Clinical Practice*. 40th edition, Churchill Livingstone Elsevier, 2009; 807-809
3. Kardile PB, Ughade JM, Joshi RA, Herekar NG, Jadhav AS, Katti AS, Ughade MN; Unilateral Merging of Musculocutaneous Nerve with Variant Branching of Median Nerve. *International Journal of Recent Trends in Science And Technology*, 2012; 5(1):35-37.
4. Irvine ED, Tilley JB; Congenital absence of the pectoral muscles. *Arch Dis Child*, 1937; 12(68): 123-126
5. Bing R; Weber Angeborene Muskeldefekte. *Virchow's Arch f Path*, 1902; 170-175.
6. Flint MM, Drinkwater BL, McKittrick JE; Shoulder dynamics subsequent to a radial mastectomy. *Electromyography*, 1970; 10:171-182.
7. Poland A; Deficiency of pectoral muscle. *Greys Hosp Rep*, 1841; 6:191-193.
8. Rahbari H; Congenital Absence of Pectoral Muscles. *Calif Med*; 1972; 117:66-68.
9. Mosconi T, Kamath S; Bilateral asymmetric deficiency of the pectoralis major muscle. *Clin Anat*. 2003;16(4):346-9.
10. LewisWH; Development of the arm in man. *Am J Anat*, 1901; 1:145-185.
11. Chiarapattanakom P, Leechavengvons S, Witoonchart K, Uerpairojkit C, Thuvasethakul P; Anatomy and internal topography of the musculocutaneous nerve: The nerves to the biceps and brachialis muscle. *Journal of Hand Surgery*, 1998; 23 A:250-255.
12. Rasch PJ, Burke RK; *Kinesiology and applied anatomy*. 6th ed, Lea & Febiger, Philadelphia, 1978; 164.
13. Kruse AL, Luebbbers HT, Obwegeser JA, Bredell M, Gratz KW; Evaluation of the pectoralis major flap for reconstructive head and neck surgery. *Head & Neck Oncology*, 2011; 3:12.