

## Original Research Article

### **Histopathological Study of Undescended Testis in Pediatric Age Group**

**Dr. Sudipto Konar<sup>1</sup>, Dr Sumohan Biswas<sup>2</sup>, Dr Tamal Kanti Ghosh<sup>3</sup>, Dr Kalyan Brata Singha<sup>4</sup>, Dr Maloy Kumar Mondal<sup>5</sup>**

<sup>1</sup>Assistant Professor, Department of Anatomy, Burdwan Medical College, West Bengal, India

<sup>2</sup>Associate Professor, Department of Anatomy, Midnapore Medical College, West Bengal, India

<sup>3</sup>Professor, Department of Pathology, Midnapore Medical College, West Bengal, India

<sup>4</sup>Assistant Professor, Department of Anatomy, Midnapore Medical College, West Bengal, India

<sup>5</sup>Associate Professor, Department of Anatomy, Burdwan Medical College, West Bengal, India

#### **\*Corresponding author**

Dr Sudipto Konar

Email: [sudiptokonar@gmail.com](mailto:sudiptokonar@gmail.com)

---

**Abstract:** After development of the testis in the abdominal cavity, if its descent is arrested anywhere along its normal pathway of migration undescended testis results. Undescended testis is a multifactorial disease as the specific mechanism and factors involved in testicular descent are partly obscure. In addition to infertility, undescended testis is highly susceptible for malignant transformation. This study was designed to survey the various histopathological changes of undescended testis in pediatric age group. For this purpose we have evaluated testicular biopsy specimens from 116 boys with undescended testis who were treated surgically. Microscopic examination showed that in undescended testis the epithelium of the seminiferous tubules undergoes extensive atrophy with maturation arrest and significant reduction of germ cells while the interstitial cells are actually found to be increased in numbers. The longer the testicle resides outside the scrotum, the greater the chances of harm to the seminiferous tubules. This study suggests early orchiopey and promotes importance of testicular biopsy for providing valuable prognostic information.

**Keywords:** Undescended testis, Histology, Testicular descent, Pediatrics, Biopsy, Orchidopexy.

---

#### **INTRODUCTION:**

Testis after its development at the lumbar region of abdominal cavity descends to the scrotum to avoid increased intra-abdominal temperature. This descent of testis is facilitated by increase intra-abdominal pressure, the traction of gubernaculum, contraction of arched fibers of internal oblique muscle, uncurling of the fetal curve and secretion of some hormone from interstitial cells of fetal testis. This descent may be arrested at its normal pathway due to several reasons resulting partially descended testis. The topics regarding its etiology, pathophysiology affecting developmental process, investigations and treatment modalities are controversial and much debated [1-2].

Numerous theories have suggested the possible mechanism of normal testicular descent. Clinical and experimental observations supporting and refuting each theory therefore have failed to confirm any one explanation completely. Some authors believe that traction of gubernaculum leads to testicular descend [3]. The gubernaculum has been shown to be androgen responsive and is believed to create a downward force on the testis in some species [4-5]. Experimental

transection of the gubernaculum or division of the genito femoral nerve, which indirectly furnishes the gubernaculum, prevents testicular descent in some animals [6]. The role of testosterone in testicular descent is evident in patients with complete androgen insensitivity syndrome [7].

Patients with undescended testis usually present with empty scrotum and pain in the groin. Apart from psychological and cosmetic problems other common complications of undescended testis include torsion, inguinal hernia and trauma to the organ. The condition is also associated with potential long-term risks of infertility and malignancy [8-9]. So, early diagnosis and management of the undescended testicle are needed to preserve fertility and improve early detection of testicular malignancy.

Testicular biopsy is performed in men with risk factors for testicular malignancy. There is an increased risk for carcinoma in situ of the testis especially with a history of cryptorchidism [10]. Thus testicular biopsy is strongly recommended during orchiopey in cryptorchid boys as it has a prognostic

value with respect to fertility and the probability of discovering carcinoma in situ [11].

Histopathological changes associated with undescended testis are still a matter of curiosity. The present study was proposed to find out presence and spectrum of microscopical irregularities in undescended testis in the pediatric age group. These findings may help us in choosing treatment modalities concerned with fertility prognosis and malignancy.

#### **MATERIAL & METHODS:**

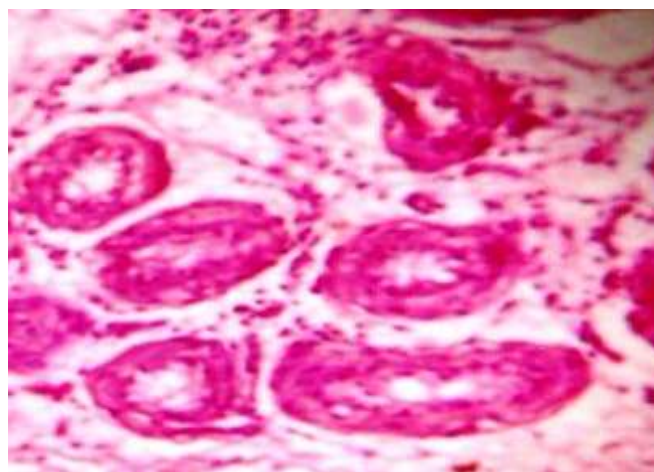
This study was conducted on 116 patients of pediatric age group [12] presented to the surgical OPD with empty scrotum. The study was approved by the Institutional Ethics Committee of the Burdwan Medical College of the West Bengal University of Health Sciences. Informed consents were obtained from the parents of the children included in this study.

After recording detailed history careful local examinations and routine clinical evaluations were done. Radiological examinations as USG were done to determine the presence and location of the undescended testis. Standard single stage Fowler-Stephens orchidopexy (exploration of inguinal canal,

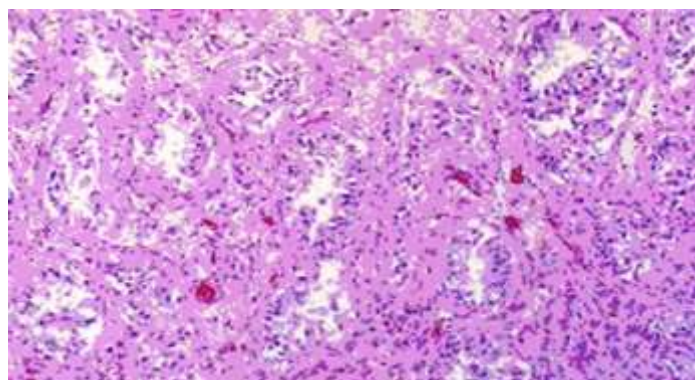
mobilization of testis by lengthening of the cord, fixation of testis at the dartos pouch) was done in 110 cases. Two stage Fowler-Stephens orchidopexy was planned in 2 cases with very short spermatic vessels to reduce the risk of a non-viable testis if placed into the scrotum without staging. But in 4 cases orchiectomy was done to remove atrophic testis. Testes were subjected to biopsy and histopathological examination after proper tissue processing and staining by haematoxylin and eosin method. During microscopic examination special attention was given to the position and structure of seminiferous tubules; natures of Sertoli cells, Leydig cells and germ cells.

#### **RESULT:**

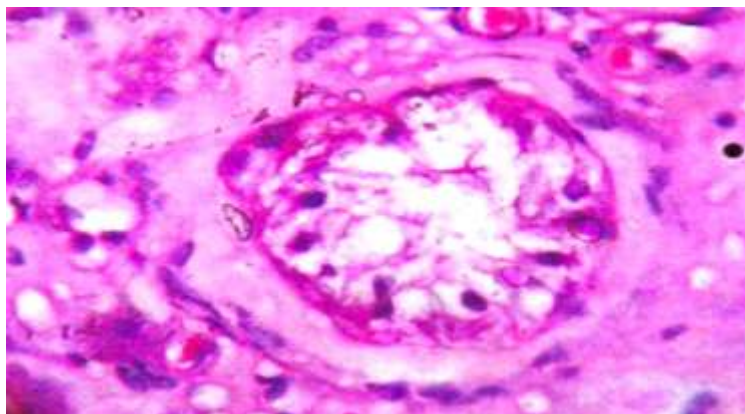
Cryptorchid testes are much smaller than normal. The seminiferous tubules are atrophic or hypoplastic and there is gradual reduction in coiling with age. The basement membrane shows gradual thickening (Figure 1) and peritubular fibrosis (Figure 2). The germinal epithelium is generally largely absent (Figure 3) after the age of five years due to maturation arrest. The Sertoli cell population progressively decreases with age but the Leydig cell number remains unchanged or even increased. Age wise histopathological findings are summarized in Table 1.



**Fig-1: Thickened tubular basement membrane (X 300)**



**Fig-2: Numerous Sertoli cells with peritubular fibrosis (X 100)**



**Fig-3: Reduced germ cells (X 300)**

**Table-1: Histopathological findings of undescended testis**

Age	Nature of Seminiferous tubules	Diameter of tubules	Cellularity (Germ Cells)	Basement Membrane	Sertoli Cells	Leydig cells
< 2 Years	Slightly tortuous	Small	Undifferentiated cells, Occasional spermatogonia present	Normal	Nil	-
2-5 Years	No increase in tortuosity	Small	Decreased cellularity, No increase in number of spermatogonia	Gradual thickening	Nil	Appear
5-10 Years	Decrease in tortuosity	Smaller	No Spermatogonia, cellularity decreased further	Thickened & peritubular fibrosis	Focal area of hyperplasia	Usually normal
10-15 Years	Reduced tortuosity	Much smaller	No Spermatogonia, marked decreased in cellularity	More thickened & prominent peritubular fibrosis	Tubules populated only by Sertoli cells	Increase in number
>15 Years	Markedly reduced tortuosity	Smallest	Absence of germ cell layer	Markedly thickened & peritubular fibrosis	Few in number	Hyperplasia & interstitial fibrosis

**DISCUSSION:**

The late descent of a testicle into the scrotum may impair its development. In this series histopathological outline was based on evidence of testicular hypotrophy indicated by decrease in germ cells, Sertoli cells, thickened basement membrane and prominent Leydig cells. This study shows that cases aged below the age of two years had no significant histological changes. Previous observers also have noted no significant differences in testicular histology from birth to 6 months of life and smaller seminiferous tubules only up to 3 years of life; though thereafter progressive diminution of tubular diameter, absence of spermatogonia, thickened basement membrane etc become obvious [13-14].

Several studies indicate that early surgical treatment can reverse testicular growth retardation and improve fertility. But different researches have pointed out the dissimilar age limit up to which germ cells were visible in cryptorchid testis as one year [13], 2 years [15], or even at the end of 3<sup>rd</sup> year of life [14].

The longer the testis resides away from normal location, the greater the damage to the seminiferous tubules. Previous reports have shown that there is a chance of 87.5% fertility rate if orchiopexy done between 1-2 years of age but the rate becomes only 13% after the age of 13 years [16]. Elder showed the fertility rate maximum if the orchiopexy done by 18 months of age [4]. Our study findings of decreased germ cells, thickened basement membrane and

predominance of Sertoli cells occur after the age of 5 years.

Undescended testes frequently manifest testicular carcinoma in situ (CIS) cells prior to frank formation of germ cell tumors. As testicular tumors may not only develop in the undescended testis but also in the contralateral descended partner as well, even bilateral testicular biopsies may be indicated [17].

#### CONCLUSION:

Prepubertal testicular biopsies can predict significant undescended testis associated pathologies and allow assessment of fertility. Earlier referral may be warranted for nonpalpable testes in the newborn. For an accurate histological categorization proper tissue handling, fixation and evaluation are needed. Considering the relatively high frequency of malignant tumors in adults with undescended testis, testicular biopsies should be performed even if a primary orchidectomy is refused.

#### REFERENCES:

1. Turek PJ, Ewalt DH, Snyder 3rd HM, Stampfers D, Blyth B, Huff DS, *et al.*; The absent cryptorchid testis: surgical findings and their implications for diagnosis and etiology. *The Journal of urology*. 1994; 151(3):718-20.
2. Ludwikowski B, González R; The controversy regarding the need for hormonal treatment in boys with unilateral cryptorchidism goes on: a review of the literature. *European journal of pediatrics*. 2013; 172(1):5-8.
3. Radhakrishnan J, Morikawa Y, Donahoe PK, Hendren WH; Observations on the gubernaculum during descent of the testis. *Investigative urology*. 1979; 16(5):365-8.
4. Elder JS, Keating MA, Duckett JW; Infant testicular prostheses. *The Journal of urology*. 1989; 141(6):1413-5.
5. Wensing CJ; Testicular descent in some domestic mammals. 3. Search for the factors that regulate the gubernacular reaction. *Proceedings of the Koninklijke Nederlandse Akademie van Wetenschappen. Series C. Biological and medical sciences*. 1972; 76(2):196-202.
6. Tayakkanonta K; The gubernaculum testis and its nerve supply. *Australian and New Zealand Journal of Surgery*. 1963; 33(1):61-7.
7. Konar S, Dasgupta D, Patra DK, De A, Mallick B; Chromosomal study is must for prepubertal girl with inguinal hernia: opportunity to diagnose complete androgen insensitivity syndrome. *Journal of clinical and diagnostic research: JCDR*. 2015; 9(4):GD01.
8. Carizza C, Antiba A, Palazzi J, Pistono C, Morana F, Alarcon M; Testicular maldescent and infertility. *Andrologia*. 1990; 22(3):285-8.
9. Martin DC; Malignancy in the cryptorchid testis. *The Urologic clinics of North America*. 1982; 9(3):371-6.
10. Dohle GR, Elzanaty S, van Casteren NJ; Testicular biopsy: clinical practice and interpretation. *Asian J Androl*. 2012; 14(1):88-93.
11. John TJ; IAP policy on age of children for pediatric care. *Indian pediatrics*. 1999; 36(5):461.
12. Hadžiselimović F, Hecker E, Herzog B; The value of testicular biopsy in cryptorchidism. *Urological research*. 1984; 12(3):171-4.
13. Mengel W, Hienz HA, Sippe WG, Hecker WC; Studies on cryptorchidism: a comparison of histological findings in the germinative epithelium before and after the second year of life. *Journal of pediatric surgery*. 1974; 9(4):445-50.
14. Houissa S, de Pape J, Diebold N, Feingold J, Nezelof C; Cryptorchidism: histologic study of 220 biopsies with clinico-anatomical correlations. *Cryptorchidism, diagnosis and treatment*. Paris. 1979:14-26.
15. Hadžiselimovic F, Duckett JW, Snyder HM, Schnauffer L, Huff D; Omphalocele, cryptorchidism, and brain malformations. *Journal of pediatric surgery*. 1987; 22(9):854-6.
16. Ludwig G, Potempa J; Der optimale zeitpunkt der behandlung des kryptorchismus. *DMW-Deutsche Medizinische Wochenschrift*. 1975; 100(13):680-3.
17. Hedinger CE; Histopathology of undescended testes. *European journal of pediatrics*. 1982; 139(4):266-71.