

## **Original Research Article**

### **Evaluation of Healing Effects and Anti-Oxidant Activity of *Pongamia pinnata* seed extract on acetic acid-induced Colitis**

Himanshu Sharma<sup>1†</sup>, Prakash Dubey<sup>1</sup>, D K Jain<sup>1</sup>, P K Phadnis<sup>1</sup>, Punya Pratap Singh<sup>2</sup>, R K Goel<sup>3</sup>

<sup>1</sup>Department of Pharmacology, Bundelkhand Medical College, Sagar 470001, MP, India

<sup>2</sup>Department of Radiodiagnosis, Bundelkhand Medical College, Sagar 470001, MP, India

<sup>3</sup>Department of Pharmacology, Institute of Medical Sciences, Banaras Hindu University, Varanasi 221005, India

#### **\*Corresponding author**

Himanshu Sharma

Email: [himanshugsvm@gmail.com](mailto:himanshugsvm@gmail.com)

---

**Abstract:** The main objective is to evaluate the healing effects of 50% ethanolic extract of dried seeds of *Pongamia pinnata* on acetic acid-induced colitis in rats. The method is *Pongamia pinnata* seed extract was administered orally, once daily for 14 days in rats after the induction of colitis with acetic acid and 50 mg/kg dose of extract was found to have an optimal effect against acetic acid-induced colonic damage score, weight and adhesions. Effect of above dose of the extract was then further studied for its effects on faecal output, food and water intake and body weight changes during 14 days of study. Colonic mucosal damage and inflammation and status of colonic mucosal antioxidants, superoxide dismutase and reduced glutathione; free radicals, nitric oxide and lipid peroxidation were studied on 15th day of acetic acid-induced colitis. Antibacterial activity of the extract was also studied using in vitro procedures. In results the *Pongamia pinnata* seed extract decreased colonic mucosal damage and inflammation, faecal output and increased body weight. *Pongamia pinnata* seed extract showed intestinal antibacterial activity and enhanced the antioxidants but decreased free radicals activities. Acute toxicity study indicated no mortality or other ANS or CNS related adverse effects even with 500 mg/kg dose (10 times of effective dose) indicating its safety. The conclusion in this study is *Pongamia pinnata* seed extract seemed to be safe and effective in colitis by its predominant effect on promoting antioxidant status and decreasing intestinal bacterial load, free radicals responsible for tissue damage and delayed healing.

**Keywords:** *Pongamia pinnata*, Colitis, Free radicals, Antioxidants.

---

#### **INTRODUCTION**

Ulcerative colitis (UC) is a refractory, chronic, and nonspecific disease of colon. It typically involves the innermost lining (mucosa), manifesting as continuous areas of inflammation and ulceration. Symptoms include a progressive loosening of the stool, abdominal cramps, rectal bleed and loss of appetite that result in nutrient deficiencies, weight loss and anemia [1]. Although the exact cause of ulcerative colitis remains undetermined, the condition appears to be related to a combination of genetic, microbial and environmental factors that influence the normal intestinal commensal flora to trigger an inappropriate mucosal immune response. Among the pathological findings associated with UC are an increase in certain inflammatory mediators, signs of oxidative stress, a deranged colonic milieu, abnormal glycosaminoglycan content of the mucosa, decreased oxidation of short chain fatty acids and increased intestinal permeability [2, 3]. Reactive oxygen species (ROS) mediated injury plays an important role in the pathophysiology of UC.

Chronic inflammation, infection or immune imbalance increases production of ROS and impairs antioxidant defenses, resulting in intestinal oxidative injury in UC patients [4].

*Pongamia pinnata* Linn is a medium-sized, glabrous, semi-evergreen tree, growing up to 18 m or higher, with a short bole, spreading crown with grayish green or brown bark. This tree is popularly known as Karanja in Hindi, Indian Beech or Derris indica in English. Seeds of this plant also have medicinal properties and traditionally used in hypertension, bronchitis, whooping cough, skin diseases, leucoderma, leprosy, lumbago, and muscular and articular rheumatism. *P. pinnata* seed and seed oil have been reported to possess hypoglycemic, anti-oxidative, anti-ulcerogenic, anti-inflammatory and analgesic properties [5]. We earlier reported analgesic, anti-inflammatory, hypnotic and antiulcerogenic activities of extract of *Pongamia pinnata* seeds [6].

The present study was undertaken to evaluate healing effects of 50% ethanol extract of *P. pinnata* seed in acetic acid-induced colitis in rats.

## MATERIALS AND METHODS

### Animals

Inbred Charles-Foster albino rats (160-180 g) and mice (25-30 g) of either sex were obtained from the central animal house of Institute of Medical Sciences, Banaras Hindu University, and Varanasi. They were kept in the departmental animal house at  $26 \pm 20$  C and relative humidity 44-56%, light and dark cycles of 10 and 14 h respectively for 1 week before and during the experiments. Animals were provided with standard rodent pellet diet (Pashu Aahar, Ramnagar, and Varanasi) and water ad libitum. 'Principles of laboratory animal care' (NIH publication no. 82-23, revised 1985) guidelines were followed. Approval from the Institutional Animal Ethical Committee was taken prior to the experimental work (Notification no.: Dean/10-11/276 dated 13.10.2010).

### Plant material and preparation of extract

Seeds of *P. pinnata* were collected during month of June, 2010 from the Ayurvedic Garden, Banaras Hindu University. The shells of the seeds were removed and the seeds were dried at room temperature and crushed to fine particles. 50% ethanol extract was prepared by adding 500 ml of ethanol and an equal amount of distilled water in 200 g of dried fine powder of *P. pinnata* seed. The mixture was shaken at intervals and the extract so obtained was filtered after an interval of two days. The procedure was repeated twice at an interval of two days. The ethanol containing extract so obtained each time was mixed and later dried at 400C in incubator. The yield was about 22.0 % (w/w).

### Drug and chemicals

Sulfasalazine (SAZO, WALLACE); acetic acid obtained from Merck Ltd., Mumbai, India, and all the other chemicals and reagents were used of analytical grade.

### Induction of colitis and treatment protocol

Experimental colitis was produced by intracolonic administration of acetic acid (10%, 0.20 ml/100 g rat) given per rectally [7]. A dose response study was first undertaken with 50% ethanol extract of *P. pinnata* seed (25, 50 and 100 mg/kg) when given orally for a period of 14 days after the induction of UC with acetic acid and on 15th day of experiment, the healing effect was studied on the colonic mucosal damage score, weight and adhesions in acetic acid-induced colitis. 50 mg/kg of *P. pinnata* seed extract showed optimal protective effects against acetic acid-induced changes on the colonic mucosal weight, damage score and adhesions (Figure 1) and was used for further detailed study on faecal output, food intake and water intake and body

weight changes on the day 0, 2, 4, 6, 10 and 14 of experiment in acetic acid-induced colitis rats. The animals were sacrificed on 15th day after intra-colonic administration of either normal saline (negative control) or acetic acid (control) and after treatments with *P. pinnata* seed extract (test extract, 50 mg/kg) and sulfasalazine (positive control, 100 mg/kg)[8] in acetic acid induced colitis rats. *P. pinnata* seed extract and standard UC protective drug, sulfasalazine suspension was prepared in 0.5% carboxymethyl cellulose (CMC) and administered orally, once daily in the volume of 1 ml/100 g rat for 14 days after the induction of colitis. The results of the acetic acid group were compared with normal saline group while the treatment groups were compared with acetic acid group.

### Assessment of faecal output and changes in body weight, food and water intake

Faecal output and changes in body weight, food and water intake were observed in intracolonic normal saline and intracolonic acetic acid-induced colitis per se and after administration of *P. pinnata* seed extract and sulfasalazine. 24 hr faecal output of individual rat was measured and then faecal output was calculated for each group. Similarly, each rat of normal saline/acetic acid and acetic acid plus *P. pinnata* seed extract/sulfasalazine group was individually weighed using standard rat weighing machine and their respective weights were noted down. Weight/volume of food/water was measured after giving fixed amount of food and water in the respective cage to each rat at a fixed time of day and next day the amount of food and water left was measured again to calculate the amount of food and water intake by an individual rat. The above effects were seen on day 0 (before induction) and after 2, 4, 6, 10 and 14th day of induction of colitis. The result of acetic acid was compared with normal saline (without colitis) while that of *P. pinnata* extract/sulfasalazine treated groups were compared with acetic acid group on respective day study.

### Assessment of colonic damage and inflammation and histopathology

All scorings of damage and excision of tissue samples were performed by an observer unaware of the treatment group. The rats in the various treatment groups were randomized before being sacrificed. The rats were weighed and sacrificed by over dose of ether and proximal 8 cm of colon was removed. The colon was opened by a longitudinal incision, rinsed with tap water and pinned out on a wax block. Macroscopically visible damage was scored on a 0-10 scale using the scoring system as described by Morris *et al.*; [7], which takes into consideration the area of involvement and the presence or absence of ulcers, adhesions to surrounding tissue and thickness. Subsequently 8 cm of colon were taken for measurement of weight and the weight was then expressed as mg/per cm length of colon.

Histopathology of the colon was done in all the groups on 15th to know the status of healing. A piece of colon was removed and fixed in 10% buffered formalin and paraffin embedded. 4-6  $\mu$ m thick sections were stained with Hematoxylin and Eosin stain for histological evaluation and examined under microscope at 100 X magnification.

#### Estimation of colonic mucosal antioxidants and free radicals

Antioxidants, superoxide dismutase (SOD) and reduced glutathione (GSH); and free radicals, lipid peroxidation (LPO) and nitric oxide (NO) and protein were estimated in colonic mucosal homogenates following the standard procedures [7]. SOD was expressed as mU/mg protein while GSH, LPO, NO were expressed as nmol/mg protein.

#### Antimicrobial susceptibility and minimum inhibitory concentration (MIC)

In vitro antibacterial susceptibility test of *P. pinnata* seed extract was done using serial concentrations of 50, 100, 150 and 200 mg/ml following the approved standards of the National Committee for Clinical Laboratory Standards[9] against various intestinal pathogens i.e. *Escherichia coli* ATCC 25922, *Shigella boydii*, *Shigella sonnei* and *Shigella flexneri* obtained from the American Type Culture Collection (ATCC) and clinical strain preserved at Department of Microbiology, Institute of Medical Sciences, BHU, Varanasi, India following the disk diffusion method while, minimum inhibitory concentration (MIC) was performed by micro dilution method[10].

#### Acute toxicity study in mice

Adult Charles Foster strain albino mice of either sex, weighing between 20 to 25g fasted overnight, were used for toxicity study. Suspension of *P. pinnata* was orally administered at 500 mg/kg stat dose (10 times of the optimal effective dose of 50 mg/kg) to mice. Subsequent to *P. pinnata* extract administration, animals were observed closely for first four hours, for any toxicity manifestation, like increased motor activity, salivation, convulsion, coma and death. Subsequently observations were made at regular intervals for 24 h. The animals were under further investigation up to a period of 14 days [11].

#### Statistical analysis

Statistical comparison was performed using either unpaired 't' test or one way analysis of variance (ANOVA) and for multiple comparisons versus control group was done by Dunnett's test. All statistical analysis was performed using SPSS statistical version 16.0 software package (SPSS® Inc., USA). P value <0.05 were considered statistically significant.

## RESULTS

### Effects on colonic damage, inflammation and adhesions

Untreated rats, receiving 0.5% carboxymethyl cellulose orally daily, were given normal saline instead of acetic acid in the colon intrarectally did not show any colonic mucosal damage or adhesions at 15th day of experiment while, the colonic weight (8 cm of proximal colon) was found to be  $145.0 \pm 8.2$  mg/cm. The acetic acid intra-rectally led to significant increase in colonic mucosal damage score ( $6.16 \pm 0.54$ ,  $P < 0.001$ ) and adhesions (5/6 rats, 83.3%) and increase in colonic weight to  $227.6 \pm 17.3$  mg/cm (63.8% increase,  $P < 0.00$ ) compared with normal saline value indicating an extensive colonic tissue damage, adhesions, inflammation together with oedema. *P. pinnata* seed extract when given in graded doses of 25, 50 and 100 mg/kg for 14 days, once daily, orally as suspension in 0.5% CMC showed dose-dependent decrease in damage score from 44.3 to 79.4% ( $P < 0.01$  to  $P < 0.001$ ), colonic weight from 24.8 to 39.2% ( $P < 0.01$  to  $P < 0.001$ ) and tissue adhesions from 40.0 to 60.0%. The protective effects of *P. pinnata* seed extract (50 mg/kg) against acetic acid-induced changes on the colonic mucosal weight, damage score and adhesions were comparable with standard UC protective drug, sulfasalazine (Figure 1).

### Effects on body weight, faecal output and food and water intake

Mean body weight of normal saline, acetic acid and acetic acid plus oral *P. pinnata* extract or sulfasalazine treated rats at day 0 ranged from  $172.2 \pm 3.78$  to  $174.9 \pm 3.51$ g. Normal saline (negative control) treated rats showed a gradual increase in body weight from 6.3 to 28.0% while, AA-induced colitis rats (control) showed decrease in body weight from day 2 onwards till 14th day of study compared to normal saline-treated rats. Treatments with *P. pinnata* seed extract (test extract) and sulfasalazine (positive control) for 14 days reversed the decreasing trend in body weight (Figure 2a). However, little or no change was observed on food and water intake between the acetic acid-induced colitis group and *P. pinnata* seed extract group and sulfasalazine treated animals from 0 day to 14th day of study treatments.

Mean faecal output of intracolonic normal saline and acetic acid treated and acetic acid plus oral *P. pinnata* extract or sulfasalazine treated rats at day 0 ranged from  $4.58 \pm 0.45$  to  $4.79 \pm 0.51$ g per 100 g body weight. Carboxymethylcellulose (0.5%) oral treated normal saline rats showed little or no change in faecal output while, acetic acid rats showed increase in faecal output from 29.0 to 63.0% from day 2 to day 6 and then declined to 47 and 30% at day 10 and 14 respectively. Oral administration of *P. pinnata* seed extract (50 mg/kg) and sulfasalazine (100 mg/kg), once daily for 14

days in acetic acid-induced colitis rats showed significant decrease in faecal output from day 4

onwards till the 14 days of study period (Figure 2b).

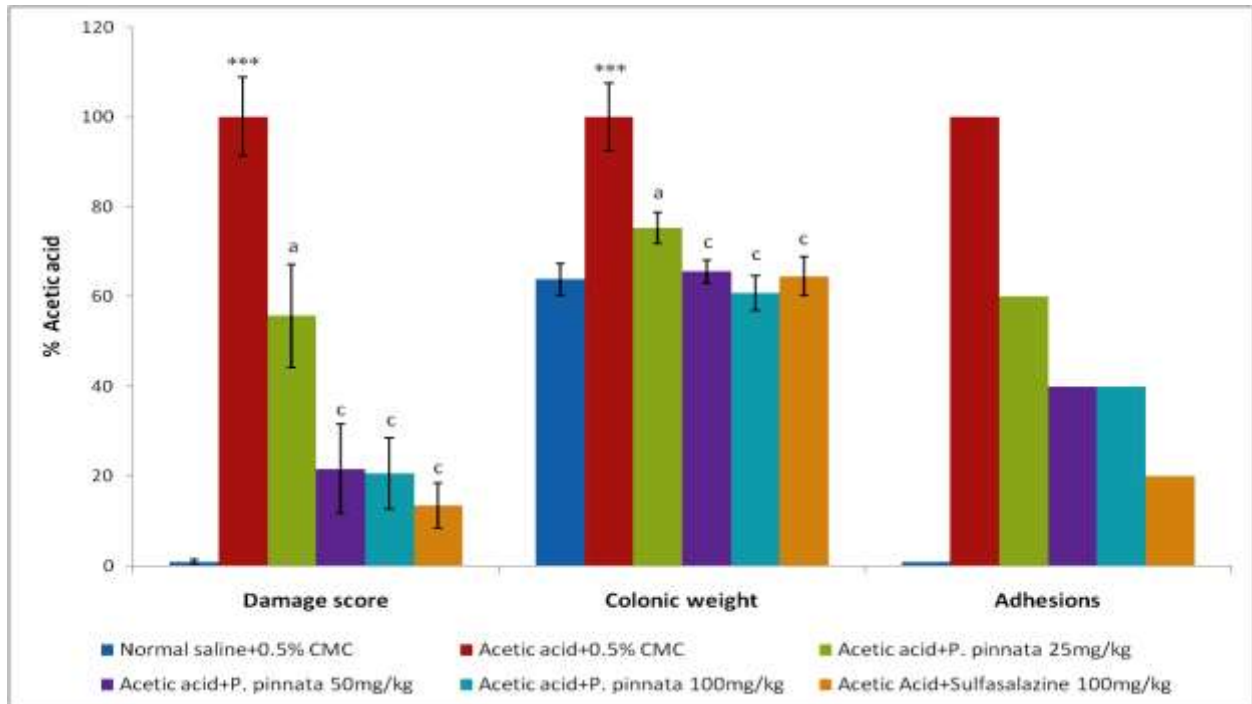
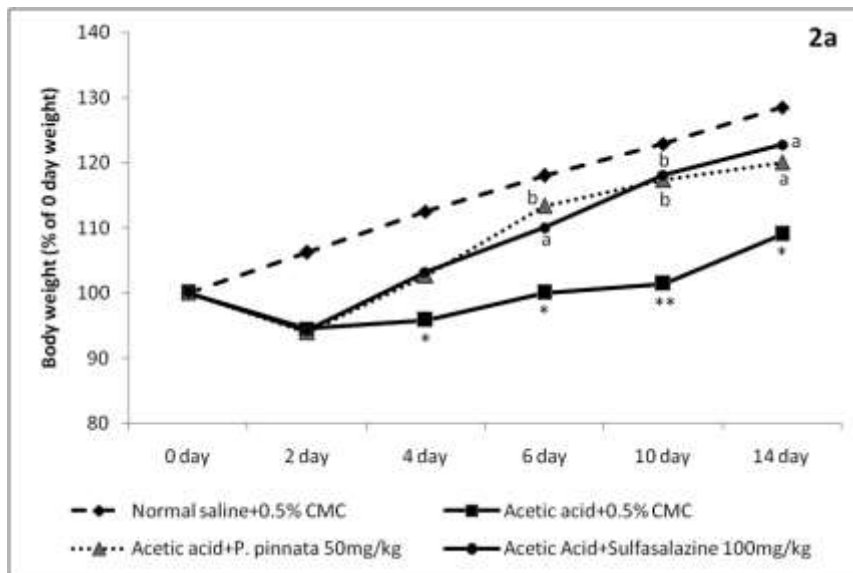
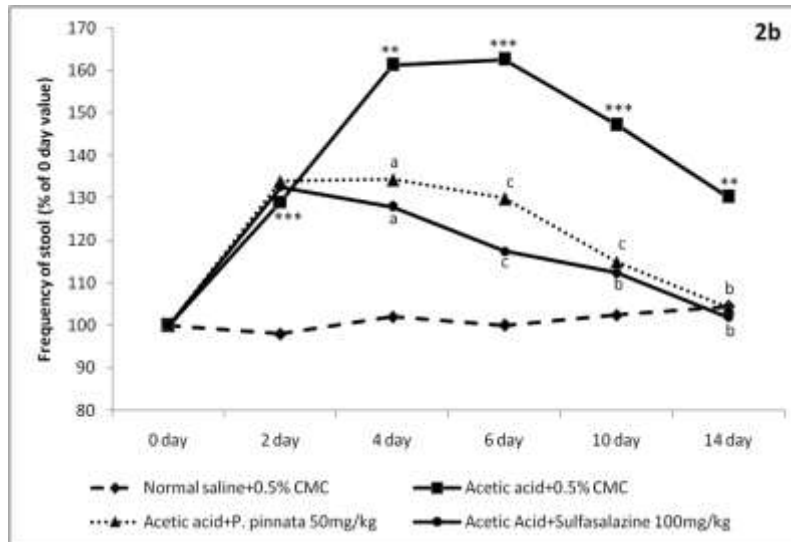


Fig 1: Effect of graded doses of 50% ethanolic *Pongamia pinnata* seed extract (25, 50 and 100 mg/kg, oral, once daily for 14 days) on acetic acid-induced rat colonic mucosal damage score, weight and adhesions.

Results are % mean value of acetic acid  $\pm$  SEM (n=6). \*P<0.001 compared to respective normal saline group (unpaired 't' test) and bP<0.01, cP<0.001 compared to respective acetic acid group (ANOVA followed by Dunnett's test for multiple comparisons).





**Fig 2: Effects of *P. pinnata* seed extract (50 mg/kg) on changes in faecal output (2a) and body weight (2b) in acetic acid-induced colitis rats.**

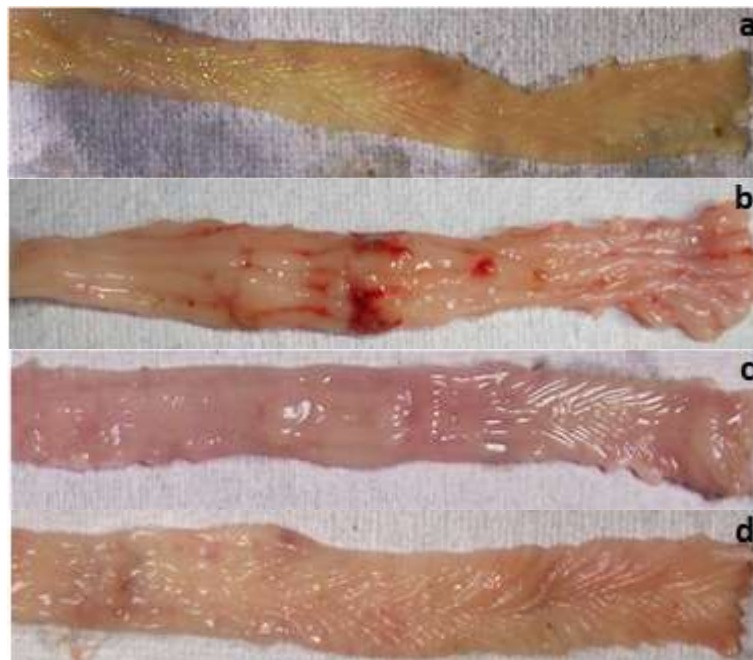
\*P<0.05, \*\*P<0.01, \*\*\*P<0.001 compared to normal saline group (unpaired 't' test) and <sup>a</sup>P<0.05, <sup>b</sup>P<0.01, <sup>c</sup>P<0.001 compared to acetic acid group (ANOVA followed by Dunnett's test for multiple comparisons).

**Histopathology study**

**Macroscopic study**

The figure 3a shows the features of colon of orally treated CMC rats after normal saline enema. The figure 3b shows colon of intra-colonic acetic acid-treated rats on oral CMC treatment having significant hydropsia, necrosis, erosion and ulceration. The figures 3c and 3d

show the colons of acetic acid-induced colitis treated orally with *P. pinnata* seed extract and sulfasalazine respectively. The severity of hydropsia, necrosis and ulceration were significantly reduced by them. The results of *P. pinnata* treated group were comparable with sulfasalazine treated group.

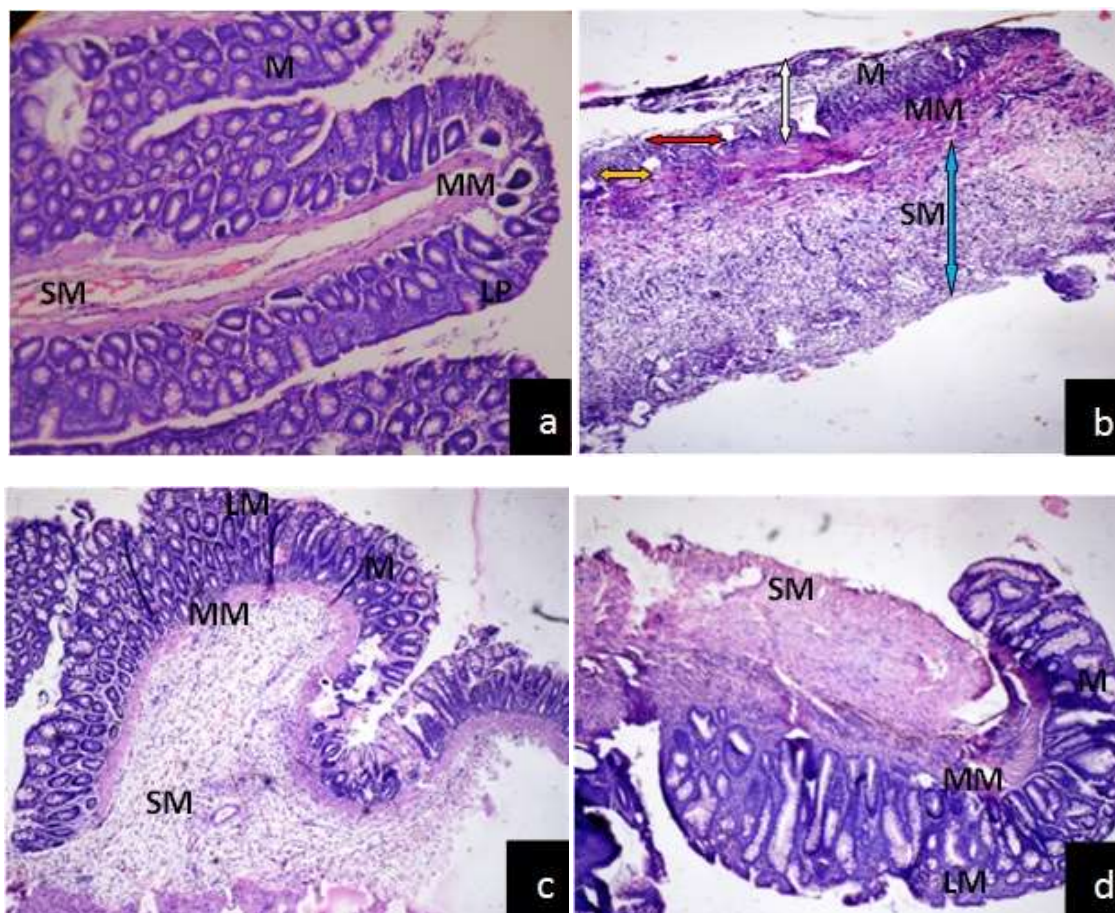


**Fig 3: Macroscopy of rat colonic mucosa 3a: Normal saline enema treated colon with oral CMC showing normal morphology; 3b-d: Colon of acetic acid-induced colitis treated with; 3b: oral CMC showing necrosis, erosion, hydropsia and ulceration; 3c and 3d: *P. pinnata* seed extract (50 mg/kg) and sulfasalazine (100 mg/kg) respectively showing reduction in ulceration, hydropsia, erosion and necrosis.**

### Microscopic study

The figure 4a shows the morphology of colon of normal saline enema treated colon of rats treated orally with CMC. The structure is relatively normal and clear with intact epithelia. The figure 4b shows the colon histology of acetic acid-colitis rat with oral CMC. There were crypt destruction with severe cryptitis and

lymphocytic infiltration in mucous layer with sub mucosal edema. The figures 4c and 4d show the improvement in the structures with regenerative mucosa and mild lympho-plasmacytic infiltrate in the lamina propria after treatment with *P. pinnata* seed extract and sulfasalazine respectively.



**Figure 4.** Histological section of rat colon stained with H & E stain (x100). (a) Normal saline + CMC showing normal structure and clear with intact mucosa and sub mucosa. (b) Acetic Acid + CMC showing ulcerated and eroded mucosa shown by white arrow, crypt destruction with severe cryptitis shown by red arrow, lymphoplasmacytic infiltrate shown by yellow arrow and transmural inflammation (predominantly-lymphocytes and plasma cells) shown by blue arrow. (c) Acetic Acid + *Pongamia pinnata* (50 mg/kg) showing regenerative mucosa with mild crypt distortion, lympho-plasmacytic infiltrate in the lamina propria and sub mucosal oedema and (d) Acetic Acid + Sulfasalazine (100 mg/kg) showing intact mucosa with minimal lymphoplasmacytic infiltrate in the lamina propria. [M: Mucosa; SM: Sub mucosa; LP: Lamina propria; MM: Musculaires mucosa]

### Effects on colonic mucosal antioxidants and free radicals

Acetic acid-treated animals showed significant decrease in colonic mucosal antioxidants SOD (57.3%,  $P < 0.001$ ) and GSH (43.6%,  $P < 0.001$ ) and increase in free radicals LPO (150.8%,  $P < 0.001$ ) and NO (86.9%,  $P < 0.001$ ) level compared to normal saline-treated rats.

Both *P. pinnata* (50mg/kg, oral) and sulfasalazine (100 mg/kg, oral) when given for 14 days after acetic acid-induction of colitis reversed the above changes in antioxidants and free radicals compared to acetic acid-induced colitis rats. The above effects on antioxidant status and free radicals with *P. pinnata* seed extract were comparable with sulfasalazine group (Table 1).

**Table 1: Effect of *P. pinnata* seed extract and sulfasalazine on acetic acid-induced changes in free radicals (lipid peroxidation, LPO and nitric oxide, NO) and antioxidants (superoxide dismutase, SOD and reduced glutathione, GSH) in rat colonic mucosa**

Oral treatment (mg/kg, once daily x 14 days)	Free Radicals		Anti-oxidants	
	LPO nmol/mg protein	NO nmol/mg protein	SOD mU/mg protein	GSH nmol/mg protein
Normal saline + CMC 0.5%	6.3 ± 0.38	13.0 ± 1.12	394.4 ± 43.7	27.5 ± 2.77
Acetic acid + CMC 0.5%	15.8 ± 1.22 <sup>*</sup>	24.3 ± 2.36 <sup>*</sup>	168.3 ± 32.5 <sup>*</sup>	15.5 ± 1.29 <sup>*</sup>
Acetic acid + <i>P. pinnata</i> 50	4.9 ± 0.39 <sup>c</sup>	8.0 ± 0.70 <sup>c</sup>	329.1 ± 37.2 <sup>b</sup>	27.0 ± 2.99 <sup>b</sup>
Acetic acid + Sulfasalazine 100	6.6 ± 0.59 <sup>c</sup>	8.3 ± 0.29 <sup>c</sup>	317.8 ± 17.9 <sup>b</sup>	30.0 ± 2.18 <sup>c</sup>

Results are mean ± SEM (n=6).

\*P<0.001 compared to respective normal saline group (Unpaired 't' test) and <sup>b</sup>P<0.01, <sup>c</sup>P<0.001 compared to respective acetic acid group (one way analysis of variance followed by Dunnett's test for multiple comparisons).

### Antimicrobial susceptibility and MIC

*P. pinnata* seed extract showed positive susceptibility test against Escherichia coli ATCC 25922, Shigella boydii, Shigella sonnei and Shigella flexneri at 150 mg/ml against all the above gram negative intestinal bacteria showing zone of inhibition ≥10 mm. *P. pinnata* showed MIC value at 6.25 mg/ml against E. coli and S. flexneri and 12.5 mg/ml against S. sonnie and S. boydi.

### Acute toxicity study

*P. pinnata* even at 500 mg/kg oral dose did not show any acute toxicity manifestation like increased motor activity, salivation, colonic convulsion, coma and death, observed up to a period of 14 days.

### DISCUSSION

Acetic acid-induced colitis has been reported to resemble human inflammatory bowel disease in terms of the prolonged colonic inflammation and serves as a useful model to investigate the role of free radicals and antioxidants in the pathophysiology of colitis [12]. Our results with intracolonic administration of acetic acid showed increase in faecal output and loss of body weight without any significant change in the food and water intake. Diarrhoea with loss in body weight could be due to alterations in the GIT absorptive functions. Acetic acid intracolonic administration also led to significant increase in colonic mucosal damage score and adhesions (indicative of necrosis and ulcerations) and increase in colonic weight (indicative of inflammation and oedema) probably due to the direct necrotic action and subsequent inflammation and bacterial invasions. Microscopic study of the acetic acid-treated colon indicated extensive epithelial necrosis and edema with crypt destruction, severe cryptitis, and transmural inflammation (predominantly-lymphocytes and plasma cells). Microscopic study of the colon of acetic acid-induced colitis confirms our findings of macroscopic study where increase in colonic

weight, adhesions and mucosal damage were observed. This could be due to alterations in epithelial function, produced either directly or indirectly by products released from activated mast cells [13]. Rats treated with *P. pinnata* extract showed significant decrease in the severity of hydropsia in terms of decrease in colonic weight, necrosis and ulceration (decrease in colonic damage score and adhesions) enhanced in acetic acid-induced colitis and showed regenerative mucosa with mild crypt distortion and mild lympho-plasmacytic infiltrate in the lamina propria and its effect was comparable with sulfasalazine-treated group. These above effects may be attributed to the anti-inflammatory, antinociceptive and antiulcer properties of *P. pinnata* [6]. Many biological activities of *P. pinnata* seed extracts can be attributed to karanjin, the major flavonoid of the seed oil. Recently, anti-inflammatory effect of karanjin in rat models as substantiated by the inhibition of lipoyxygenase-1 and 5-LOX by karanjin [14].

Chronic inflammation due to infection, chemical irritation or immune imbalance increases production of reactive oxygen species (ROS) and impairs antioxidant defenses, resulting in oxidative-stress. ROS can be produced from both endogenous and exogenous substance. Potential endogenous sources include mitochondria, cytochrome P450 metabolism, peroxisomes and inflammatory cell activation [15]. Activated neutrophils and macrophages are responsible for ROS or reactive nitrogen species generation and the levels of ROS can be correlated with the severity of inflammatory changes in the colonic mucosa. Free radicals are released in both inflammatory bowel disease patients and animal models of colitis [16]. Reactive oxygen and nitrogen metabolites were suggested to be involved in the initiation and progression of ulcerative colitis and are major cause of tissue destruction [17, 18]. Oxidative stress therefore, may lead to detrimental lipid peroxidation, DNA and

protein damage, and disruption/activation of abnormal intracellular signaling pathways causing cytotoxicity and ulcerations and delays healing and thus elimination of ROS could be an important strategy in treatment of ulcerative colitis. Therefore, estimation of antioxidants like superoxide dismutase (SOD) and reduced glutathione (GSH) in colonic mucosal tissues has been relevant because these antioxidants hasten the process of healing by destroying the free radicals [7]. Our studies on the antioxidants and free radicals status revealed that *P. pinnata* extract alleviated inflammation with marked decrease in LPO and NO suggesting decrease in oxidative damage. It also increased SOD and GSH levels effectively counteracting the free radicals generated by cascade of reactions and promote the healing process.

The role of microbial content of the GI tract in the pathogenesis of ulcerative colitis is well documented. A higher concentration of intestinal bacteria than the normal colon has been observed in UC patients [19]. *P. pinnata* seed oil also been reported to show inhibition against the fungal and bacterial cultures [20]. Results of our study also revealed that *P. pinnata* seed extract possessed antimicrobial potential against intestinal pathogens like *Escherichia coli* ATCC 25922, *Shigella boydii*, *Shigella sonnei* and *Shigella flexneri*. The highest activity exhibited by *P. pinnata* extract at 150 mg/ml concentration was  $\geq 10$  mm, and considered as having effective antibacterial activity [21] and the antibacterial effect could be a contributory factor in helping healing of colitis induced by acetic acid in our present study. *P. pinnata* was also found to be safe as it did not show any mortality or ANS and CNS observable effects in acute toxicity study in mice.

The present study with the 50% ethanol extract of *P. pinnata* seed on various physical and biochemical parameters of colonic damage and inflammation induced by acetic acid showed its safety and effectiveness in colitis due to its predominant antibacterial, promoting antioxidant status and decreasing free radical-induced tissue damage.

#### Conflict of interest statement

We declare that we have no conflict of interest.

#### Acknowledgments

The authors' express sincere thanks to Department of Pharmacology, Faculty of Medicine, Institute of Medical Sciences, Banaras Hindu University, Varanasi, India, for providing the best facilities and funding for the research work.

#### REFERENCES

1. Kathleen A, Jurenka JS; Inflammatory Bowel Disease Part I: Ulcerative colitis—pathophysiology and conventional and

- alternative treatment options. *Alt Med Review* 2003; 8(3): 247–283.
2. Benson JM, Shepherd DM; Aryl hydrocarbon receptor activation by TCDD reduces inflammation associated with crohn's disease. *Toxicol Sci* 2010;120(1): 68–78.
3. Molodecky NA, Kaplan GG; Environmental risk factors for inflammatory bowel disease. *Gastroenterol Hepatol* 2010; 6(5): 339–346.
4. Khor B, Gardet A, Xavier RJ; Genetics and pathogenesis of inflammatory bowel disease. *Nature* 2011; 474(7351): 307–317.
5. Chopada VV, Tankar AN, Pande VV, Tekade AR, Gowekar NM, Bhandari SR, Khandake SN; *Pongamia pinnata*: Phytochemical constituents, traditional uses and pharmacological properties: A review. *Int J Green Pharmacy* 2008; 72–75.
6. Effect of methanolic extract of *Pongamia pinnata* seed on gastro-duodenal ulceration and mucosal offensive and defensive factors in rats. T. Prabha, M. Dorababu, Shalini Goel, P.K. Agarwal, A. Singh, V. K. Joshi, & R.K. Goel, *Indian J Exp Biol*, 2009,47:649-659.
7. Gautam MK, Goel S, Ghatule RR, Singh A, Nath G, Goel RK; Curative effect of *Terminalia chebula* extract on acetic acid-induced experimental colitis: role of antioxidants, free radicals and acute inflammatory marker. *Inflammopharmacol* 2012. [Available at: <http://www.springerlink.com/doi/10.1007/s10787-012-0147-3>].
8. Ghatule RR, Goel Shalini, Gautam MK, Singh A, Joshi VK, Goel RK; Effect of *Azadirachta indica* leaves extract on AA-Induced colitis in rats: Role of antioxidants, free radicals and myeloperoxidase. *Asian Pac J Trop Disease* 2012. [In press: [www.apjtc.com/press/2011/D147.docx](http://www.apjtc.com/press/2011/D147.docx)].
9. National Committee for Clinical Laboratory Standards NCCLS, Methods for dilution antimicrobial susceptibility tests for bacteria that grow aerobically: approved standards-fifth edition. NCCLS document M7-A5, (Wayne, PA, USA.) NCCLS, 2000.
10. Wiegand I, Hilpert K, Hancock REW; Agar and broth dilution methods to determine the minimal inhibitory concentration (MIC) of antimicrobial substances. *Nature Protocols* 2008; 3: 163–175.
11. Gautam MK, Singh A, Rao CV, Goel RK; Toxicological evaluation of *Murraya paniculata* (L.) leaves extract on rodents. *Am J Pharm Toxicol* 2012; 7(2): 62–67.
12. Tahan G, Aytac E, Aytekin H, Gunduz F, Dogusoy G, Aydin S, *et al.*; Vitamin E has a dual effect of anti-inflammatory and



- antioxidant activities in acetic acid-induced ulcerative colitis in rats. *Can J Surg* 2011; 54(5): 333–338.
13. Groshwitz KR, Ahrens R, Osterfeld H, Gurish MF, Han X, Abrink M, *et al.*; Mast cells regulate homeostatic intestinal epithelial migration and barrier function by a chymase/Mcpt4-dependent mechanism. *PNAS* 2009; 106(52): 22381–22386. DOI: 10.1073/pnas.0906372106
  14. Tamrakar AK, Yadav PP, Tiwari P, Maurya R, Srivastav AK; Identification of pongamol and karanjin as lead compounds with antihyperglycemic activity from *Pongamia pinnata* fruits. *J Ethnopharmacol.* 2008;118:435–9.
  15. Mangerich A, Knutson CG, Parry NM, Muthupalani S, Ye W, Prestwich E, *et al.*; Infection-induced colitis in mice causes dynamic and tissue-specific changes in stress response and DNA damage leading to colon cancer. *Proc Natl Acad Sci U S A* 2012; 109(27): E1820-1829.
  16. Pawar P, Gilda S, Sharma S, Jagtap S, Paradkar A, Mahadik K, *et al.*; Rectal gel application of *Withania somnifera* root extract expounds anti-inflammatory and mucorestorative activity in TNBS-induced Inflammatory Bowel Disease. *BMC Comp Alt Med* 2011; 11: 34–42.
  17. Roberts RA, Smith RA, Safe S, Szabo C, Tjalkens RB, Robertson FM; Toxicological and pathophysiological roles of reactive oxygen and nitrogen species. *Toxicology* 2010; 276: 85–94.
  18. Tanida S, Mizoshita T, Mizushima T, Sasaki M, Shimura T, Kamiya T, *et al.*; Involvement of oxidative stress and mucosal addressin cell adhesion molecule-1 (MAdCAM-1) in inflammatory bowel disease. *J Clin Biochem Nutr* 2011; 48(2) 112–116.
  19. Chichlowski M, Hale LP; Bacterial-mucosal interactions in inflammatory bowel disease-an alliance gone bad. *Am J Physiol Gastrointest Liver Physiol* 2008; 295(6): G1139–G1149.
  20. Kesari V, Das A, Rangan L; Physico-chemical characterization and microbial assay from seed oil of *Pongamia pinnata*, potential biofuel crop. *Biomass and Bioenergy* 2010; 34:108-115.
  21. Gautam MK, Gangwar M, Nath G, Rao CV, Goel RK; In-vitro antibacterial activity on human pathogens and total phenolic, flavonoid contents of *Murraya paniculata* (L.) leaves. *Asian Pac J Trop Biomed* 2012 [In press: [www.apjtb.com/press/2012/B580.pdf](http://www.apjtb.com/press/2012/B580.pdf)].