

## Original Research Article

### Prevalence of Myelinated Retinal Nerve Fibers

Shinji Makino MD, PhD

Department of Ophthalmology, Jichi Medical University, Shimotsuke, Tochigi, Japan

#### \*Corresponding author

Shinji Makino MD, PhD

Email: makichan@jichi.ac.jp

**Abstract:** The objective is to evaluate the prevalence of myelinated retinal nerve fibers. retrospectively analyzed 7,856 patients at our hospital for health screening during the 1-year period. All patients, including 4,421 men and 3,435 women, were analyzed using fundus photographs. The overall prevalence of myelinated retinal nerve fibers was found to be 0.47% (37/7,856). Out of 37 patients with myelinated nerve fibers, 23 were men (23/4,421; 0.52%), and 14 were women (14/3,435; 0.40%). Among the 37 patients, 27 had unilateral and 10 had bilateral. In addition, 28 were located around the vascular arcades, while nine were located at peripapillary region. Among the patients who underwent health screening, the prevalence of myelinated retinal nerve fibers was found to be 0.47%. These results may aid in explaining clinically rare conditions.

**Keywords:** myelinated retinal nerve fibers, health screening.

#### INTRODUCTION

Myelinated retinal nerve fibers are congenital anomalies that appear as grey-white patches with feathery borders at the nerve fiber layer [1]. They may be located on the disc or elsewhere on the retina. In a series of 3,968 consecutive autopsy cases, Straatsma et al. [2] reported that myelinated retinal nerve fibers were present in 0.98% of patients and in 0.54% of eyes examined, with bilateral involvement in 7.7% of patients. Patients with myelinated retinal nerve fibers may be completely asymptomatic or may show significant visual defects, especially those with marked axial myopia and amblyopia in the affected eye [1-4]. In this study, we report the prevalence of myelinated retinal nerve fibers.

#### MATERIALS AND METHODS

We conducted a retrospective survey of patients who visited the Jichi Medical University hospital for health screening from January 2014 through December 2014. A total of 7,856 patients, including 4,421 men and 3,435 women, were analyzed using fundus photographs taken with a non-mydiatric fundus camera.

#### RESULTS

The overall prevalence of myelinated retinal nerve fibers was found to be 0.47% (37/7,856). Out of 37 patients with myelinated retinal nerve fibers, 23 were men (23/4,421; 0.52%), and 14 were women (14/3,435; 0.40%). Myelinated retinal nerve fibers varied in location: they were around the vascular arcade, peripapillary region, and nasal region (Figure 1 left, middle, and right, respectively).

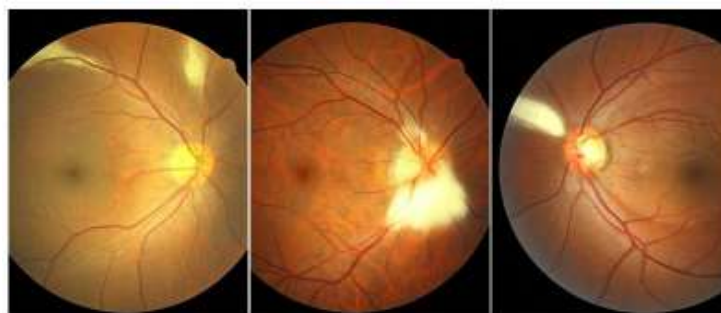


Fig. 1: Various locations of myelinated retinal nerve fibers in this study

Among the 37 patients, 27 had unilateral and 10 had bilateral myelinated retinal nerve fibers (Figure 2 and 3). In addition, 28 were located around the

vascular arcades, while nine were located at peripapillary region.

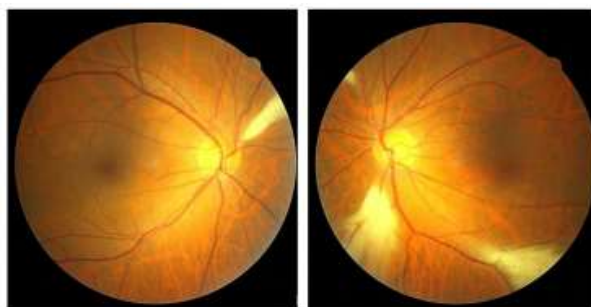


Fig. 2: Bilateral myelinated retinal nerve fibers around the vascular arcades

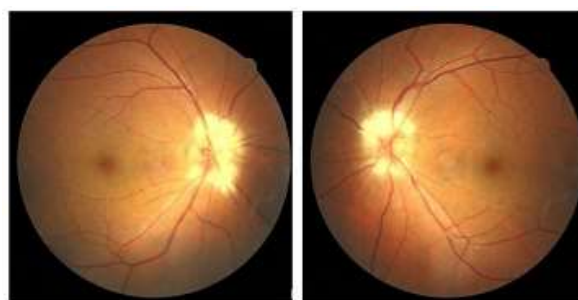


Fig. 3: Bilateral myelinated retinal nerve fibers at peripapillary region

## DISCUSSION

In health screening, various fundoscopic abnormal findings, such as prepapillary vascular loop, Bergmeister papilla, and persistent hyperplastic primary vitreous and myelinated retinal nerve fibers are often experienced. We previously reported the prevalence of prepapillary vascular loop, Bergmeister papilla, and persistent hyperplastic primary vitreous was 0.115% [5], 0.802% [6], and 0.064% [7], respectively. To the best of our knowledge, there are no reports on the prevalence of myelinated retinal nerve fibers in patients who underwent health screening. In present study, the overall prevalence of myelinated retinal nerve fibers was relatively frequent condition among above congenital anomalies.

## CONCLUSION

Although our findings were based on a single fundus photograph of the posterior pole, these results may aid in explaining clinically rare conditions.

## Disclosure

The author declares that he has no conflicts of interest.

## REFERENCES

1. Tarabishy AB, Alexandrou TJ, Traboulsi EI; Syndrome of myelinated retinal nerve fibers, myopia, and amblyopia: a review. *Surv Ophthalmol.*, 2007; 52(6): 588-596.
2. Straatsma BR, Foos RY, Heckenlively JR, Taylor GN; Myelinated retinal nerve fibers. *Am J Ophthalmol.*, 1981; 91(1):25-38.
3. Straatsma BR, Heckenlively JR, Foos RY, Shahinian JK; Myelinated retinal nerve fibers associated with ipsilateral myopia, amblyopia, and strabismus. *Am J Ophthalmol.*, 1979; 88 (3): 506-510.
4. Hittner HM, Antoszyk JH; Unilateral peripapillary myelinated nerve fibers with myopia and/or amblyopia. *Arch Ophthalmol.*, 1987; 105(7): 943-948.
5. Makino S; Prevalence of prepapillary vascular loop. *Sch J Appl Med Sci.*, 2015; 3(2C): 693-694.
6. Makino S; Prevalence of Bergmeister papilla. *Sch J Appl Med Sci.*, 2015; 3(2C): 682-683.
7. Makino S; Prevalence of persistent hyperplastic primary vitreous. *Sch J Appl Med Sci.*, 2015; 3(2E): 906-907.