

Original Research Article

Management of Pemphigus Vulgaris by Dexamethasone cyclophosphamide pulse therapy: a SAIMS Experience

Kailash Bhatia, Satguru Dayal, Rajesh Kataria, Rajeshwari Naik, Hitesh Lokwani

Department of Skin and VD, Sri Aurobindo Medical College and Post Graduate Institute, Indore, Madhya Pradesh, India

***Corresponding author**

Kailash Bhatia

Email: drbhatiakailash@yahoo.co.in

Abstract: The standard treatment of pemphigus comprises of systemic steroids and other immunosuppressive agents. Dexamethasone–cyclophosphamide pulse (DCP) therapy has shown promising results in the management of these diseases. The objective of the study was to assess the outcome of DCP therapy in pemphigus. Forty three patients of pemphigus vulgaris diagnosed by Tzanck smear and skin biopsy were included in the study. DCP pulse therapy was given to them according to standard protocol. In Results the mean age of patients was 44.7±14.8 years. Three patients were lost to follow up. In five patients DCP therapy was discontinued due to precipitation of diabetes (2), arthritis (1), and cardiac complications (2). Twenty nine patients completed phase I, of which 26 (23 in phase II, 2 in phase III and 1 in phase IV) were maintaining remission and three patients relapsed. Six patients are still in phase I. The commonest side effects observed was increased susceptibility to infections, both bacterial and candidial in 15 patients. However the infections responded to conventional antibacterial and antifungal treatment. In Conclusion all our patients have shown remarkable response to DCP therapy irrespective of their disease activity and severity. The side effects profile was comparable with those from previous studies.

Keywords: Dexamethasone, cyclophosphamide pulse, pemphigus vulgaris

INTRODUCTION

A pemphigus vulgaris (PV) disorder is a life-threatening autoimmune scratching skin disease. It has a global division with an occurrence of about 0.1-0.42 per 100.00 per year. Mortality is high due to lack of treatment. The prevalence of PV is about equal in men and women. The mean age of onset is fourth to sixth decades. But it may be seen in children and the elderly [1]. It is caused by auto antibodies against desmosomal caderins desmoglein 3 (Dsg3) which is calcium dependent cell adhesion molecule. The measurement of Dsg 3-ELISA has been shown to be a sensitive and specific test for the diagnosis of pemphigus disorders in addition to the traditional indirect immuno fluorescence auto antibodies titre [2-5]. There is strong genetic background to PV and there is also HLA association in pemphigus disorders most patients are of HLA phenotype DR4 or DR6 [6]. In about 50-70% of the cases the disease begins with oral lesion, which may precede the cutaneous lesions by several months. Cutaneous lesions can be localized or generalized and usually present primarily as flaccid vesicles or bullae varying in size from less than 1 cm to several centimeters. Histological examination of pemphigus on hematoxylin and eosin staining reveals intraepithelial clefts or bullae, acantholysis and a dense mononuclear

lymphocytic infiltration. A smear taken from new lesion can also be used to identify acantholytic cells called “Tzanck cells”, which are indicative of pemphigus. However, the identification of Tzanck cells is not diagnostic since these can also be found in herpes simplex, carcinoma and transient acantholytic dermatosis [7].

Pulse therapy appears to be successful in the treatment of PV. High-dose steroid therapy can be tampered with the use of this treatment. Various studies have proven the efficacy of pulse therapy along with reduced side-effects of conventional corticosteroid therapy [8]. To minimize the cumulative steroid affects in pemphigus, there has been a continuous search for alternative therapies concerning treatment of this disease. Pulse therapy, the ‘big shot’, refers to discontinuous intravenous infusion of very high-dose corticosteroid over a short period. Due to lack of available monitoring facility after giving so large dose of steroid, intended to use 5mg of Dexamethasone pulse (DP) intravenously eight hourly for early control of disease [7-8]. In a study conducted among various physicians treating cases of PV, the expert opinion regarding the definition of disease control was the development of no new lesions and healing most of the

previous lesions. This should be followed by a period of maintenance treatment using the minimum drug doses required for disease control in order to minimize their side effects. It is evident that no trial with Dexamethasone and cyclophosphamide (DCP) has been yet done in Central India. Since there is no recorded study in Central India, this study was undertaken to find out the efficacy of parenteral DP compared with oral prednisolone in early management of pemphigus disorders.

MATERIALS AND METHODS

Patients

This is indiscriminate study carried out in 43 patients of Pemphigus admitted at Sri Aurobindo

Institute of Medical Sciences (SAIMS), Indore were enrolled for the study prospectively from May 2012 – Jan 2016. Laboratory evaluation that included hemoglobin, CBC, ESR, Blood sugar, Urine analysis, Kidney and liver function tests, Serum electrolytes, Chest X-ray, ECG, HIV, HBsAg and HCV tests were undertaken before starting treatment and during follow-up. CBC, serum electrolytes and ECG were repeated after the completion of each pulse. Diagnosis of pemphigus was based on clinical features(Figure 1), tzank smear(figure 2) and skin biopsy(Figure 3).Immunofluorescence could not be carried out in all the patients as the cost and affordability was a limiting factor.DCP was started after positive tzank smear and histopathological features of pemphigus.

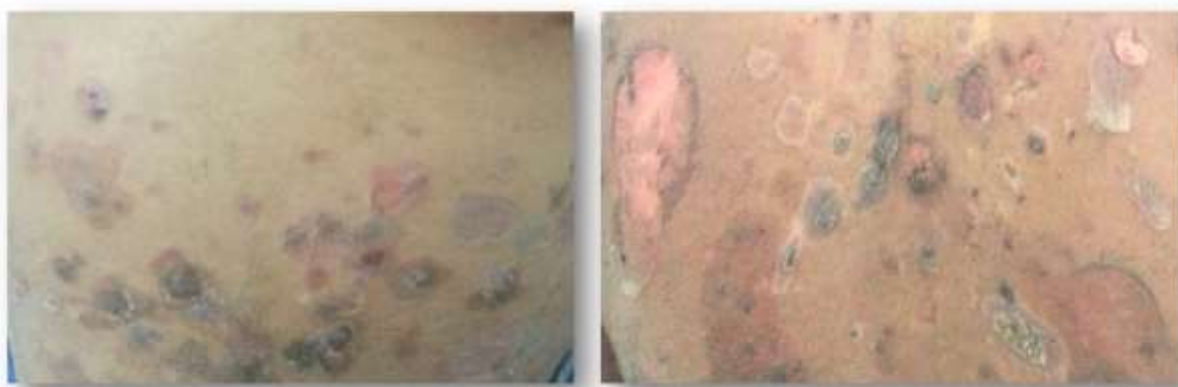

Fig 1: Patients Belly and Back picture showing large superficial ulcers and crust

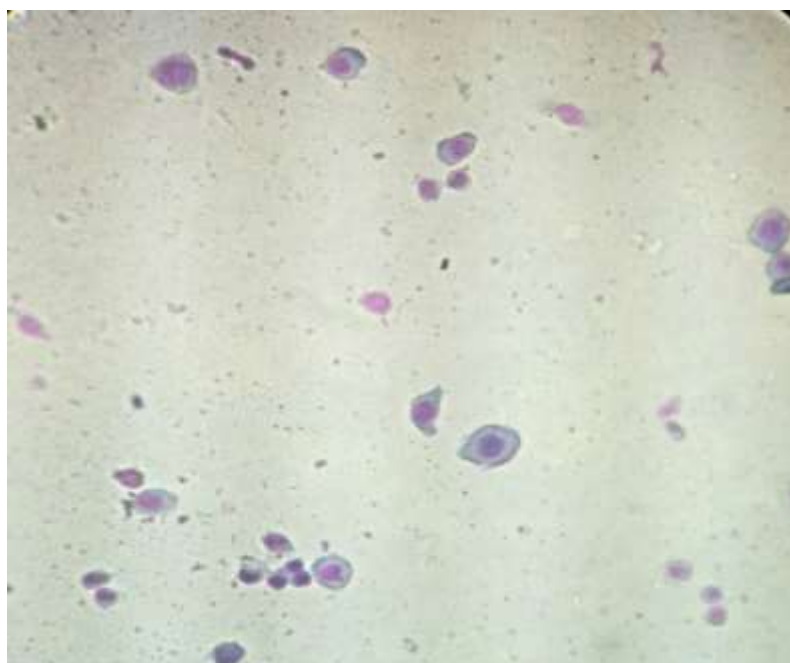


Fig 2: Tzanck smear showing acantholytic cells

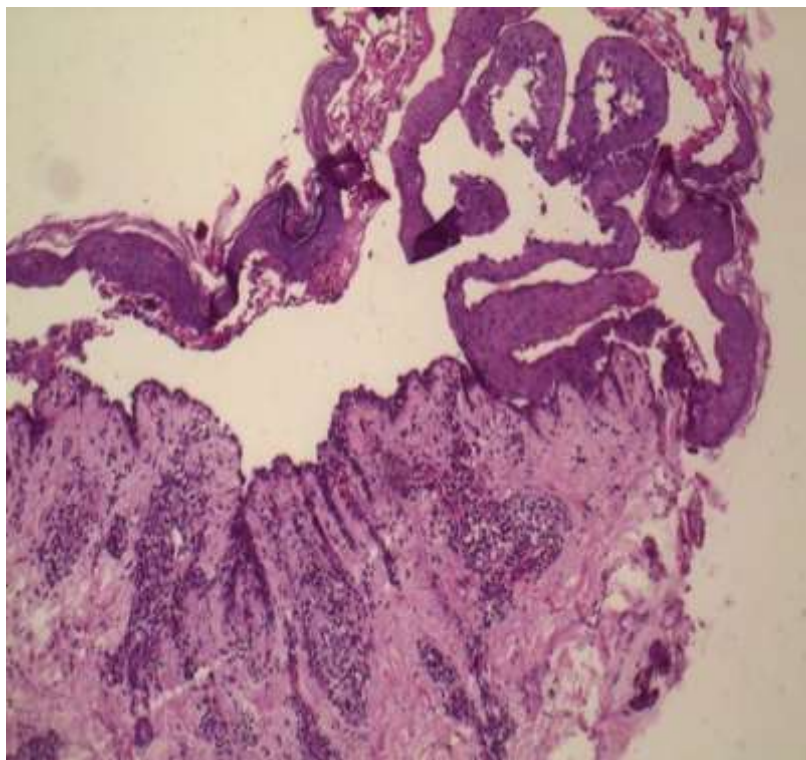


Fig 3: Histopathology Showing several large rounded acantholytic cells

STUDY DESIGN

After obtaining ethical clearance from the institutional ethical committee, the treatment was divided into four phases as per Pasricha *et al.*; [9] schedule-

Phase I: Patients received monthly doses of 100 mg of DP dissolved in 500 mL of 5% dextrose by slow intravenous infusion over 2 – 4 hours on three consecutive days along with 500 mg of cyclophosphamide in the infusion on day 2. In between, the patients received 50 mg of oral cyclophosphamide daily. An additional daily dose of oral prednisolone (40-60mg) sufficient to control the disease activity during phase I was given, which was progressively tapered off completely. Thorough cleaning of the skin and scalp with a normal soap and shampoo, and proper maintenance of oral hygiene was strictly advised. Use of systemic antibiotics if the patient had infected skin lesions and oral anti-candida drugs if the patient had signs of oral candidiasis until complete healing.

Phase II: After the skin and mucosal lesions healed completely and the additional medications were withdrawn, the patient was shifted to phase II. In phase II, DCPs were administered along with 50 mg cyclophosphamide orally per day.

Phase III: DCPs were stopped; only 50 mg of oral cyclophosphamide was given daily for 9 months.

Phase IV: All treatments were stopped, and patients were followed up to look for any tendency to relapse.

RESULTS:

A total of 43 patients (13 male and 30 Female) were enrolled during the study. The age ranged between 25 years to 68 years with a mean of 44.7 ± 14.8 years. Duration of disease before starting treatment varied from a minimum of 1.5 months to maximum of 3 years with a mean of 5.2 months. 17 patients were treated with various modalities before entering the study. All baseline investigations were within normal limits in all patients.

In five patients DCP therapy was discontinued due to precipitation of diabetes (2), arthritis (1), and cardiac complications (2). Three patients were lost to follow up.

At the time of writing this study, 25 patients had completed the phase I and entered in Phase II, 3 and 1 patients were completed the phase II and phase III and entered in phase III and Phase IV respectively. 6 patients were still in phase I.

4 patients (3 males, 1 female) were irregular in receiving pulses due to various reasons. Two patients had relapse during the phase II and one patient relapsed in phase III. Pulse therapy for one patient had to be interrupted temporarily as he developed Herpes simplex keratitis and was started after the viral infection was

controlled. Pulse therapy was completely stopped for 2 patients; one patient (68 yrs male) developed cardiac arrest after his 5th pulse, was resuscitated and was followed on oral cyclophosphamide but was lost to follow up. One female (65 yrs) developed septic arthritis of the hip joint after her 9th pulse. IV antibiotics were started after consultation with the orthopaedic department and both oral and pulse therapy was stopped. Patient is on regular follow up since 5 months with no new skin/mucosal lesions.

DISCUSSION:

The efficacy of DCP regimen in management of pemphigus has been reported time and again, virtually amounting to prediction of "cure" in pemphigus [12-15]. Kanwar *et al.*; [11] assessed the long-term efficacy of DCP therapy. The time taken for completion of phase 1 was 4.2 months on an average (range, 2-8 months), while time for completion of phase 3 was 24 months (20-32 months). The more the pretreatment severity, the more is the number of DCP required for phase 1. Duration of phase 1 in our study was 4.5 months on an average (range 2-10 months). It has been observed that those patients who were regular in their pulses required less number of pulses to go into clinical remission. DCP appears to be more effective in achieving rapid healing of lesions, long-term clinical remission, and fewer incidences of side effects compared with conventional corticosteroid therapy.

All our patients have shown remarkable response to DCP therapy irrespective of their disease activity and severity. The side effects profile was comparable with those from previous studies. DCP therapy was found to be effective in inducing remission in pemphigus, provided the patients receive regular and complete treatment.

Limitations of study was direct Immunofluorescence could not be done for all patients for confirmation of diagnosis. Indirect Immunofluorescence for monitoring of disease activity not done.

REFERENCES

1. Huilgol SC, Black MM; Management of the immuno bullous disorders. II. Pemphigus. Clin Exp Dermatol 1995; 20:283-93.
2. Rao PN, Lakshmi TSS; Pulse therapy and its modifications in pemphigus: A six year study. Indian J Dermatol Venereol Leprol, 2003; 69:329-3.
3. Pasricha JS, Poonam; Current regimen of pulse therapy for pemphigus: Minor modifications, improved results. Indian J Dermatol Venereol Leprol, 2008; 74:217-21.
4. Ramam M, Bhat R; Pulse therapy in other diseases. In: Pasricha JS, editor. Pulse therapy in pemphigus and other diseases. 3rd ed. New Delhi: Mehta publishers; 2006; 91-5.
5. Pasricha JS; Pulse therapy as a cure for autoimmune diseases. Indian J Dermatol Venereol Leprol, 2003; 69:323-8.
6. Sacchidanand S, Hiremath NC, Natraj HV, Revathi TN, Rani TS, Pradeep G *et al.*; Dexamethasone cyclophosphamide pulse therapy for autoimmune vesiculobullous disorders at Victoria hospital, Bangalore. Dermatol Online J, 2003; 9:2.
7. Huilgol SC, Black MM; Management of the immuno bullous disorders. I. Pemphigoid. Clin Exp Dermatol 1995; 20:189-201.
8. Pasricha JS, Khaitan BK, Raman RS, Chandra M; Dexamethasone cyclophosphamide pulse for pemphigus. Int J Dermatol, 1995; 34:875-82.
9. Pasricha JS, Gupta R; Pulse therapy with dexamethasone-cyclophosphamide in pemphigus. Indian J Dermatol Venereol Leprol, 1984;50:199-203
10. Pasricha JS, Khaitan BK, Raman RS, Chandra M; Dexamethasone cyclophosphamide pulse therapy for pemphigus. Int J Dermatol, 1995; 34:875-82.
11. Kanwar AJ, Kaur S, Thami GP; Long- term efficacy of dexamethasone- cyclophosphamide pulse therapy in pemphigus. Dermatology, 2002; 204:228-31.
12. Kandan S, Thappa DM; Outcome of dexamethasone- cyclophosphamide pulse therapy in pemphigus: A case series. Indian J Dermatol Venereol Leprol, 2009; 75:373-8.
13. Masood Q, Hassan I, Majid I, Khan D, Manzooi S, Qayoom S, *et al.*; Dexamethasone cyclophosphamide pulse therapy in pemphigus: Experience in Kashmir valley. Indian J Dermatol Venereol Leprol, 2003; 69:97-9 .
14. Gupta R; Prolonged remission of pemphigus induced by dexamethasone- cyclophosphamide pulse therapy. Indian J Dermatol Venereol Leprol, 2007; 73:121-2.
15. Pasricha JS, Das SS; Curative effect of dexamethasone-cyclophosphamide pulse therapy for the treatment of pemphigus vulgaris. Int J Dermatol, 1992; 31:875-7.