

Original Research Article

Treatment of Paediatric Femoral Shaft Fracture with Titanium Elastic Nails

Dr. Neeraj Mahajan¹, Dr. Arti Khurana²

¹M.S. Orthopaedics, Consultant Orthopaedics, Department Of Orthopaedics, Government Medical College, Bakshi Nagar, Jammu City, Jammu and Kashmir, India

²M.D. Radiodiagnosis, Assistant Professor, Department Of Radio Diagnosis, Government Medical College, Bakshi Nagar, Jammu City, Jammu and Kashmir, India

***Corresponding author**

Neeraj Mahajan

Email: neeraj16mahajandr@gmail.com

Abstract: The operative fixation of pediatric femoral fractures is increasing being done nowadays. Children of age less than six years can be best treated by traction followed by cast method but the conventional traction and casting method for management of pediatric femoral fractures is giving way for the operative stabilization of the fracture in children more than six years. Twenty patients in age group 6-14 years with femoral fractures were treated with titanium nails. The final results were evaluated using the Flynn *et al.*; criteria. In Results were excellent in 14, satisfactory in 5 and poor in 1 patient. The average time for fractures to unite is 9.8 (7-14.5) weeks. The soft tissue impingement near the knee produced by the nails ends was the most common problem encountered. There was knee flexion restriction in 3 patients and shortening was present in 2 patients. There was no case of infection, delayed union or refracture. TENS is an ideal modality of treatment for pediatric femoral fracture fixation because it avoids the chances of pin tract infections, long scars and long term immobilization associated with spica cast.

Keywords: Titanium elastic nailing, paediatric, femur

INTRODUCTION

Most pediatric femoral shaft fractures are treated conservatively, with traction followed by plaster hip spica. The results are usually satisfactory in the long term due to the great potential of remodeling in the pediatric age group. For children between 6-14 years, there are a wide variety of surgical and nonsurgical treatment options available as early spica casting, traction followed by casting, external fixation, plate fixation, reamed intramedullary rods and flexible intramedullary nails with no clear consensus as to the preferred treatment[2]. Children with age more than six years have more chances of malunion and plaster complication. . Operative methods of treatment are needed when there is a failure to obtain and maintain acceptable reduction of the fracture by conservative methods [3, 4]. The objective of treatment is to stabilize the fracture, maintain the length, control the rotational alignment, promote healing, and minimize the morbidity and complications for the child[3,4] An ideal fixation device for pediatric femur fracture would be a load sharing internal splint maintaining reduction for a few weeks until callus forms. Most importantly implant should endanger neither the physis nor the blood supply to femoral head [5]. Titanium implants are increasingly being used for elastic stable intramedullary nailing.

These age group shows good outcome with closed reduction and fixation by Titanium Elastic Intramedullary Nails; as compare to traditional methods like conservative traction followed by cast method, open reduction and plate fixation, external fixator. TENS can be carried out in both closed and open fractures and at all levels between the subtrochanteric and supracondylar areas. This results in rapid recovery and rehabilitation and avoids prolonged immobilization. The present study reported the results of series of paediatric patients who were treated with TENS.

MATERIAL AND METHODS

A retrospective study on 20 paediatric patients treated with TENS for femoral shaft fractures was carried out between 2009 to 2014. The surgical indication was cases with closed or grade I and grade II open fractures. Polytrauma patients were also included in the study. The exclusion criteria were -. children <6 and >14 years of age, femoral metaphyseal fractures, open grade III femoral diaphyseal fractures, underlying neuromuscular disorder, pathologic fractures and metabolic bone disorder. TENS with standard length of 440 mm and diameter ranging from 2.0 mm - 4.0 mm were used. To determine the size of the titanium nails to be used, femoral diaphyseal internal diameter was

measured on both antero-posterior and lateral roentgenograms and was divided by 2 and 0.5 mm was subtracted from that calculation for the eventual nail diameter as determined by Kasser and Beaty[6].

$$\text{Nail size} = [\text{Internal diameter} / 2] - 0.5\text{mm}$$

Fractures were reduced using fluoroscopic guidance. A 1-2 cm longitudinal incision was made over the lateral surface of the distal femur, starting 2 cm proximal to the distal femoral epiphyseal plate. After soft tissue dissection, distal femoral metaphysis was exposed and opened using an awl at a point 2.5 cm proximal to distal femoral physis. The drill was then inclined so that it made an angle of 10 degrees with distal metaphyseal cortex for easy passage of the nail through the dense metaphyseal bone. The nail diameter was determined preoperatively. Two nails of similar diameter in a symmetrical construct alignment, face to face with the maximum curvature of the fracture site, were used. The nails were preventing sufficiently to facilitate placement and also to allow the nail to bounce off the opposite cortex at the time of insertion. This also facilitates the spreading of the nail ends in proximal femoral metaphysis. The nails were put in a double 'C' construct to ensure a three-point fixation, so that early mobilization could be done with toe touching. . When this nail reached the fracture site, the fracture was reduced by manipulation and traction under image intensifier control. Once the fracture site was reduced the nail was pushed into proximal fragment. Then the medial incision was given and the second nail was inserted in a similar retrograde manner. The two nails were then driven into the proximal end of the femur. The tip of the nail that entered from the lateral femoral cortex came to rest just distal to trochanteric apophysis. The opposite nail was made to lie at the same level but pointing towards the calcar region of femoral neck. . Care was taken to see that the nails did not cross the epiphyseal growth plate proximally and that both nails were at the same level proximally. Attention was given to avoid short nails. Distally the nail was cut so that 1 cm of nail remains outside the cortex. The extra osseous

portion of the nail was bent slightly away from the bone for easy removal after fracture union. Too much bending was avoided to prevent the formation of painful bursa over nail ends. . The alignment and anatomic reduction, with proper attention to length and rotation, was confirmed by the image intensifier. Postoperatively patients were placed in supine position with elevation of operated leg on a pillow. Long knee brace was used in distal third fractures, where fixation was not adequate. Patients were mobilized without weight bearing on the fifth to seventh day postoperatively. Partial weight bearing was started at three weeks and full weight bearing by six to eight weeks depending on the fracture configuration and callus formation. The final results were evaluated using the criteria of Flynn *et al.*; [5] [Table 1].

RESULTS

Twenty patients of paediatric femoral fracture in the age group 6-14 treated with TENS was evaluated [Table 2]. There were 12 males and 8 females with mean age 9.4 years. The commonest cause of injury was road traffic accident in 15 (75%) patients. Right-sided involvement was seen in 12 cases (60%) and associated injuries were seen in 4 cases (8%). Seventeen cases were closed fractures, two were grade I and one was grade II compound fracture. Three fractures were in the proximal third, 14 in the middle third and 3 were in the distal third. Thirteen fractures were transverse, 5 short oblique and 2 minimally comminuted. Radiological union was achieved in all cases in a mean time of 9.8 (7-14.5) weeks. Partial weight bearing with crutches was started with an average of 4.2 (4-7.5) weeks. Full weight bearing was possible in a mean time of 9.9 (7.2-15) weeks. The soft tissue impingement near the knee produced by the nails ends was the most common problem encountered. There was knee flexion restriction in 3 patients and shortening was present in 2 patients. There was no case of infection, delayed union or refracture. The results were excellent in 14 patients (70.0%), satisfactory in 5 (25.0%) and poor in 1 patient (5.0%) as per the scoring criteria for TENS by Flynn *et al.*; [1,5] [Table 1].

Table 1: Flynn scoring system for TENS

	Excellent result	Satisfactory result	Poor result
Leg length inequality	<1.0 cm	<2.0 cm	>2.0 cm
Malalignment	5°	10°	>10°
Pain	None	None	Present
Complications	None	Minor and resolved	Major/lasting morbidity

Table 2: Characteristics of Titanium Elastic Nailing for paediatric femoral fractures

S.No	Characteristics	No.
1.	Age (yrs) Range (6-14) Mean age	9.4
2.	Sex Male/Female	12/8
3.	Mode of traum Automobile accidents/Fall from stairs or height/ Sports	15/3/2
4.	Limb side injured: Right/left	12/8
5.	Closed fracture	17
6.	Open fractures I/II	3/2/1
7.	Site of fracture Middle third/Proximal third/Distal third	14/3/3
8.	Fracture pattern Transverse/Short oblique/Minimally communitied	13/5/2
9.	Time taken for weight bearing (wks) mean Partial Full	4.2 9.9
10.	Time for radiological union (wks) Mean	9.8
11.	Complications Knee restriction/ Shortening	3/2
12.	Result grading- Excellent/Satisfactory/Poor	14/5/1

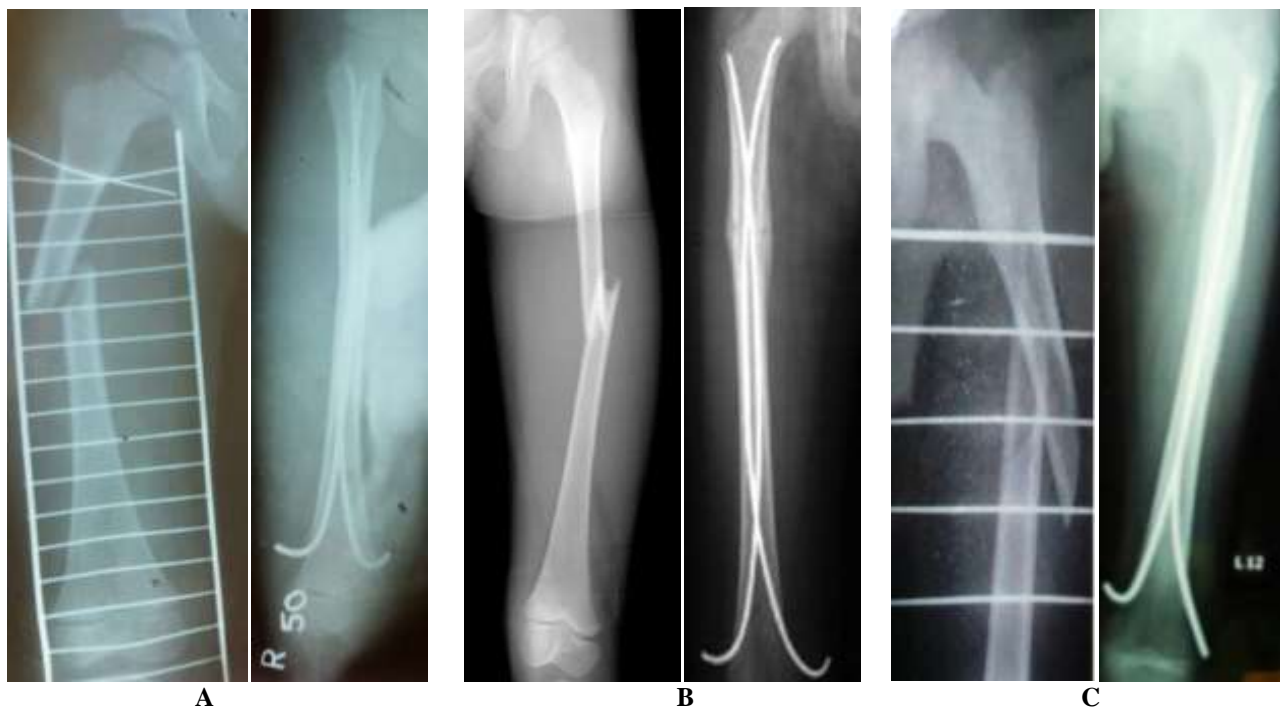


Fig 1: Preoperative and Postoperative X-Rays of Paediatric Femoral Fracture Fixed With Tens

DISCUSSION

Femoral shaft fractures accounts for 2% of all pediatric fractures. Traditionally these fractures have been treated none operatively with either early spica cast or a period of traction followed by application of hip spica cast until the time of fracture union. This is

the standard treatment for the young children but complications such as malunion, joint stiffness and delay in functional recovery are common in older children if managed in this manner [7]. Moreover, conservative treatment results in increased hospital stay and financial losses to the parents attending their

children in the hospital. During the past few decades some form of internal fixation as plate fixation, external fixator, K-wire fixation, rigid intramedullary nailing, Ender nailing, titanium nailing has been advocated but the controversy regarding the ideal implant to treat pediatric femoral fractures still exists[6]. Plate osteosynthesis is associated with a large exposure, relatively longer duration of immobilization and the risks of delayed union, infection and a large dissection for plate removal [8, 9]. The external fixator provides good stability and early mobilization, but is associated with the risk of pin tract infections and it takes a longer time for weight bearing [10, 11]. Intramedullary K-wire fixation has also been used for pediatric femoral fracture but there is disadvantage of stability and fracture angulation. Interlocking nail is ideal for skeletally matured children. Reports of avascular necrosis of femoral head, coxa valga have been reported with interlocking nail when attempted in skeletally immature patients [12, 13]. TENS is the ideal device for the treatment of most femoral fractures in children because it is simple, load sharing internal splint that allows mobilization and maintenance of alignment and extremity length until bridging callus forms. Micro motion conferred by the elasticity of the fixation promotes faster external bridging callus formation. The periosteum is not disturbed and being a closed procedure there is no disturbance of the fracture hematoma, thereby less risk of infection. Flynn *et al.*; found TENS advantageous over hip spica in treatment of femoral shaft fractures in children [14]. Buechsenschuetz *et al.*; documented titanium nail superior in terms of union, scar acceptance and overall patient satisfaction compared to traction and casting [15]. Mazda *et al.*; treated 34 femoral shaft fractures with TENS. They observed that elastic properties of titanium provide a very good stability and it is a safe surgical treatment for immature femoral shaft fractures [16]. Transverse, short oblique and minimally comminuted fractures are suitable for TENS as stated by Flynn *et al.*; [1]. Lascombes *et al.* stated that TENS could be indicated in all femoral diaphyseal fractures of children above six years of age till epiphysis closed except severe Type III open fractures [17]. Titanium elastic nail does not provide adequate stability in comminuted, long oblique or spiral fractures.

Skin irritation due to nail ends was the most common complication encountered in the series. For many years, outward bending of the nail to facilitate retrieval was recommended, but this can cause anything from irritation to skin necrosis and infection and therefore should be avoided [18]. These cases also had restriction of knee motion Insertion points that are too diaphyseal lead to severe muscle irritation. Nails that are left too long in the distal femur, the iliotibial tract can be blocked, thus inhibiting knee flexion [18]. This problem resolved in all our patients once the nails were

removed. No cases of infection were seen in the present series. The operative procedure requires only small incisions and less time. Hence, infection is not a problem with this procedure. Similar results, regarding infection were observed by Herndon *et al.*; [19].

CONCLUSION

TENS technique gives enough stability at the fracture site to allow early ambulation. TENS has considerably decreased the hospitalisation time resulting in early return of the patients to their home. Due to its elastic and flexible quality it allows enough micro motion at fracture site thus allowing early healing. The avoidance of reaming and use of small diameter flexible nails lessen the risk of injury to growth plates. It also allows a biological environment that enhances both the rate of fracture healing and quantity of callus formation. The technique is relatively simple, minimally invasive and healing occurs in an extremely natural way.

REFERENCES

1. Flynn JM, Skaggs DL, Sponseller PD, Ganley TJ, Kay RM, Kellie Leitch KK; The operative management of pediatric fractures of the lower extremity. *J Bone Joint Surg Am.* 2002; 84:2288–300.
2. Clinkscales CM, Peterson HA; Isolated closed diaphyseal fractures of the femur in children: Comparison of effectiveness and cost of several treatment methods. *Orthopaedics.* 1997; 20(12): 1131-6.
3. Anastasopoulos J, Petratos D, Konstantoulakis C, Plakogiannis C, Matsinos G; Flexible intramedullary nailing in paediatric femoral shaft fractures. *Injury* 2010; 41:578-82.
4. Baldwin K, Hsu JE, Wenger DR, Hosalkar HS; Treatment of femur fractures in school-aged children using elastic stable intramedullary nailing: A systematic review. *J Pediatr Orthop B* 2011; 20:303-8.
5. Flynn JM, Hresko T, Reynolds RA, Blasier RD, Davidson R, Kasser J; Titanium elastic nails for Pediatric femur fractures: A multicenter study of early results with analysis of complications. *J Pediatr Orthop.* 2001; 21(1): 4-8.
6. Kasser JR, Beaty JH; Femoral shaft fractures. In: Rockwood and Wilkins Fractures in Children. 5th ed. New York: Lippincott Williams and Wilkins; 2001. 941-80
7. Galpin RD, Willis RB, Sabano N; intramedullary nailing of pediatric femoral fractures. *J Pediatr Orthop.* 1994; 14(2): 184-9.
8. Reeves RB, Ballard RI, Hughes JL; Jackson Internal fixation versus traction and casting of adolescent femoral shaft fractures. *J Pediatr Orthop.* 1990; 10:592–5.

9. Ward WT, Levy J, Kaye A; Compression plating for child and adolescent femur fractures. *J Paediatr Orthop.* 1992; 12:626–32.
10. Aronson J, Torsky EA; External fixation of femur fractures in children. *J Pediatr Orthop.* 1992; 12:157–63.
11. Krettek C, Haas N, Walker J, Tscherne H; Treatment of femoral shaft fractures in children by external fixation. *Injury.* 1991; 22:263–6.
12. Beaty JH, Austin SM, Warner WC, Canale ST, Nichols L; Interlocking intramedullary nailing of femoral-shaft fractures in adolescents: Preliminary results and complications. *J Pediatr Orthop.* 1994; 14:178–83.
13. Letts M, Jarvis J, Lawton L, Davidson D; Complications of rigid intramedullary rodding of femoral shaft fractures in children. *J Trauma.* 2002; 52:504–16.
14. Flynn JM, Luedtke LM, Theodore J, Ganley TJ, Dawson J, Davidson RS, *et al.*; Comparison of titanium elastic nails with traction and a spica cast to treat femoral fractures in children. *J Bone Joint Surg Am.* 2004;86:770–7.
15. Buechsenschuetz KE, Mehlman CT, Shaw KJ, Crawford AH, Immerman EB; Femoral shaft fractures in children: traction and casting versus elastic stable intramedullary nailing. *J Trauma.* 2002; 53:914–21.
16. Mazda K, Khairouni A, Pennecot GF, Bensahel H; Closed flexible intramedullary nailing of femoral shaft fractures in children. *J Pediatr Orthop.* 1997; 6(3): 198-202.
17. Lascombes P, Haumont T, Journeau P; Use and abuse of flexible intramedullary nailing in children and adolescents. *J Pediatr Orthop.* 2006;26:827–34
18. Slongo TF; Complication and failures of the ESIN technique. *Injury.* 2005; 36: S-A78-S-A85.
19. Herndon WA, Mahnken RF, Yngve DA, Sullivan JA; Management of femoral shaft fractures in the adolescent. *J Pediatr Orthop.* 1989; 9(1): 29-32.