

Original Research Article

Study of operative modalities for tibial plateau fractures

Pradip Patil¹, Adarsh Kumbar², Salim Lad³, Ravindra Kachare⁴, P.V Naveenkumar⁵, Ravindra Patil⁶

¹Associate professor, ²Junior Resident, ³Professor and HOD, ⁴Associate professor, ⁵Junior Resident, ⁶Assistant Professor
Dept. of Orthopaedics, D. Y. Patil Medical College, D. Y. Patil University, Kolhapur, Maharashtra - 416 006, India

*Corresponding author

Pradip Patil

Email: rutujapundkar83@gmail.com

Abstract: The management of tibial plateau fractures has remained a controversy with a variety of procedures described in this prospective study conducted at Dept. of Orthopaedics, D. Y. Patil Medical College & Hospital, Kolhapur from May 2014 to November 2015. We studied 15 cases of tibial condylar fractures. They were classified according to Schatzker system and underwent management by LCP, reconstruction plates, Buttress plate or screws. The results with each operative modality were compared. We have found the locking compression plating to be superior to others.

Keywords: tibial condyle Fracture, Complication, CC screws, buttress plate, LCP

INTRODUCTION:

Tibial plateau fractures show a wide variety of fracture patterns. The classic mechanism of injury is either a Valgus ('bumper fracture') or a varus force in combination with axial compression (fall from height). Due to special anatomic configuration of knee (Valgus position, weaker trabecular pattern of lateral condyle, & shape of respective femoral condyle) 55 to 72% of tibial plateau fracture are located laterally [1]. Depending upon the flexion of knee & position of femur condyle, the fracture of tibial plateau will be frontal, central, and dorsal. Split depression fractures are common in patients in their fifth decade & pure split fractures occur in young patients with dense cancellous bone [2]. Fractures of medial tibial plateau occur in 5 to 14%. Bicondylar fractures are seen in 15 to 38% soft tissue injury occurs in 40 to 70% cases. Despite many advances in the care of intra-articular fractures, tibial plateau fractures continue to be a difficult surgical problem [3]. A survey of the literature indicates that many authors report only slightly better than 50% satisfactory results with either closed or operative methods of treatment. The failures of treatment are usually due to residual pain, stiffness, instability, deformity, recurrent effusions, and giving way.

AIM:

To Find a Better Operative Modalities for Tibial Plateau Fractures

METHODOLOGY:

In this prospective study, 50 patients of tibial plateau fractures admitted in our institute were studied.

Inclusion criteria:

1. Tibial condylar fractures, displaced or undisplaced.
2. Unicondylar & bicondylar fractures of tibia.
3. Condylar fractures with extension to shaft.

These all fractures were classified according to SCHATZKER classification. A useful classification not only identifies the fracture pattern but serves as a definite guide to treatment and prognosis. Several attempts have been made easy to classify these fractures. The problem in classifying is that they are often comminuted and complex.

Schatzker Classification: [4]

The Schatzker classification system divides tibial plateau fractures into six types:

Type I : Lateral tibial plateau fracture without depression,

Type II : Lateral tibial plateau fracture with depression,

Type III: Compression fracture of the lateral (IIIA) or central (IIIB) tibial plateau,

Type IV: Medial tibial plateau fracture,

Type V : Bicondylar tibial plateau fracture,

Type VI: Tibial plateau fracture with diaphyseal discontinuity.

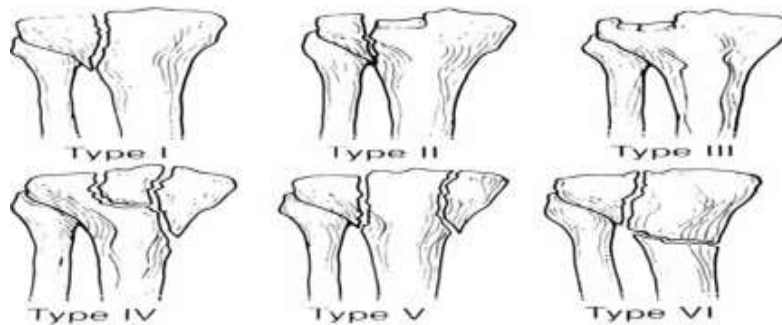


Fig. 1: Schatzker Classification

Treatment methods used for fracture of tibial plateau in our study were -

1. Extensile exposure with arthrotomy & reconstruction of the joint surface with plate & screw fixation.
2. Arthrotomy /limited arthrotomy & percutaneous screw fixation.
3. Newer plating techniques are done with less tissue stripping than older techniques & usually use smaller incision. If more than one incision is used, a large soft tissue bridge is left in between them.
4. Extensive surgery on a severely comminuted fracture may result less than optimal internal fixation & a need for postoperative immobilizations.

SCORING SYSTEM USED FOR ANALYSIS WAS RASMUSSEN'S SYSTEM [5]

Table 1: Clinical and Radiological assessment

	Clinical assessment		Radiological assessment	
	Points	n	Points	n
Excellent	18-20	9	15-16	8
Good	16-17	9	13-14	10
Fair	13-15	1	10-12	1
Poor	< 13	1	< 10	1

Table 2 Clinical assessment

Subjective Points	
Pain None	5
Occasional pain	4
Pain after strenuous activity	3
Pain after mild activity	2
Constant pain	1
Walking capacity :	
Normal	5
Outdoor walking > 1 h	4
Outdoor walking < 1 h	3
Walking with aid	2
Wheelchair/bedridden	1
Objective	
Total range of motion :	
Full	5
> 120°	4
90 °-120°	3
< 90°	2
< 60°	1
Stability :	
Normal	5
Unstable at 20°-30° flexion	3
Unstable with knee extension	1
Maximum	20
Excellent	18-20
Good	16-17
Fair	13-15
Poor	< 1

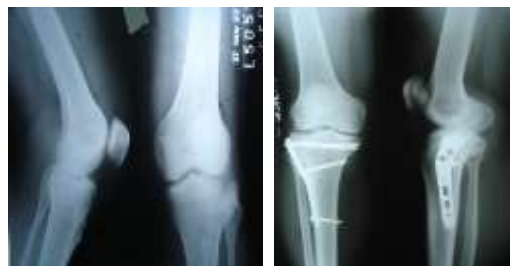Table 3: Radiological assessment

	Points
Articular depression :	
None	4
< 2 mm	3
3-4 mm	2
> 4 mm	1
Varus/valgus:	
None	4
< 5	3
6°-10°	2
> 10°	1
Condylar widening:	
None	4
< 5 mm	3
6-10 mm	2
> 10 mm	1
Osteoarthrosis :	
No progression	4
Mild progression	2
Evident progression	0
Maximum	16
Excellent	15-16
Good	13-14
Fair	10-12
Poor	< 10

RESULTS:

These are the preoperative and postoperative photographs of a patient treated with LCP in a

Schatzker type 2 fracture showing full range of movements.

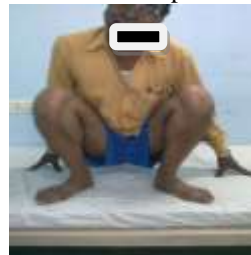

Preoperative

Postoperative



Sitting cross leg



Squatting position

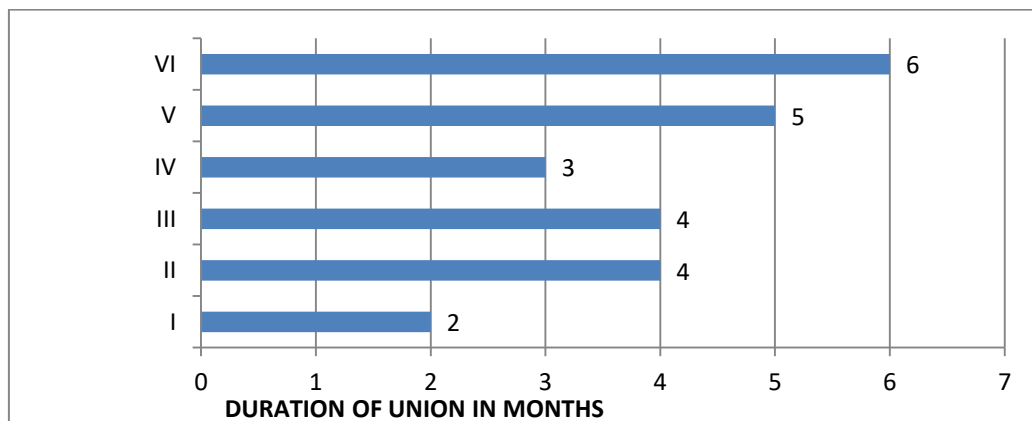


Fig. 1: Duration of union in months

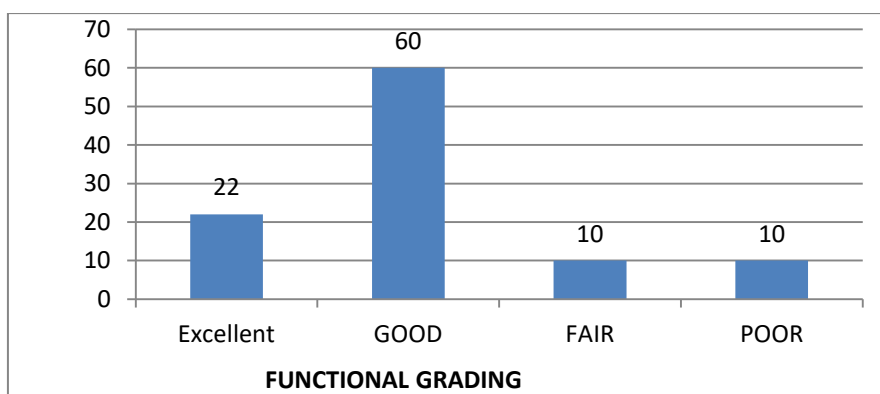


Fig. 2: Functional grading

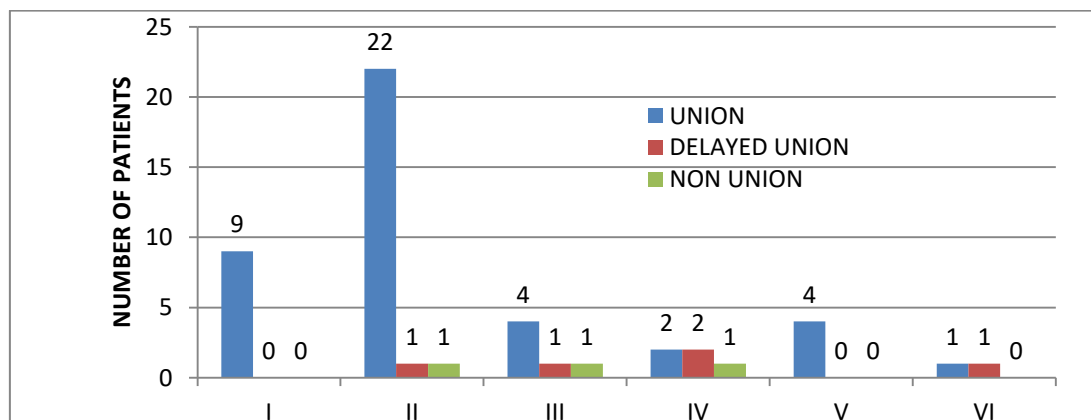


Fig. 3: pattern of union in various types of fractures after operative procedure.

DISCUSSION:

For many years, treating proximal tibial fractures has been the subject of much controversy regarding both the indications for surgical intervention and the specific type of intervention to be employed. These fractures often affect patients during the most productive years of their lives, with potentially devastating consequences. Especially in intra-articular fractures, inadequate treatment may result in joint instability and deformity coupled with a restricted range of motion. Open reduction and rigid internal fixation, according to the principles of Association for

Osteosynthesis/Association for the Study of Internal Fixation (AO/ASIF), has been the treatment of choice for decades. This treatment modality has yielded satisfactory short- and long-term results in many series. In these cases, excessive dissection through the injured soft-tissue envelope and devitalisation of bone fragments are known factors contributing to the development of such complications. Additionally, conventional-plate osteosynthesis requires compression of the plate to the bone and relies on friction at the bone-plate interface. This is inevitably associated with biological pitfalls associated with compression of

periosteal blood supply and compromise of the vascularity of the fracture. As a result, complications such as infection, hardware failure, delayed union and non-union are more likely to occur. Recently, locking plates, or internal fixator, have been designed to allow for less plate to bone contact without compromising stability. The screw holes are modified to allow the screw to “lock” into the plate, thus converting a plate/screw construction into a fixed-angle device with multiple points of fixation. This design allows for minimal vascular damage to the periosteum. In addition, CT scan evaluation provides a more definitive assessment of non union/malunion, but our protocol, based on clinical history and standard radiographs, is practical for the typical clinical situation, with CT scans being reserved for specific cases [6, 7, 8].

CONCLUSION:

In the surgical treatment of tibial plateau fractures in elderly patients, the basic principles are the same as for young patients. Anatomic reduction, secure fixation, and early range of motion are the necessary requirements to achieve satisfactory radiological and clinical results. In this study, we found open reduction with internal fixation to be a reasonable treatment option for these fractures. In addition, a conservative rehabilitation program may be more suitable for elderly patients to avoid further joint depression, decrease the incidence of arthritis, and preserve a satisfactory range of motion.

Locking plates can be particularly effective in treating osteoporotic bones. The evolution of locking-plate technology has led to newly designed, anatomically preshaped plates for different fractures, such as proximal humerus, proximal and distal femur and proximal and distal tibia. These plates are also designed to enhance the surgeon’s ability to pass the plate in a sub muscular or subcutaneous manner for minimally invasive application. Obtaining and maintaining reduction of the articular surface is both surgeon and implant dependent. Malunion of the articular surface as judged on radiographic examination was significantly less in the locked plating group compared to the external fixator group (7% vs 40%, respectively). This decreased incidence of articular malalignment is supported by Cole *et al.*; who cite a 2.6% rate.

CT and MR imaging are more accurate than plain radiography for characterization and classification of tibial plateau fractures, and results of CT and MR imaging can be important for surgical planning. Currently, the clinical significance of preoperative diagnosis of meniscal and ligamentous injury is unknown; therefore, the choice of CT or MR imaging depends on what additional information the clinician needs.

Arthroscopically assisted percutaneous fixation, which was first recommended by Caspari and Jennings, has gradually become popular since its initial use as a diagnostic tool. The advantages of AAPO include the direct vision of the intra-articular fracture, a more accurate reduction, lower morbidity compared with ORIF, better assessment and immediate treatment of intra-articular soft tissue lesions, prevention of soft-tissue complications and the possibility of washing out the joint content, including chondral debris and hematoma. Fowble and colleagues[1] reported that the results of the arthroscopic treatment were superior to ORIF. They pointed out that there was a higher percentage of anatomic reduction, lower rates of complication and a shorter delay to full weight-bearing among patients who underwent AAPO than among those who had ORIF.

ACKNOWLEDGEMENTS

We express deep sense of gratitude and thanks to all our colleagues in the Dept. of Orthopaedics for encouraging and helping us throughout this study.

REFERENCES

1. Campbell’s operative orthopaedics, Vol 3, eleventh edition.
2. Rockwood and Green of adult fractures, Sixth edition.
3. Wang C, Li Y, Huang L, Wang M; Comparison of two-staged ORIF and limited internal fixation with external fixator for closed tibial plafond fractures. Arch Orthop Trauma Surg, 2010 ;(130):1289-97.
4. Markhardt B, Gross J, Monu J; Schatzker Classification of Tibial Plateau Fractures: Use of CT and MR Imaging Improves Assessment1. Radiographics. 2009; 29 (2): 585-597.
5. Jens Rasmussen, Kim J Vicente; Coping with human errors through system design: implications for ecological interface design; J. Man-Machine Studies (1989) 31, 517-534.
6. Heikkila J.T, Kukkonen J, Aho A.J, Moisander S, Kyyronen T, Mattila K; Bioactive glass granules: a suitable bone substitute material in the operative treatment of depressed lateral tibial plateau fractures: a prospective, randomized 1 year follow-up study.J Mater Sci Mater Med, 2011;(22):1073-80.
7. Boldin C., Fankhauser F., Hofer H.P, Szyzskowitz R; Three-year results of proximal tibia fractures treated with the LISS. Clin Orthop Relat Res 2006; 445:222-229.
8. Bozkurt M, Turanlı S, Doral M.N, Karaca S, Doğan M, Şeşen H, *et al.*; The impact of proximal fibula fractures in the prognosis of tibial plateau fractures, 2005; 13(4): 323-328.