

Case Report

## **Ophthalmomyiasis externa caused by *Oestrus ovis*: a case report from Puducherry**

**Jayavarthinni M<sup>1\*</sup>, Malini A<sup>2</sup>, Ezhilvathani N<sup>3</sup>, Amudha P<sup>4</sup>**

<sup>1</sup>Assistant Professor, Department of Microbiology, <sup>2</sup>Associate Professor, Department of Microbiology, <sup>3</sup>Associate Professor, Department of Ophthalmology, <sup>4</sup>Assistant Professor, Department of Ophthalmology, Indira Gandhi Medical College & Research Institute, Kathirkamam, Puducherry-605009

**\*Corresponding author**

Dr. Jayavarthinni M

Email: [jayavarthinni@yahoo.co.in](mailto:jayavarthinni@yahoo.co.in)

---

**Abstract:** *Oestrus ovis* ophthalmomyiasis is an uncommon entity and the diagnosis may often be missed. A 62-year-old farmer from Puducherry, presented with severe symptoms of conjunctivitis. The larvae were observed in the bulbar conjunctiva, and following removal, the symptoms improved within a few hours. Very few cases are documented from Puducherry. This case report will throw light on the aspect of considering myiasis as a possibility of conjunctivitis.

**Keywords:** *Oestrus ovis*, ophthalmomyiasis, conjunctivitis, Puducherry.

---

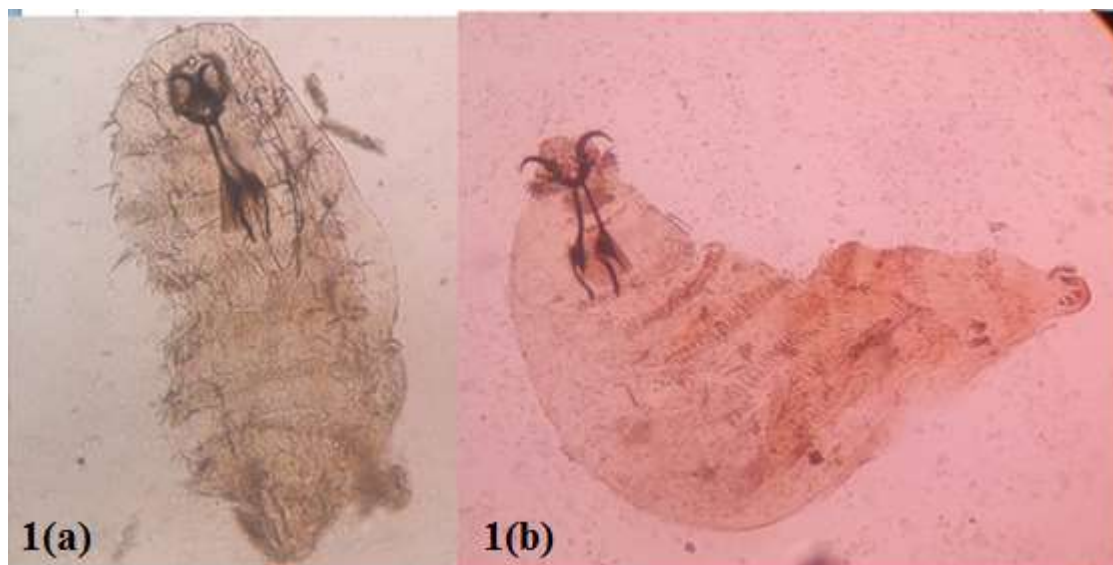
**INTRODUCTION:**

Myiasis is considered as an ignominious disease to patients and to health care professionals. It is defined as infestation of live human or other vertebrate host with fly larvae belonging to the insects of order Diptera [1]. All the species of flies belonging to the families: Muscidae, Fanniidae, Oestridae, Calliphoridae, and Sarcophagidae are frequently responsible for specific and facultative myiasis both in animals and humans [2]. Poor hygiene, low socioeconomic status and unhealthy tissue (necrotic/gangrenous) are the most important risk factors for acquiring myiasis [1]. Ophthalmomyiasis or oculo myiasis is the infestation of any anatomic structure of the eye. *Oestrus ovis* is the main agent causing external ocular myiasis [2]. Here we report a case of external ophthalmomyiasis caused by *Oestrus ovis* in Puducherry. This case shows that one can consider myiasis as a cause of conjunctivitis.

**CASE REPORT:**

A 62-year-old man, presented with complaints of foreign body sensation, burning, excessive watering and a crawling sensation over his right eye since three days, to the ophthalmology out-patient department. He was apparently normal earlier. On examination, his left

eye was normal. Visual acuity was 20/20 and the extra ocular movements were full, in both eyes. Slit lamp examination of the affected eye revealed lid edema, congested bulbar conjunctiva. There was ropy discharge from the bulbar and palpebral conjunctiva. Cornea was clear, anterior chamber was quiet and the pupil was briskly reacting to light. On eversion of the upper lid, multiple petechial haemorrhages were seen in the tarsal conjunctiva and three tiny translucent larvae, 1-2 mm in size with dark heads, were swarming in the fornices which were quickly moving away deeper into the fornices when bright light of slit lamp was thrown. The larvae were removed using Mcpherson's forceps and mounted on a glass slide, after the application of topical anaesthesia and sent to department of microbiology for identification. Wet mount microscopic examination of the larvae revealed the characteristic features of *Oestrus ovis*, with sharp, curved, dark brown oral hooks at the anterior end, segmented body with tufts of numerous hooks and spinose tips (Fig. 1a&b). Topical antibiotic solution (ciprofloxacin), along with anti-inflammatory drops was prescribed. The patient was found to have relief of all the symptoms when reviewed on the next day. Follow up examination for further two weeks was done and no complication was noted.



**Fig 1a&b: Larvae of *Oestrus ovis*, with sharp, curved, dark brown oral hooks at the anterior end, segmented body with tufts of numerous hooks and spinose tips**

#### DISCUSSION:

Oestrosis is a regional myiasis caused by larvae of the fly *Oestrus ovis* which belongs to class Insecta, order Diptera and family Oestridae. Ophthalmomyiasis caused by *O. ovis* is broadly classified into three types. External type is benign and includes the presence of the larvae in the conjunctiva/sclera/ eyelids or the lacrimal duct. Whereas, internal and orbital types are destructive and they are classified based upon the presence of the larva either in the ocular eyeball or in the orbital cavity respectively [3]. *Oestrus ovis*, being the most common cause of external ophthalmomyiasis, inhabits the nasal cavities of goats and sheep. The peculiar feature of the *O. ovis* female is that it may larviposit while still in flight. The larviparous females, deposit a number of first-instar larvae over the nostrils of sheep and goats. The larvae then migrate to the nasal mucosa and nasal and frontal sinuses where they undergo 2 moults. The fully grown third instar larvae, after a period of 2 to 12 months are expelled and pupate on the ground [4]. Man is an accidental host. Persons living in contact with the animals have a higher risk of developing the disease [5]. Also flies in general have a greater abundance in tropical countries, where the climate favours faster life cycles and a higher number of generations per year [2]. Our patient was farmer by occupation and had been rearing sheep in his house, which has attributed to the disease. People with external ophthalmomyiasis will present with similar complaints of any other conjunctivitis. Itching, foreign body sensation, lacrimation, pain, swelling, chemosis and redness will be present in most of the cases while rhinorrhea will be present in few cases due to allergic reaction induced by the larva [5,6,7]. Acute mucopurulent form of conjunctivitis occurs in patients with secondary bacterial infection. However keratitis can also occur [8].

In our case the patient presented with symptoms of acute conjunctivitis, without any evidence of secondary bacterial infection and keratitis. *Oestrus ovis*, has also been reported to cause nasal myiasis [9]. The armed fly larvae with oral hooks, inter-segmental and caudal spines and a multi-layered spiny thoracic complex, may cause direct mechanical damage and lead to haemorrhage, ulceration or even potential invasion, especially in neglected cases [10]. Our patient was free of all the complications due to early presentation and small number of larvae. Recommended treatment is removal of the larva under local anaesthesia [8]. However, administration of topical antibiotics, as and when needed is indicated to prevent the secondary bacterial infection and complications.

#### CONCLUSION:

Appropriate diagnosis with proper history taking, thorough examination and early intervention will reduce the morbidity and complications associated with myiasis.

#### REFERENCES:

1. Ramana KV; Human Myiasis. J Medical Microbiol Diagnosis 2012; 1:e105.
2. Francesconi F, Lupi O; Myiasis. Clin Microbiol Rev. 2012; 25(1):79–105.
3. Gregory AR, Scott S, Harold L; Ophthalmomyiasis caused by the sheep bot fly *Oestrus ovis* in northern Iraq. Optom Vis Sci. 2004; 81:586-90.
4. Gunalan S, Kamaliah G, Wan S, Rozita A.R, Rugayah M, Osman M.A, et al.; Vet. Res. 2011; 2:41-49.
5. Choudhary P, Rathore MK, Dwivedi P, Lakhtakia S, Chalisgaonkar C, Dwivedi A; Red eye: Rule out Ophthalmomyiasis too. Indian J Ophthalmol 2013; 61:293-5.

6. Sucilathangam G, Meenakshisundaram A, Hariramasubramanian S, Anandhi D, Palaniappan N, Anna T; External Ophthalmomyiasis which was Caused by Sheep Botfly (*Oestrus ovis*) Larva. J Clin Diagn Res. 2013; 7(3): 539–542.
7. Masoodi M, Hosseini K; External ophthalmomyiasis caused by sheep botfly (*Oestrus ovis*) larva: a report of 8 cases. Arch Iranian Med 2004; 7:136-9.
8. Sreejith RS, Reddy AK, Ganeshpuri SS, Garg P; *Oestrus ovis* ophthalmomyiasis with keratitis. Indian J Med Microbiol 2010; 28:399-402.
9. Duraipandi K, Gupta N, Karunakaran A, Kale P, Dhaka S, Verma N, Mirdha BR; Naso-Ophthalmic Myiasis and Pubic Louse Infestation of Nose. JCR 2016; 6:1-3.
10. White GB; Myiasis, In: Manson's Tropical Diseases, Cook GC, Zumla A, Eds. WB Saunders Publishers, London, UK, Chapter 88, 22nd ed, 1996; 1526-32.