

Original Research Article

Video Assisted Thoracoscopy in Undiagnosed Pleural Effusion

Dr. Ramaswamy¹, Dr. Sudeena D², Dr.S.B.Lal³

¹Assistant Professor, Department of Pulmonary Medicine, Osmania Medical College, Hyderabad, Telangana, India

²Associate Professor, Department of Pulmonary Medicine, Osmania Medical College, Hyderabad, Telangana, India

³Professor, Department of Pulmonary Medicine, Siddarth Medical College, Vijayawada, Andhra Pradesh, India

*Corresponding author

Dr. Sudeena D

Email: drsudeenaravi@gmail.com

Abstract: Thoracoscopy is a medical procedure involving the internal inspection of pleural cavity. The main diagnostic and therapeutic indications for medical thoracoscopy are pleural effusions and pneumothorax. Due to its high diagnostic accuracy approaching almost 100% in malignant and tuberculous pleural effusions, it should be used when pleural fluid analysis and needle biopsy are non diagnostic. In addition medical thoracoscopy provides staging for lung cancer and diffuse malignant mesothelioma. Talc poudrage as the best conservative method for pleurodesis can also be performed with medical thoracoscopy. It can also be effectively used in the early management of empyema. Medical thoracoscopy is a safe procedure which is even easier to learn than flexible bronchoscopy. Due to its high diagnostic and therapeutic efficiency, it should be applied increasingly in the management of the above mentioned pleuropulmonary diseases.

Keywords: medical thoracoscopy, video assisted thoroscopic surgery [VATS], lung biopsy, pleural space, refractory cough, respiratory failure.

INTRODUCTION

Indications for Thoracoscopy

Medical thoracoscopy [1] is today primarily a diagnostic procedure but it can also be applied for therapeutic purposes. Pleural effusions are by far the leading indication for medical thoracoscopy both for diagnosis mainly in exudates of unknown etiology and for staging in diffuse malignant mesothelioma or lung cancer and for treatment by talc pleurodesis in malignant or other recurrent effusions or in case of empyema. Spontaneous pneumothorax for staging and in stage 1&2 for local treatment is also an excellent indication.

Diagnostic Indications

- Exudative pleural effusion of unknown origin.
- Suspected mesothelioma and staging.
- Undiagnosed fluid collection in lungs.
- Indeterminate lung masses.
- Lung cancer.[5]
- Biopsy of structures surrounding heart, diaphragm, mediastinum and pleura.
- Diseases of lung parenchyma and interstitial lung diseases.
- Biopsy of pericardium.
- video assisted thoracic surgery[2]

Therapeutic Indications

- Treatment of recurrent intractable pleural effusion from any cause (pleurodesis)
- Lysis of pleural adhesions by means of thoraco cautery[8] (jacobsbaeus operations)
- Removal of multiple collections of pus surrounding lungs.
- Pleurectomy [6] thoracoscopic assisted surgery.
- Control of bleeding in chest trauma.
- Resection of benign cancerous peripheral lung masses.
- Ablation of sympathetic trunk.
- Lobectomy or pneumonectomy.
- Excision of benign pleural fibromas.
- Staplings of blebs.
- Volume reduction of pleural emphysema.
- thoracotomy

Contraindications:

Absolute:

- The lack of pleural space.
- Respiratory insufficiency requiring ventilatory support.

- End stage pulmonary fibrosis with honeycomb lung [4] having risk of bronchopleural arterial hypertension.
- Uncorrectable bleeding disorders.

Relative:

- General health of patient.
- Fever.
- Uncontrolled cough.
- Unstable CVS status.
- Hypoxemia (not due to large pleural effusion).
- Refractory cough should be avoided due to high risk of subcutaneous emphysema. :

Thoracoscopy Procedure[3]

Patients are placed in lateral decubitus with healthy lungs. The arm on the side of exploration is positioned above the patient's head in order to widen the intercostal spaces. The entry point will vary according to the indication for the procedure. The trocar [11] is usually introduced mid axillary line always perpendicular to the chest wall. For recurrent pneumothoraces high intercostal space 3rd or 4th will be chosen as entry point. For suspected MPE the trocar is inserted in 6th or 7th intercostal space, as most malignancies tend to involve the lower area of pleural cavity. USG examination of affected hemithorax can provide additional information to select entry point. A single port will be sufficient for most diagnostic thorascopies. When using anaesthesia and conscious sedation a single port technique is preferable to minimize pain. A double port technique [13] is usually reserved for a lysis of adhesions drainage of complex loculated effusions or lung biopsy. Either technique can be employed for talc pleurodesis. An artificial pneumothorax is usually created by blunt dissection before the introduction of trocar, to allow exploration of pleural cavity. Some authors recommended the creation of pneumothorax a few hours and upto a day before the thoracoscopy. This is based on idea that the prolonged collapse of the lung.

Primarily introduced as a diagnostic procedure thoracoscopy [3] was applied between 1915-1955 almost exclusively therapeutically in pneumothorax treatment of tuberculosis. In the early 1960s thoracoscopy was used mainly by pneumologists in Europe on much broader basis for diagnosis of many pleuropulmonary diseases. Medical thoracoscopy, performed by pneumologist in an endoscopy suite, is much less invasive requiring only local anaesthesia or conscious sedation and only one or two points of entry.

The main indication for medical thoracoscopy is in 1998 in the diagnosis and treatment of pleural effusions [12] and pneumothorax. In pleural effusions medical thoracoscopy provides proof or exclusion of malignancies and TB. Medical thoracoscopy has proven

to be successful in management of empyema and of spontaneous pneumothorax. In future, it may become even more popular once more respiratory physicians are trained in using this procedure.

Aim and Objectives:

To know the role of video assisted thoracoscopy in the evaluation of undiagnosed pleural effusions in total no of 16 patients with pleural effusion for the analysis.

MATERIALS AND METHODS:

Total number of 16 patients' (13 male, 3 females), mean age 51years with undiagnosed pleural effusion were admitted to government general and chest hospital between May 2008 to October 2009 were taken in the study.

Study design: Prospective observational study.

Inclusion Criteria:

Undiagnosed pleural effusions (inconclusive after repeated pleural fluid and pleural biopsy analysis).

Exclusion Criteria:

- Bleeding diathesis or anti coagulation
- Occluded pleural cavity
- Refractory cough
- Acute coronary syndrome or uncontrolled cardiac arrhythmias
- Hemodynamic instability
- Respiratory failure
- Unable to obtain informed consent.

Statistical Analysis:

Duration of symptoms: 1=><1 month
2=>>1 month

CXR – 1=> Moderate pleural effusion
2=> Massive pleural effusion
3=> Massive pleural effusion with mediastinal shift
4=> Pleural effusion with growth.

Colour of fluid: 0=> Straw colour
1=> Hemorrhagic

ADA – 1=><40 U/lit
2=>>40U/lit

Thoracoscopy findings: 0=> No pleural growth
1=> Pleural growth presents

[14]

Two patients with sputum AFB +ve and had pleural effusion. The pleural effusion persistent and recurrent even with ATT and hence these patients subjected to thoracoscopy for further evaluation.

Descriptive Values:

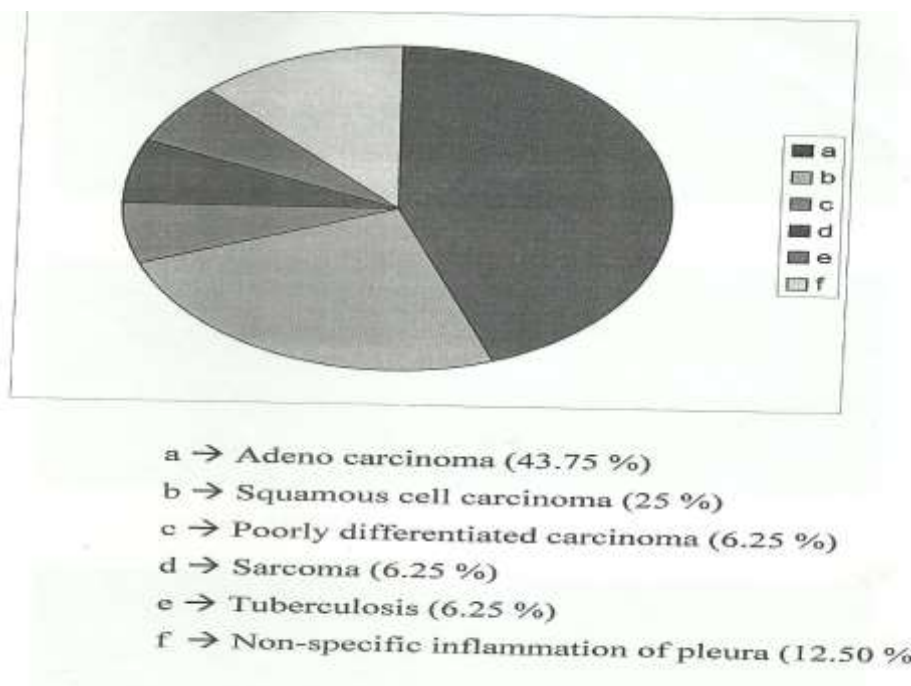
Thoracoscopy was performed on 16 patients from may 2014 to October 2015. Mean age of patients 51 years.

Thoracoscopy guided pleural biopsy[15] was done at multiple sites (4-6 bits) and the samples were subjected to histopathological examination and culture for Mycobacterium tuberculosis. Definitive diagnosis was established in 14 patients.

Table-1: Histopathological examination results

	TOTAL NO.	PREVALENCE (%)
Adenocarcinoma	7	43.75
Squamous cell ca	4	25
Poorly differentiated ca	1	6.25
Sarcoma	1	6.25
TB	1	6.25
Non specific inflammation of pleura	2	12.5

Diagnostic Yield is about 87.5%



DISCUSSION:

The diagnosis of pleural effusion is often challenging. Even after thoracocentesis [9] and closed pleural biopsy 21-27% of patients remain without a definitive diagnosis. Thoracoscopy is highly sensitive and accurate for detecting pleural effusions. The diagnostic yield of thoracoscopy is between 90 and 100% according to literature, in contrast to 44% for closed pleural biopsy and 62% for fluid cytology.

Thoracoscopy came into wide spread use beginning in early 1990's. In India still it is not used commonly due to lack of familiarity with the instrument and experience in usage. In metastatic [10] pleural effusions biopsies of visceral and diaphragmatic pleura are only possible under direct vision because the chest wall is often not involved in early stages.

Not only the pathological confirmation of malignancy or other diagnosis for undiagnosed pleural effusion was possible but also the histological diagnosis was established. Out of 14 diagnosed patients 7 were positive for adenocarcinoma, 4 for Squamous CC, and one showed poorly differentiated ca, 1 had sarcoma, 1 had TB.

Only 2 patients have inconclusive diagnosis. Diagnostic yield is 87.5%. Overall the complications of thoracoscopy appear to be less and it is extremely safe. In the present study no mortality was observed.

CONCLUSION:

- Thoracoscopy [3] is a simple safe and efficient procedure with high positive rate for pleural effusion which is difficult to diagnose.

- Decreased length of hospitalization.
- Minimally invasive and less painful procedure.
- Our study confirmed thoracoscopy useful procedure in diagnosing undiagnosed pleural effusions with high diagnostic yield of 87.5%
- Medical thoracoscopy in an invaluable addition to diagnose armamentarium to pulmonary medicine.

Conflict:

Compliance with ethical requirements and conflict of requirements. Informed written consent was obtained from patient for publication this study was approved by ethical committee of our institute and the authors declare that they have no conflict of interest.

Acknowledgements

The authors thanks to the RNTCP staff of Osmania medical college, department of CT- surgery and department of microbiology for their assistance during the study.

REFERENCES

1. Colt Hg; Thoracoscopy window to pleural space. Chest 1999; 116:1409-2.1415.
2. Ohtsuka T, Ninomiya M, Maemura T, Takamoto S; Needle guided mini entry in video assisted coronary artery bypass. Eur J Cardiothorac Surg. 2003; 24:644-3.
3. Loddenkemper R; Thoracoscopy-state of art. Eur Respir J.1998;11:213-221.3
4. Rao A, Bansal A, Rangraj M, Grant G.R, Papamichael M.J, Nepomuceno A, *et al.*; Video-assisted thoracic surgery (VATS). Heart & Lung: The Journal of Acute and Critical Care, 1999; 28(1): 15-19.
5. LiWW, Lee TW, Lam SS, Ng C.S, Sihoe A.D, Wan I. *Yet al.*; Quality of life following lung cancer resection, video assisted surgery vs thoracotomy Chest 2002;122(2):584-589.
6. McCarthy JF, Hurley JP, Wood AE; The diverse potential of thoracoscopic assisted surgery. International surgery, 1996; 82(1): 29-31.
7. Stoica SC, Walker WS; Video assisted thoracoscopic surgery. PG Med, J.2000; 76:547-550.
8. Hokschi B, Birken-Bertsch H, Muller JM; Thoracoscopy before jacobaeus.ann thorac surg. 2002; 74:1288-1290.
9. Braimbridge MV; The history of thoracoscopic surgery ann thorac surg. 1993; 56:610-614.
10. McCormack PM, Bains MS, Begg CB, Burt ME, Downey RJ, Panicek DM, Ginsberg RJ; Role of video-assisted thoracic surgery in the treatment of pulmonary metastases: results of a prospective trial. The Annals of thoracic surgery, 1996; 62(1):213-217.
11. Migliore M; Efficacy and safety of single-trocar technique for minimally invasive surgery of the chest in the treatment of noncomplex pleural disease. The Journal of thoracic and cardiovascular surgery, 2003; 126(5): 1618-1623.
12. Light RW; Update on tuberculous pleural effusion. Respirology, 2010; 15(3):451-458.
13. Tassi GF, Davies RJ, Noppen M; Advanced techniques in medical thoracoscopy. European Respiratory Journal, 2006; 28(5): 1051-1059.
14. Harris RJ, Kavuru MS, Mehta AC, Medendorp S.V, Wiedemann H.P, Kirby T.J, *et al.*; The impact of thoracoscopy on the management of pleural disease. CHEST Journal, 1995; 107(3): 845-852.
15. Preventza O, Hui HZ, Hramiec J; Fast track video assisted thoracic surgery am surgeon 2002; 68:309-311.