

Case Report

An Unexpected Diagnosis of Systemic Lupus Erythematosus (SLE) Four Weeks after Mitral Valve Replacement: the Need for a Deep Understanding

Haiyong Wang, MD, Donghua Pan, Tianci Qian, MD, Fugui Ruan MD, Xiaolin Sun, MD, Jiangbin Sun, MD*

Department of Cardiovascular Surgery, Affiliated Hospital of Guilin Medical University, Guilin 541001, China

***Corresponding author**

Jiangbin Sun

Email: sunjiangbin1972@sina.com

Abstract: Systemic lupus erythematosus (SLE) is one of the most common autoimmune diseases. Here, we present a special surgical case of mitral stenosis with SLE. Mitral valve replacement was performed, and the postoperative course was uneventful. Pathohistological findings of the mitral valve showed chronic inflammation, proliferative fibrous change. The postoperative course seemed to be uneventful. But on the 27th postoperative day, acute cough and fever occurred. The patient hospitalized again. All clinical findings confirmed the diagnosis of SLE. Due to clinical manifestation of SLE, the patient was referred to rheumatology section and started with glucocorticoids. The patient recovered fully. Regular medication for the SLE was continued after her discharge. To our knowledge, this report is an unexpected diagnosis of SLE four weeks after mitral valve replacement. SLE may be clinically silent in some heart valve disease cases. These results, along with a review of the world literature, suggest the importance of raising awareness of SLE in heart valve disease.

Keywords: Lupus erythematosus, Systemic, Mitral valve stenosis, Surgery

INTRODUCTION

The prevalence of autoimmune diseases has increased in recent years, especially due to the broader and deeper medical knowledge on the subject and the development of specific diagnostic methods. Therefore, such diseases have acquired an extremely relevant importance. Among them, systemic lupus erythematosus (SLE) is known to be a cause of cardiovascular involvement [1]. Furthermore, cardiovascular disease is the main cause of morbidity and mortality in patients with SLE [2]. Herein, we review the world medical literature and report our experience with one patient who was diagnosed of SLE four weeks after mitral valve replacement.

METHODS

Case presentation

A 41-year-old Chinese woman presented to our institution with progressive exertional dyspnea and unexplained tachycardia of one-month duration. She had no special history. Physical examination was unremarkable except for the presence of malar rash. Preoperative hemoglobin, platelet and white blood cell count was normal. Liver and renal parameters were normal. Routine and microscopic evaluation of urine also was normal.

A chest X-ray showed cardiac enlargement. Preoperative transthoracic echocardiography confirmed severe mitral stenosis with thickened mitral valve leaflets associated with a dilated left Atrium (Fig 1). The systolic pulmonary artery pressure was 50 mm Hg.

Patient was scheduled for Mitral valve replacement (MVR) and an informed consent was obtained. In March 2014, an operation was performed with median sternotomy using routine cardiopulmonary bypass (CPB). At surgery, there was no pericarditis and pleurisy. The mitral valve was exposed using the transseptal approach. Intraoperative findings showed no thrombus in the left atrium. A mitral valve analysis revealed that there was thickening and calcification in the mitral leaflets, no enlarged annulus of the tricuspid valve. All the chordae were thickened and shortened. MVR was performed using mechanical valve (ATS Medical 27 mm) with continuous suture technique. The aortic clamping time was 56 minutes, and the CPB time was 92 minutes. Intraoperative transesophageal echocardiography showed that valve replacement had achieved good results. Pathohistological findings of the mitral valve were as follows: degenerative change due

to chronic inflammation, proliferative fibrous change and calcification, and no adhesion of thrombi to the mitral valve (Fig. 2). The postoperative course was

generally good; the patient was discharged on the 11th postoperative day.

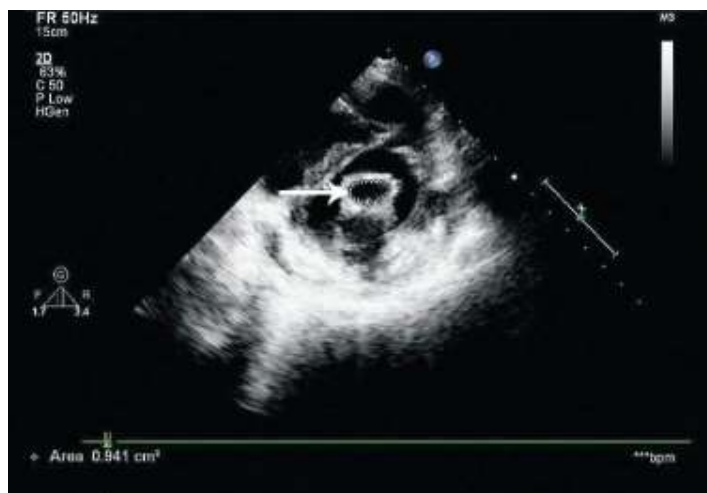

Fig-1: Transthoracic echocardiography confirmed revealed severe mitral stenosis with thickened mitral valve leaflets (ARROW)

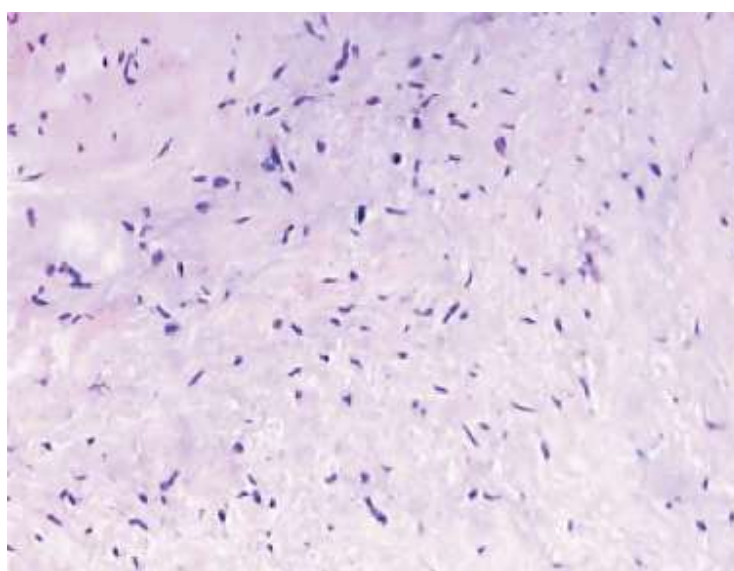


Fig-2: Pathohistological findings of the mitral valve showed degenerative change due to chronic inflammation, proliferative fibrous change

27 days passed, she admitted to the hospital because of cough and high fever. At physical examination, she had tachycardia (heart rate = 130 beats per minute), blood pressure was 120/70 mmHg, presence of rhythmic heart sounds and fine crackling rales in both pulmonary bases. A transthoracic echocardiogram was requested, which ruled out infective endocarditis, and revealed mitral mechanical valve with no structural alterations and slight pericardial effusion. All blood cultures were negative. The electrocardiogram showed sinus rhythm with 130bpm. No abnormal findings were found. The chest X-ray and CT performed for suspected pneumonia showed positive result for lung infection. Because of

acute lung infection the patient was started with broad-spectrum antibiotics.

However, there is no remission of clinical symptoms after one week. Laboratory tests showed $7.8 \times 10^9/L$ platelet count, leukocyte $10.21 \times 10^9/L$ count, erythrocyte sedimentation rate of 36 mm and C-reactive protein of 42.38mg/L. Liver and kidney function damage occurred. The hypothesis of autoimmune disease was considered. Immunological analysis showed the presence of antinuclear and antiphospholipid antibodies. The tests showed ASO of 200 IU / mL, Anti-Nuclear Antibody (ANA) titer (N: <20) >640, positive anti-SM, positive

anticardiolipin IgM (14 IU) and IgG antibodies, Anti-ds-DNA Ab (Farr-assay):120, and positive lupus anticoagulant test.

Due to clinical manifestation of SLE, the patient was referred to rheumatology section and started with glucocorticoids. The patient recovered fully after 20 days and regular medication for the SLE was continued after the discharge.

When last seen in April of 2016, she was in New York Heart Association class I, in sinus rhythm. The follow-up echocardiograms showed preservation of left ventricular function. The left ventricular ejection fraction was estimated at 0.68, and the mean pulmonary pressure was 16 mm Hg. She is currently on anticoagulation and in good general condition.

SEARCH STRATEGY

We systematically reviewed the literature on mitral valve surgery for mitral stenosis caused by SLE. We performed Medline and Google Scholar from 1970 through December 2015 database queries with the following text and keywords: "systemic lupus erythematosus" and "mitral valve". All papers were considered irrespective of their quality or the journal in which they were published. We then used strict criteria. Titles and abstracts were screened and relevant papers were selected.

DISCUSSION

SLE is a multi-systemic autoimmune disorder characterized by a broad range of manifestations. Patients with SLE produce abnormal antibodies in their blood that target different tissues within their own body rather than foreign agents.

The prevalence of SLE ranges from 7.4 to 159.4 per 100,000 of population with the striking 9:1 female/male ratio of disease incidence, and peak age of onset between 15 years and 40 years [3,4]. Our patients were also a woman.

Patients with SLE can have a wide variety of symptoms and organ involvement of multiple systems. 11 criteria were established by the American Rheumatism Association to establish the diagnosis of SLE [5]. When the patient has 4 or more of these criteria, the diagnosis of SLE is strongly suspected. Our patient had malar rash, renal disorder, immunologic abnormal (positive antiphospholipid and antinuclear antibodies).

On the other hand, rheumatic heart disease is also a systemic inflammatory disease that develops as a consequence of an exaggerated immune response to group A beta-haemolytic streptococci. The molecular mimicry appears between human cardiac myosin and M

protein of group A streptococcal membranes, which lead to autoimmune reactions and cardiac tissue damage known as rheumatic heart disease [6]. There is a complex network of inflammatory and immune reactions controlled by several genes that can drive the rheumatic heart lesions. Genetic studies on systemic or organ specific autoimmune diseases revealed an association between a functional single nucleotide polymorphism and some autoimmune diseases including rheumatoid arthritis and SLE [7,8].

SLE can present major challenges because of a broad range of organ damage, coagulation defects and complex management regimes. The clinical and serological heterogeneity makes it a great challenge for diagnosis, especially at the earlier stage, when an inadequate number of features required to meet the diagnostic criteria may be present. It has been shown that the prevalence of valvular disease (diagnosed by echocardiography) in SLE can be 11-70%, depending on the diagnostic technique [9]. Our patient reveals a rare case of unexpected diagnosis of SLE four weeks after mitral valve replacement.

Libman-Sacks (LS) endocarditis was first described in 1924 by Libman and Sacks, as the cardiac manifestation in SLE [10]. Almost all patients with SLE will have involvement of the heart at some stage during their illness. The prevalence of significant valve dysfunction in SLE patients is variable. Nowadays endocarditis is seen as a cardiac manifestation of SLE. It is typically mild and asymptomatic but can lead to severe and sudden presentation such as superimposed bacterial endocarditis, congestive heart failure and thromboembolic events. Echocardiography remains the best imaging modality for early and accurate diagnosis and helps to avoid misdiagnosis (papillary fibroelastoma and infective endocarditis). Our patients could exclude the diagnosis of infective endocarditis.

Preoperative detailed assessment will provide accurate information on disease flares, organ damage. It would be prudent to delay non-urgent surgery until after recovery from SLE. Coronary angiography is mandatory in patients with SLE, irrespective of age, with emphasis not only to overt lesions in the major coronary arteries but also to a possible rarefaction of the end-branches as a sign of recurrent micro emboli [11]. In patients with SLE, preoperative evaluation should particularly address the need for perioperative continuation of immunosuppressants and steroid replacement. In view of increased risk of infection and sepsis, strict aseptic precautions and use of broad-spectrum antibiotics are warranted in the perioperative period. High rate of infection in SLE patients appears related to intrinsic susceptibility and treatment-related immunosuppression, and is an important risk factor for morbidity and mortality in

patients with SLE[12]. Management for renal protection (maintaining urine output, avoiding hypoperfusion and hypotensive states, avoiding nephrotoxic drugs) is advisable even in the absence of overt kidney impairment. Longer acting muscle relaxants such as pancuronium, that depend on renal excretion, should be avoided and atracurium used instead[13].

Previous studies [12] suggested that repair might be a preferable approach due to the elimination of the need for anticoagulation. But, anticoagulation may present higher risks in young patients who require prolonged steroid use and who frequently experience renal failure, and the risks are especially high in patients who are undergoing hemodialysis and require valve replacement. The patient's with SLE might not achieve the best result with valvular repair [14]. Other attempts at mitral valve repair in patients with SLE have not been as successful. Some patient with the rheumatic involvement of the mitral valve and was treated with mitral valve repair by ring annuloplasty and anterior leaflet augmentation with autologous pericardium. Follow-up, however, disclosed precocious calcification of the valve, necessitating mitral valve replacement [15]. So, mitral valve replacement has been reported to be safe by a handful of other authors[16]. So, we believe that applying valvular replacement in our patient would have been associated with better outcome. Even if the SLE patients are decided to repair the valve, it is advisable that autologous pericardium be not used because SLE involves all components of the heart, including the pericardium, heart valves, myocardium, conduction system, and coronary arteries.

A 84 year old woman, who had undergone mitral valvuloplasty and subsequently developed early restenosis, presented with major commissural fusion and verrucous lesions on the cuspid edges of the mitral valve, with normal subvalvar apparatus. She did well for the first six months after surgery when she began to present dyspnea on light exertion. A clinical diagnosis of restenosis was made, which was confirmed by an echocardiogram. She underwent surgery, and a stenotic mitral valve with verrucous lesions suggesting Libman-Sacks' endocarditis was found. Because the diagnosis of SLE had not been confirmed at that time, a bovine pericardium bioprosthesis (FISICS-INCOR) was implanted[17].

When SLE patients need mitral valve surgery, we recommend mechanical valve replacement rather than repair. Antiphospholipid antibodies are frequently present in patients with SLE and valvular heart disease. The use of mechanical valves requires anticoagulation; however, such treatment is essential in most cases. Current therapeutic guidelines for antiphospholipid antibody syndrome include antithrombotic prevention with long-term anticoagulation. Due to embolic events

in SLE patients and the procoagulant effect of the lupus anticoagulant, many patients with lupus are placed on warfarin. Moreover, atrial fibrillation frequently affects patients with severe mitral stenosis, so anticoagulation is not to be avoided in such patients. In our patients, valve replacement surgery achieved good results. Even if the patient repair was successful; however, the patient will likely require lifelong anticoagulation for antiphospholipid syndrome and venous thrombotic episodes. The target INR should be rather high, but no clear cut data support this recommendation. If thrombotic events occur despite "adequate" anticoagulation, the dose of warfarin and target INR can be increased and/or a platelet inhibitor added [18]. The difficulty of anticoagulation in SLE patients is the frequent encountered in end-stage renal disease and the resultant dependence on dialysis. Furthermore, valvuloplasty and bioprosthetic valve replacement are not the best choice in the setting of renal insufficiency, since accelerated native valve and bioprosthetic valve calcification tend to occur due to the high calcium turnover.

The mortality rates remain high in the previously reported cases of mitral valve replacement in patients with SLE. The surgical success of valve replacement in our patients was with no death or reoperation after surgery. The major perioperative challenges in patients with SLE undergoing valve replacement include accrued organ damage, increased risk of infection, and renal impairment. The goals of perioperative management are directed towards maintaining asepsis, avoiding use of nephrotoxic drugs, and promoting early ambulation[19].

CONCLUSIONS

This case highlights the role of SLE for the positive diagnosis of valvular involvement leading to severe mitral stenosis. SLE is a heterogeneous disease in which diagnosis is not always easy. Valvular heart disease in SLE is associated with substantial morbidity and mortality. Current therapy includes symptomatic measures and valve replacement. SLE can present major challenges because of accrued organ damage, coagulation defects and complex management regimes. The perioperative goals are to maintain strict asepsis, avoid renal insult, and to promote early ambulation post-operatively.

CONFLICT OF INTERESTS

None declared.

AUTHOR'S CONTRIBUTION

Haiyong Wang and Jiangbin Sun wrote the paper. Fugui Ruan, Tianci Qian, Donghua Pan and Xiaolin Sun supervised the composition of the paper. All authors read and approved the final paper.

ACKNOWLEDGEMENTS

This work was supported by Health and Family Planning Commission of Guangxi Zhuang Autonomous Region Grant [Z2015397]. We thank Jiangwei Hu and for his contribution to this article.

REFERENCES

1. Hojnik M, George J, Ziporen L, Shoenfeld Y; Heart valve involvement (Libman-Sacks endocarditis) in the antiphospholipid syndrome. *Circulation*, 1996;93(8):1579-87.
2. Bouma W, Klinkenberg TJ, van der Horst IC, Wijdh-den Hamer IJ, Erasmus ME, Bijl M, Suurmeijer AJ, Zijlstra F, Mariani MA; Mitral valve surgery for mitral regurgitation caused by Libman-Sacks endocarditis: a report of four cases and a systematic review of the literature. *J Cardiothorac Surg.*, 2010;5:13.
3. Weckerle CE, Niewold TB; The unexplained female predominance of SLE: clues from genetic and cytokine studies. *Clin Rev Allergy Immunol.*, 2011;40(1):42-9.
4. Danchenko N, Satia JA, Anthony MS; Epidemiology of SLE: A comparison of worldwide disease burden. *Lupus.*, 2006;15(5):308-18.
5. Yu C, Gershwin ME, Chang C; Diagnostic criteria for SLE: a critical review. *J Autoimmun.*, 2014;48-49:10-3.
6. Aksoy R, Duman T, Keskin O, Düzgün N; No association of PTPN22 R620W gene polymorphism with rheumatic heart disease and SLE. *Mol Biol Rep.*, 2011;38(8):5393-6.
7. Bottini N, Vang T, Cucca F, Mustelin T; Role of PTPN22 in Type 1 diabetes and other autoimmune diseases. *Semin Immunol.*, 2006; 18(4):207-213
8. Kyogoku C, Langefeld CD, Ortmann WA, Lee A, Selby S, Carlton VE, Chang M, Ramos P, Baechler EC, Batliwalla FM, Novitzke J, Williams AH, Gillett C, Rodine P, Graham RR, Ardlie KG, Gaffney PM, Moser KL, Petri M, Begovich AB, Gregersen PK, Behrens TW; Genetic association of the R620 W polymorphism of protein tyrosine phosphatase PTPN22 with human SLE. *Am J Hum Genet.*, 2004, 75(3):504-507
9. Akhlaq A, Ali TA, Fatimi SH; Mitral valve replacement in systemic lupus erythematosus associated Libman-Sacks endocarditis. *J Saudi Heart Assoc.*, 2016;28(2):124-6.
10. Libman E, Sacks B; A hitherto undescribed form of valvular and mural endocarditis. *Arch Intern Med.*, 1924;33:701-37.
11. Gorki H1, Malinovski V, Stanbridge RD; The antiphospholipid syndrome and heart valve surgery. *Eur J Cardiothorac Surg.*, 2008;33(2):168-81.
12. Lin CH1 Lee ML, Hsu RB; Cardiac surgery in patients with systemic lupus erythematosus. *Interact Cardiovasc Thorac Surg.*, 2005;4(6):618-21.
13. BenMenachem E; SLE: A review for anesthesiologists. *Anesth Analg.*, 2010;111:665-76.
14. Hakim JP, Mehta A, Jain AC, Murray GF; Mitral valve replacement and repair. Report of 5 patients with systemic lupus erythematosus. *Tex Heart Inst J.*, 2001;28:47-52.
15. Roshanali F, Oraii S, Mandegar H; Outcome of mitral valve repair in a patient with SLE. *BMJ Case Rep.*, 2012;2012.
16. Vassileva CM, Swong MN, Boley TM, Markwell SJ, Hazelrigg SR; Influence of SLE on procedure selection and outcomes of patients undergoing isolated mitral valve surgery. *J Card Surg.*, 2012;27(1):29-33.
17. Pomerantzeff PM, Corrêa JD, Brandão CM, de Assis RV, Jatene AD; Mitral restenosis in the early postoperative period of a patient with SLE. *Arq Bras Cardiol.*, 1999;72(4):483-6.
18. Hakim JP, Mehta A, Jain AC, Murray GF; Mitral valve replacement and repair. Report of 5 patients with SLE. *Tex Heart Inst J.*, 2001;28(1):47-52.
19. Kansara B, Singh A, Karlekar A, Mishra YK; Aortic valve replacement in a patient with SLE. *J Anaesthesiol Clin Pharmacol.*, 2013;29(2):248-51.