

Granulosa Tumour of the Ovary: A Case Report

Dr. Boubakary Guindo^{1*}, Broulaye Diarra¹, Moctar Diaby¹, Ilias Guindo², Aminata Kouma¹¹Obstetrics and Gynecology Department of the University Teaching Hospital "Pr BSS", Kati, Mali²Radiology Department of the University Teaching Hospital "Pr BSS", Kati, MaliDOI: [10.36347/sjams.2022.v10i11.022](https://doi.org/10.36347/sjams.2022.v10i11.022)

| Received: 15.09.2022 | Accepted: 24.10.2022 | Published: 24.11.2022

*Corresponding author: Dr. Boubakary Guindo

Obstetrics and Gynecology Department of the University Teaching Hospital "Pr BSS", Kati, Mali

Abstract

Case Report

Granulosa tumours of the ovary are quite rare. We report an observation and review of the literature on its clinical, therapeutic and prognostic features.

Keywords: Granulosa tumours, prognostic features, para-clinical, Abdomino-pelvic.

Copyright © 2022 The Author(s): This is an open-access article distributed under the terms of the Creative Commons Attribution 4.0 International License (CC BY-NC 4.0) which permits unrestricted use, distribution, and reproduction in any medium for non-commercial use provided the original author and source are credited.

INTRODUCTION

Ovarian granulosa cell tumours are tumours of the mesenchyma and sex cords of the ovary. They are quite rare, but are the most frequent secretory tumours [1-3]. We present an observation of this tumour and highlight its clinical, para-clinical, therapeutic and prognostic features.

OBSERVATION

A progressive increase in abdominal volume, chronic abdomino-pelvic pain, in a 35 year old patient with no known medical, surgical or family history, nulligest, experiencing leucorrhoea and vulvar pruritus. Our examination revealed a patient with a fair general condition, cachexia, conjunctivo-palmo-plantar pallor, with soft, painless, bucketing oedema of the lower limbs.

The cardiac examination revealed a tachycardia of 150 beats per minute with a systolic murmur.

Abdominal examination revealed a shiny, enlarged abdomen with the presence of a hard mass, occupying the pelvis, the left flank and the periumbilical space, a height of the mass of 38 cm and an abdominal perimeter of 95 cm. We observed the sign of the float.

Speculum examination revealed a macroscopically healthy cervix and vaginal wall.

On vaginal touch, the cervix was long, posterior, closed with a sensation of a mobile latero-uterine mass.

Abdomino-pelvic ultrasound revealed a large abdomino-pelvic mass, tissue and fluid, the tissue part of which is necrotic and calcified, and the fluid part is cystic, multipartitioned, responsible for a significant mass effect on the intra-abdominal and pelvic organs and poorly vascularised in places on colour Doppler: Ovarian tumour? Mesenteric tumour?

- Homogeneous hepatosplenomegaly.
- Bilateral kidney injury stage I.
- Gallbladder and pancreas were normal in appearance.
- Pelvic organs were not visualised by the mass (bladder, uterus and ovaries).

On abdominal-pelvic CT-scan, there was an abdominal-pelvic mass with a mixed component (tissue and fluid) with areas of necrosis, calcification, multi-partitioned and slightly lateralized on the right, in contact with the uterus, measuring 315x236 mm in the axial plane, with irregular contours indicative of an ovarian mass, suggesting a suspicion of ovarian cystadenocarcinoma.

The Blood Tests Revealed

CA 19 antigen = 36.5 IU/ml.
ACE antigen = 1.25 ng/ml.
CA 125 antigen = 57.3 U/ml.
Alpha feto protein: 0.5ng/ml.
A cystectomy was performed.

Pathological examination of the ascites fluid revealed a cytological aspect in favour of inflammatory ascites fluid. There were no cells suspicious of malignancy at the border of the samples examined.

A laparotomy was performed under general anesthesia with orotracheal intubation.

Intraoperatively, a large amount of ascites was found and aspirated, the right ovary was found to have a tumour of about 40/25 cm polylobed with purulent contents. The uterus was normal in size. The contralateral ovary was normal. We decided to perform a total right adnexectomy.

Anatomical-Pathological Examination

1. **Macroscopic Study:** Cystectomy specimen measuring 40x25x20cm. It was renitent in consistency and greyish in colour. The section is entirely tumorous, sometimes cystic, the largest measuring 8cm with liquid content, sometimes solid. 1,2: solid part 3,4: cystic wall. Samples were taken and placed in 4 cassettes.
2. **Histological Study:** The tissue fragments examined show a tumour proliferation made up of layers and trabeculae. The cells were sometimes rounded, sometimes spindle-shaped with sparse cytoplasm, with a rounded nucleus, fine chromatin with a coffee-bean incision and Cell-Exner bodies. The stroma was abundant and fibrous with necrosis.
3. **Conclusion:** Histological appearance of a granulosa tumour.

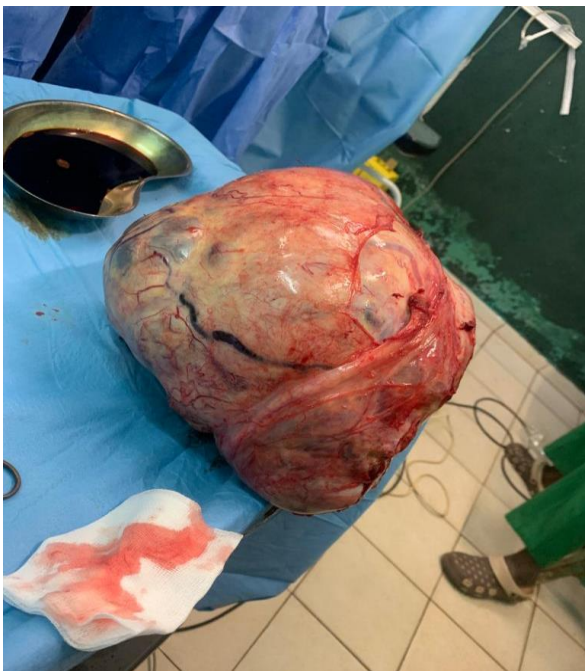

Image of the cyst after surgery

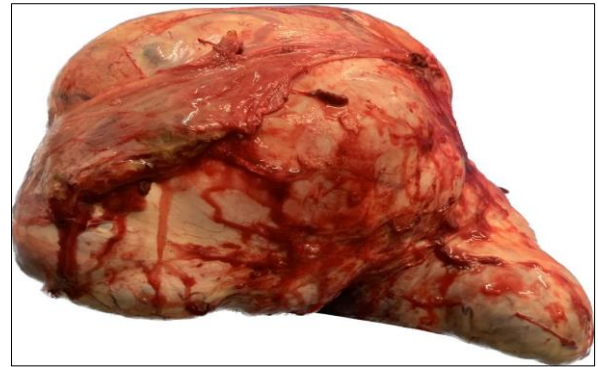
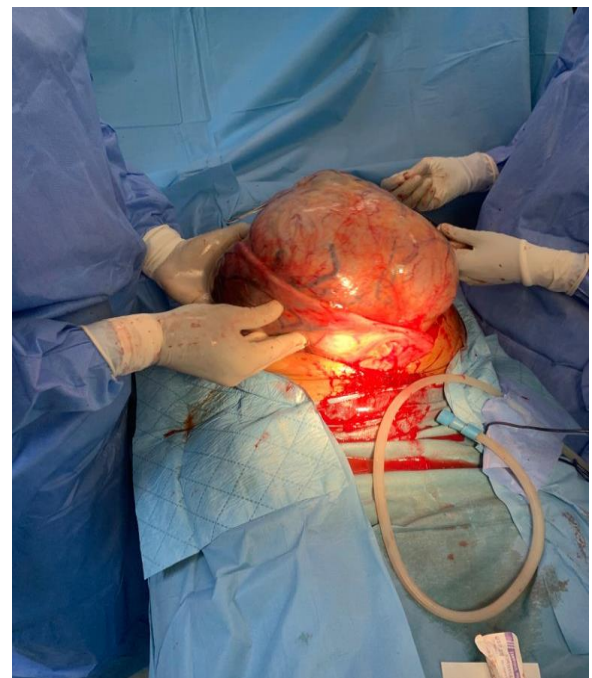
Image of the cyst after surgery



Intraoperative cyst image

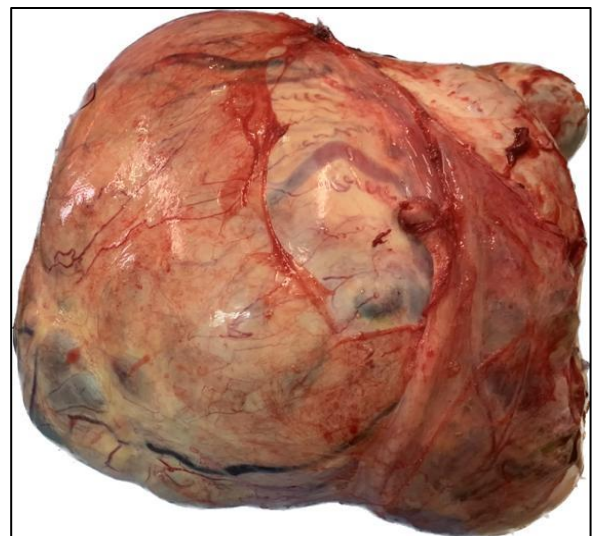


Image of the cyst after surgery

DISCUSSION

Frequency and Age of Occurrence

Granulosa tumours account for 3-4% of all ovarian tumours [4] and 5-10% of all ovarian cancers [5].

They are frequent functional secretory lesions.

Two different anatomical and clinical entities can be distinguished: The "adult" granulosa tumour and the "juvenile" granulosa tumour [3].

The "juvenile" form occurs most often before the age of 20 [6]; with a maximum frequency of 44% between the ages of 0 and 10 [7].

The "adult" form usually occurs after the age of 30 and in 70% of cases after the menopause [6].

Clinical Manifestations

Tumours of the juvenile granulosa are characterised by:

By a tumour syndrome: painful abdominal distension related to the size of the tumour, and, by an endocrine syndrome related to the secretory functions of these tumours such as isosexual precocious pseudo-puberty [8] in young girls in case of oestrogenic secretion; hirsutism, clitoral hypertrophy in case of androgenic secretion [9]. This endocrine syndrome is attenuated during pregnancy [3, 10]. Finally, we should mention rarer associations [11, 12], Ollier's disease and Mafucci's syndrome: these are non-hereditary mesodermal dysplasias associated, not exceptionally, with ovarian tumours either of the thecoma type or of the juvenile granulosa tumour type.

Adult granulosa tumours are characterised by an abdominal distension syndrome which is sometimes monstrous [13] or by signs of hyperoestrogenism after the menopause with metrorrhagia, endometrial hyperplasia which is sometimes atypical and may be previous to or associated with an adenocarcinoma [6].

Paraclinical Examinations

Ultrasound confirms the organic nature of the tumour by showing mixed, multi-locular structures with a thick wall, generally without exo- or endocystic vegetations.

Hormone measurements: estradiol is measured in the case of pseudo precocious puberty; it can be used as a tumour marker [13, 14]. Serum androgens should be requested in the presence of a masculinising syndrome. Inhibin is currently a good specific marker for granulosa tumours.

Pathological Anatomy

Macroscopy

The average size is 12 cm [14]. Tumours are bilateral in 3% of cases. The surface is smooth without

vegetations. The contents are solid-liquid or multicystic with serous contents. Necrotic and haemorrhagic foci may also be seen [7].

Microscopy

Juvenile granulosa tumours are characterised by dense patches of cells with unincised, hyperchromatic and often mitosing nuclei. Rare immature mucus-secreting follicles are seen. Luteinisation is common. Adult granulosa tumours are characterised by the presence of "coffee bean" nuclei and the cell arrangement in Call and Exner follicles. Luteinisation is rare and associated endometrial lesions are seen.

Immunohistochemistry

The vimentin marker is positive in about 80% of cases [15].

Prognosis

The individual prognosis is difficult to define and granulosa tumours should be considered as potentially malignant. The disease remains confined to the ovaries for a long time [14, 15]. Recurrences are rare and mostly observed after conservative treatment; their prognosis is poor. Metastases are very rare, affecting the lung, liver and bone.

Poor prognosis factors are: beyond stage IA, large size, ascites and capsular rupture.

Juvenile granulosa tumours generally have a good prognosis: 92% survival at 5 years. However, when they are malignant the prognosis is very poor.

Treatment

The ideal treatment for these tumours is surgical: adnexectomy in stage IA juvenile tumours; total hysterectomy without conservation in adult tumours. Radiotherapy has not been proven to be effective. Chemotherapy is proposed in the case of stage Ic tumours [14] or stage II tumours, in the case of recurrence as an adjunct to surgical revision [14], and must use at least one anthracycline [4, 14].

CONCLUSION

Granulosa tumours are rare tumours of the ovary, their diagnosis is histopathological. A distinction must be made between adult granulosa tumours and juvenile granulosa tumours which generally have a good prognosis.

REFERENCES

1. Evans 3rd, A. T., Gaffey, T. A., Malkasian Jr, G. D., & Annegers, J. F. (1980). Clinicopathologic review of 118 granulosa and 82 theca cell tumors. *Obstetrics and gynecology*, 55(2), 231-238.
2. KHATTECH, A., BOGNEL, C., PRADE, M., CHARPENTIER, P., DUVILLARD, P., &

- MICHEL, G. (1990). Tumeur de la Granulosa juvénile. Etude anatomoclinique à propos d'une observation. *Gynécologie (Paris. 1973)*, 41(2), 90-95.
3. Young, R. H., Dickersin, G. R., & Scully, R. E. (1984). Juvenile granulosa cell tumor of the ovary. A clinicopathological analysis of 125 cases. *The American journal of surgical pathology*, 8(8), 575-596.
 4. Powell, J. L., Johnson, N. A., Bailey, C. L., & Otis, C. N. (1993). Management of advanced juvenile granulosa cell tumor of the ovary. *Gynecologic oncology*, 48(1), 119-123.
 5. Mathier, C. (1989). Les formes rares de tumeurs de l'ovaire. *Revue du, Praticien (Paris)*, 39(26), 2330.
 6. Young, R. H., & Scully, R. E. (1984). Ovarian Sex Cord–Stromal Tumours: Recent Advances and Current Status. *Clinics in obstetrics and gynaecology*, 11(1), 93-134.
 7. Scully, R. E. (1988). Juvénile granulosa cell tumor. *Pediatric Pathology*, 8, 423-427.
 8. LAFFARGUE, F., & Charlier, C. (1992). Le syndrome féminisant des tumeurs endocrines de l'ovaire: Les tumeurs de l'ovaire à expression endocrine. *Gynécologie (Paris. 1973)*, 43(3), 178-180.
 9. Nakashima, N., Young, R. H., & Scully, R. E. (1984). Androgenic granulosa cell tumors of the ovary. A clinicopathologic analysis of 17 cases and review of the literature. *Archives of pathology & laboratory medicine*, 108(10), 786-791.
 10. Gabriel, R., & Wahl, P. (1992). CAT dans les tumeurs endocrines de l'ovaire chez la femme enceinte. *Gynécologie*, 43, 206-211.
 11. Tamimi, H. K., & Bolen, J. W. (1984). Enchondromatosis (Ollier's disease) and ovarian juvenile granulosa cell tumor. A case report and review of the literature. *Cancer*, 53(7), 1605-1608.
 12. Velasco-Oses, A., Alonso-Alvaro, A., Blanco-Pozo, A., & Nogales Jr, F. F. (1988). Ollier's disease associated with ovarian juvenile granulosa cell tumor. *Cancer*, 62(1), 222-225.
 13. Choi, C. H. M., & Pritchard, J. R. (1990). Large cystic granulosa cell tumor: case report. *American journal of obstetrics and gynecology*, 163(1), 74-76.
 14. Young, R. H., Dickersin, G. R., & Scully, R. E. (1984). Juvenile granulosa cell tumor of the ovary. A clinicopathological analysis of 125 cases. *The American journal of surgical pathology*, 8(8), 575-596.
 15. Biscotti, C. V., & Hart, W. R. (1989). Juvenile granulosa cell tumors. *Arch Pathol Lab Med*, 113, 40-46.