Scholars Journal of Medical Case Reports
Abbreviated Key Title: Sch J Med Case Rep
ISSN 2347-9507 (Print) | ISSN 2347-6559 (Online)
Journal homepage: https://saspublishers.com

OPEN ACCESS

Radiology

Bilateral Giant Renal Angiomyolipomas with Multiple Fat-Containing Hepatic Lesions: An Incidental CT Finding During COVID-19

Imane Boukhriss, MD[1]*, Sara Omari Tadlaoui, MD[1], Bouchra Dahmani, MD[1], Zineb Moudafia, MD[1], Siham Alaoui Rachidi, MD[1]

[1]Department of Radiology, Mohammed VI University Hospital, Tangier, Morocco

DOI: https://doi.org/10.36347/sjmcr.2026.v14i10.049 | **Received:** 19.08.2026 | **Accepted:** 21.10.2026 | **Published:** 24.10.2026

***Corresponding author:** Imane Boukhriss, MD
Department of Radiology, Mohammed VI University Hospital, Tangier, Morocco

Abstract **Case Report**

Background: Renal angiomyolipomas are benign mesenchymal tumors composed of blood vessels, smooth muscle, and adipose tissue. Although generally small and asymptomatic, they can occasionally reach enormous dimensions. Bilateral giant renal angiomyolipomas associated with multiple fat-containing hepatic lesions represent an unusual radiological finding. ***Case Presentation*:** We report the case of a 64-year-old patient admitted to the intensive care unit with severe COVID-19 pneumonia. Chest computed tomography incidentally revealed markedly enlarged and distorted kidneys containing massive bilateral heterogeneous masses with abundant macroscopic fat. Subsequent noncontrast abdominal CT demonstrated that the right and left renal masses measured 318 × 260 × 187 mm and 315 × 258 × 203 mm, respectively. Based on their characteristic fat-containing appearance, the lesions were considered consistent with giant bilateral renal angiomyolipomas. The examination also revealed 10 small, well-circumscribed hepatic lesions with negative attenuation values, suggesting macroscopic fat; the largest measured 17 × 8 mm. These lesions raised the possibility of hepatic angiomyolipomas, although their nature could not be definitively established. The patient's reported renal impairment precluded intravenous contrast administration, and further evaluation was not possible because he died from COVID-19 complications a few days after admission to the intensive care unit. ***Conclusion*:** This case highlights the incidental detection of exceptionally large bilateral renal angiomyolipomas on CT performed for COVID-19 pneumonia, accompanied by multiple indeterminate fat-containing hepatic lesions. It underscores the diagnostic value of recognizing macroscopic fat on CT while acknowledging the limitations of imaging-based characterization when further investigations are unavailable.

Keywords: Angiomyolipoma, Renal, Covid19, CT Scan, Incidentaloma.

Copyright © 2026 The Author(s): This is an open-access article distributed under the terms of the Creative Commons Attribution **4.0 International License (CC BY-NC 4.0)** which permits unrestricted use, distribution, and reproduction in any medium for non-commercial use provided the original author and source are credited.

INTRODUCTION

Renal angiomyolipomas (AMLs) are benign mesenchymal neoplasms belonging to the perivascular epithelioid cell tumor (PEComa) family and composed of varying proportions of blood vessels, smooth muscle cells, and adipose tissue. Classic renal AMLs typically contain macroscopic fat, which allows their identification on computed tomography (CT). Although most lesions are relatively small, some may grow to enormous dimensions. Tumors measuring more than 10 cm are generally classified as giant angiomyolipomas, and bilateral giant renal involvement is uncommon. Renal AMLs may occur sporadically or in association with tuberous sclerosis complex (TSC), making the recognition of bilateral or multifocal disease clinically relevant [1, 2].

Hepatic angiomyolipomas are rare mesenchymal tumors with variable imaging appearances related to their differing proportions of adipose tissue, smooth muscle, and blood vessels. Their characterization can be challenging, particularly when contrast-enhanced imaging or histopathological confirmation is unavailable [3]. We report an unusual case of exceptionally large bilateral renal angiomyolipomas incidentally detected on CT performed for severe COVID-19 pneumonia, accompanied by multiple small fat-containing hepatic lesions that could not be definitively characterized. This case highlights the importance of evaluating the upper abdominal structures visible on thoracic CT and of maintaining diagnostic caution when associated lesions cannot be fully investigated.

Case Report

We report the case of a 64-year-old man with a family-reported history of renal failure, poor adherence to medical care, and no medical follow-up for more than 2 years. He was admitted to the COVID-19 triage unit, during the peak of the pandemic, with respiratory distress.

Chest CT showed bilateral peripheral ground-glass opacities and consolidations, predominantly in the lower lobes. Additional findings included bronchiectasis, intralobular reticulation, perilobular thickening, and subpleural lines (Figure 1). The findings were highly suggestive of COVID-19 (CO-RADS 5), and SARS-CoV-2 infection was subsequently confirmed by PCR.

The upper abdominal images incidentally revealed enlarged, markedly distorted kidneys containing massive bilateral heterogeneous masses with abundant macroscopic fat.

A dedicated abdominal CT examination was subsequently performed to better characterize the lesions and assess their extent (Figures 2 and 3). Given the reported history of renal impairment, intravenous contrast material was not administered. The kidneys were markedly distorted by the bulky bilateral masses, which measured 318 × 260 × 187 mm on the right and 315 × 258 × 203 mm on the left.

The CT also revealed 10 oval, well-circumscribed hepatic lesions, the largest measuring 17 × 8 mm. These lesions demonstrated negative attenuation values on noncontrast CT, reaching approximately −35 HU, suggesting the presence of macroscopic fat (Figure 4).

Based on their renal origin and abundant macroscopic fat, the masses were radiologically most consistent with giant bilateral renal angiomyolipomas. The hepatic lesions could not be definitively characterized and were considered potentially compatible with hepatic angiomyolipomas.

The patient died from COVID-19 complications a few days after admission to the intensive care unit, precluding further clinical, genetic, and imaging evaluation.

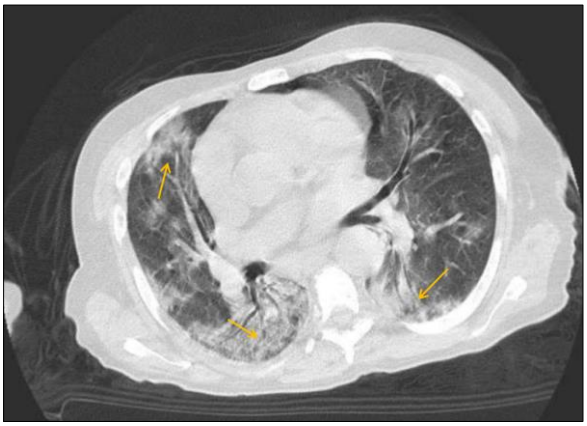

Figure 1: Chest CT images showing bilateral peripheral ground-glass opacities and consolidations consistent with COVID-19 pneumonia (arrows).

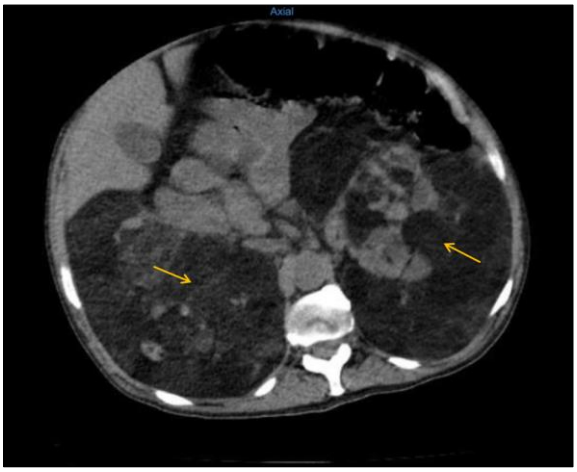

Figure 2: Axial noncontrast CT image demonstrating massive bilateral renal masses containing abundant macroscopic fat, consistent with giant renal angiomyolipomas (arrows)

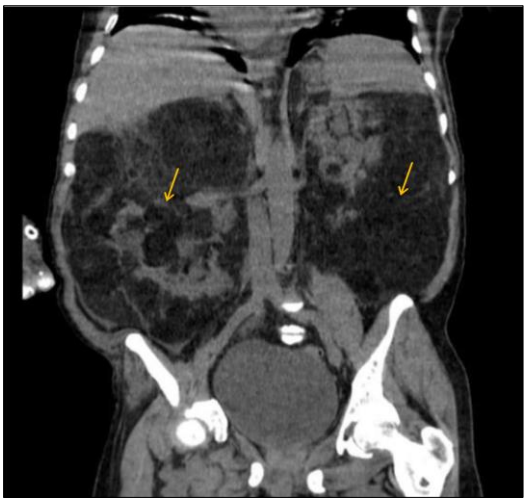

Figure 3: Coronal noncontrast CT image demonstrating the extensive bilateral renal masses containing macroscopic fat (arrows)

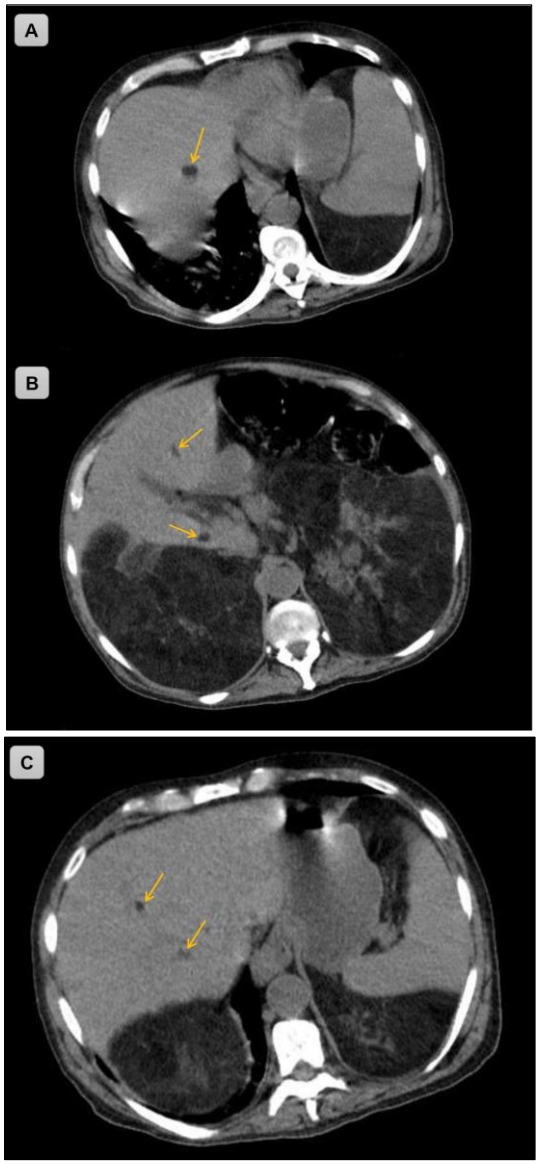

Figure 4: Axial noncontrast CT images (A–C) demonstrating multiple small, well-circumscribed, fat-containing hepatic lesions, the largest measuring 17 × 8 mm, with attenuation values as low as −35 HU (arrows)

Discussion

Angiomyolipomas are mesenchymal tumors composed of varying proportions of abnormal blood vessels, smooth muscle cells, and adipose tissue. They belong to the perivascular epithelioid cell tumor family [1].

Angiomyolipomas commonly occur in adults older than 40 years, and are sporadic in 80% of the cases, with a female predominance M:F=1:4 [4].

They most commonly occur in the kidneys but may also arise in other organs, including the liver, more rarely the skin [5], or the retroperitoneum [6].

Renal angiomyolipomas are often asymptomatic and discovered incidentally, but may become symptomatic when their size exceeds 4 cm, manifesting as abdominal pain, hematuria or even retroperitoneal hematoma caused by their rupture (Wunderlich syndrome).

Renal angiomyolipoma may be isolated or occur as part of Bourneville's tuberous sclerosis. AML is considered giant if the size exceeds 10 cm [2].

Renal AML appears on imaging as a solid, heterogeneous renal cortical mass containing macroscopic fat in adult.

In adults, classic renal angiomyolipomas typically appear as renal masses containing macroscopic fat. On ultrasound, they commonly appear as hyperechoic lesions, usually with posterior acoustic shadowing. On non contrast CT, intratumoral macroscopic fat, typically demonstrating attenuation values of −10 HU or lower, strongly supports the diagnosis of classic renal angiomyolipoma. The relative proportions of adipose tissue, smooth muscle, and blood vessels contribute to the heterogeneous appearance of these lesions [7].

On MRI, angiomyolipomas demonstrate variable signal intensity depending on their tissue composition. Macroscopic fat typically exhibits high signal intensity on T1- and T2-weighted images and signal loss on fat-suppressed sequences. Chemical-shift imaging may demonstrate an India ink artifact at the interface between fat and nonfat components [4].

The presence of macroscopic fat within a renal mass strongly favors angiomyolipoma; however, this finding is not absolutely pathognomonic, as rare renal cell carcinomas containing macroscopic fat have been reported [8]. When the fat component is minimal or absent, distinguishing angiomyolipoma from renal cell carcinoma may be more challenging.

The hepatic lesions identified in our patient were small, well-circumscribed, and demonstrated negative attenuation values on non-contrast CT, suggesting the presence of macroscopic fat. Hepatic angiomyolipomas are a possible diagnosis, particularly given the coexistence of bilateral renal angiomyolipomas.

Liver AML are well circumscribed, mostly fatty mass in liver. Ct usually shows well defined mass with heterogeneous attenuation values due to presence of fat and soft tissue densities, but may be almost completely fat or soft tissue density Mass [3].

The imaging findings were consistent with giant bilateral renal angiomyolipomas associated with multiple fat-containing hepatic lesions, which may represent hepatic angiomyolipomas.

This association raised the possibility of tuberous sclerosis complex (Bourneville disease); however, further clinical, genetic, and imaging evaluation could not be performed because the patient died from COVID-19 complications a few days after admission to the intensive care unit. The available clinical records did not document any other diagnostic features of tuberous sclerosis complex.

Conclusion

This case highlights the incidental CT detection of exceptionally large bilateral renal angiomyolipomas in a patient admitted with severe COVID-19 pneumonia. The coexistence of multiple fat-containing hepatic lesions raised the possibility of hepatic angiomyolipomas and underlying tuberous sclerosis complex. This observation emphasizes the importance of carefully evaluating abdominal structures visible on thoracic CT examinations and recognizing macroscopic fat as a key imaging feature of angiomyolipomas.

Conflict of Interest:

The authors have no conflicts of interest to disclose. None of the authors received outside funding for the production of this original manuscript and no part of this article has been previously published elsewhere.

References

1. Caliò A, Brunelli M, Segala D, et al. Angiomyolipoma of the kidney: from simple hamartoma to complex tumour. Pathology. 2021;53(1):129-140. doi:10.1016/j.pathol.2020.08.008.
2. Bains L, Bhatia R, Lal P, Bhagria G. Giant bilateral angiomyolipoma of the kidney. Ann R Coll Surg Engl. 2021;103(6). doi:10.1308/rcsann.2020.7036
3. Seow J, McGill M, Wang W, Smith P, Goodwin M. Imaging hepatic angiomyolipomas: key features and avoiding errors. Clin Radiol. 2020;75(2):88-99. doi:10.1016/j.crad.2019.09.135
4. Foster BR, Fananapazir G. Diagnostic Imaging: Genitourinary. 4th ed. Elsevier; 2021.

5. Ammanagi AS, Dombale V, Shindholimath V. Cutaneous angiomyolipoma. Indian Dermatol Online J. 2012;3(1):40-41. doi:10.4103/2229-5178.93501
6. Strahan A, King J, McClintock S. Retroperitoneal angiomyolipoma: a case report and review of the literature. Case Rep Radiol. 2013;2013:457383. doi:10.1155/2013/457383
7. Cui L, Zhang JG, Hu XY, et al. CT imaging and histopathological features of renal epithelioid angiomyolipomas. Clin Radiol. 2012;67(12). doi:10.1016/j.crad.2012.08.006
8. Galatola R, Stanzione A, Sirignano C, et al. Giant epithelioid angiomyolipoma: an imaging-related differential diagnosis among fat-containing renal masses. Clin Genitourin Cancer. 2020;18(1). doi:10.1016/j.clgc.2019.10.028.