

Original Research Article

Functional outcome of Volar Barton's Fracture treated with Volar Plate Osteosynthesis

Dr. Madhukar¹, Dr. Srinivasan N¹, Dr. Pugazhendhi G¹, Dr. Vijayanarasimhan², Dr. Sivakumar A²,
Dr. Venkatachalam K³

¹Assistant Professor, ²Professor, ³Associate Professor, Department of Orthopaedics, Sree Balaji Medical College and Hospital, 7, Works Road, Chromepet, Chennai – 600 044, Tamilnadu, India.

*Corresponding author

Dr. Madhukar

Email: drmadhukarca@gmail.com

Abstract: Volar Barton's Fracture is the intraarticular fracture of distal radius associated with dislocation or subluxation of radio carpal joint. Conservative treatment is difficult and is often associated with failure and complications. Volar plate osteosynthesis (open reduction and internal fixation) gives immediate anatomic reduction and good joint congruity allowing for early rehabilitation and good functional outcome, thus reducing short term and long term complications. We had a prospective study of 28 patients treated with volar plate osteosynthesis with 89.3% excellent to good results using modified Cooney's Score. Volar plate Osteosynthesis can be considered "Gold Standard" treatment for volar Barton's Fracture for its good functional outcome.

Keywords: Volar Barton's Fracture, Volar Plate Osteosynthesis (ORIF), Functional Outcome, Modified Cooney's Score, Gold Standard.

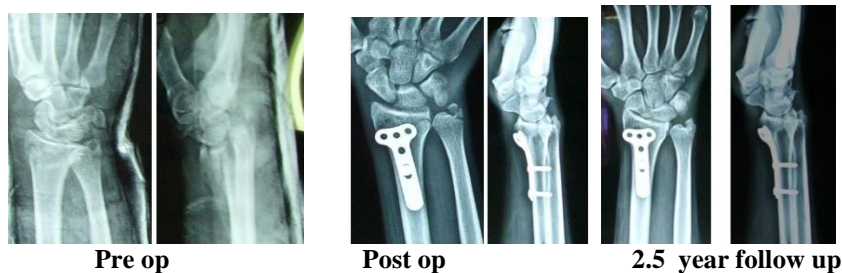
INTRODUCTION:

Barton's fractures, named after the American surgeon John Rhea Barton; who first described it in 1838, is a fracture of the distal end of the radius that involves the articular surface and is usually associated by subluxation or dislocation of the radio carpal joint [1,2,3,4]. The fracture can be either an anterior marginal (volar Barton) or posterior (dorsal Barton) marginal fracture [3, 5]. These fractures are not uncommon and account for approximately 1.2 to 4.2% of distal radius fractures [3]. The fractures may be either due to low energy or high energy injuries but high energy injuries are more frequent cause of volar Barton's Fracture [3, 6, 7]. Volar Barton's fractures stand apart other distal radius fractures in that there is an associated radio carpal dislocation. Conservative treatment is usually unsuccessful in these fractures

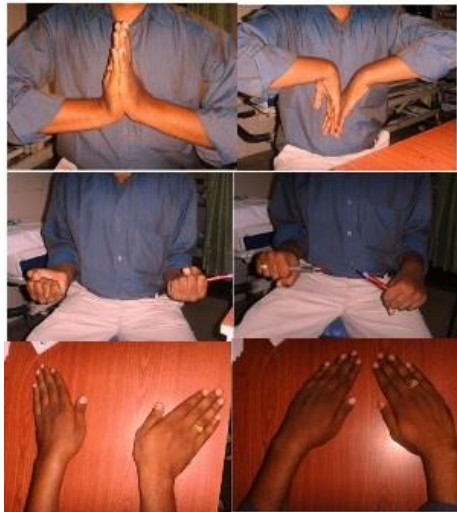unlike other distal radius fractures which have good functional outcome with conservative treatment. These fractures are fraught with complications like loss of reduction, malunion, nonunion, deformity, subluxation and instability [8, 9, 10, 11]. Various surgical treatment modalities are reported in literature. Open Reduction and Internal Fixation (Osteosynthesis) with a volar plate system have shown good results. The advantages of this system are good reduction of articular surface and immediate stability of joint leading early mobilization of wrist and potential reduction of wrist stiffness and reduction of early onset osteoarthritis of wrist [2, 3, 12, 13]. According to AO classification, volar Barton's fractures are type B3 fractures of the distal radius (Type 23 –B3) (Fig. 1) [14]. The aim of this prospective study is to evaluate the functional outcome of distal radius fractures treated by volar plate osteosynthesis.

Case illustration

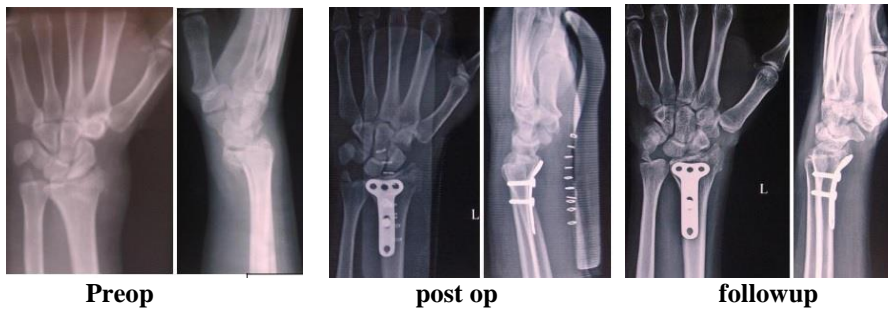
Case 1



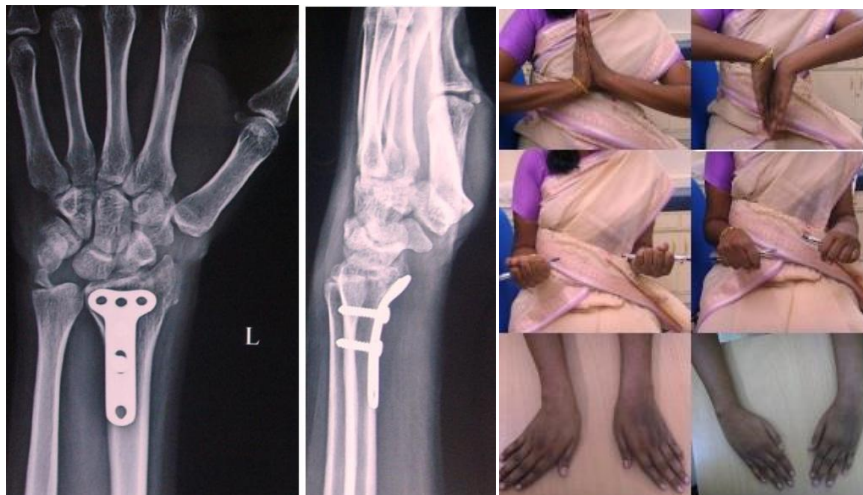Clinical outcome



Case 2



Clinical outcome



MATERIALS AND METHODS:

The study was prospective study conducted at Sree Balaji Medical College and Hospital, Chromepet, Chennai (TN) between April 2012 to January 2016. We had 546 distal radius fractures of which 342 were extra articular and 204 were intraarticular of which 28 were volar Barton's fracture which accounted for 13.72% of intraarticular fractures and 5.12% of distal radius fractures. We had inclusion criteria of patients with age

between 20 and 60 years, both sexes, fractures presenting and operated within 7 days of injury. We included all patients irrespective of associated injuries elsewhere in the body. Our exclusion criteria patients' age below 20 years and above 60 years and fractures presenting and operated after 7th day. Fracture type B3 of AO Comprehensive Classification of Fractures (Fig. 1) were only included in the study. All the volar Barton's fracture cases were in the inclusion criteria.

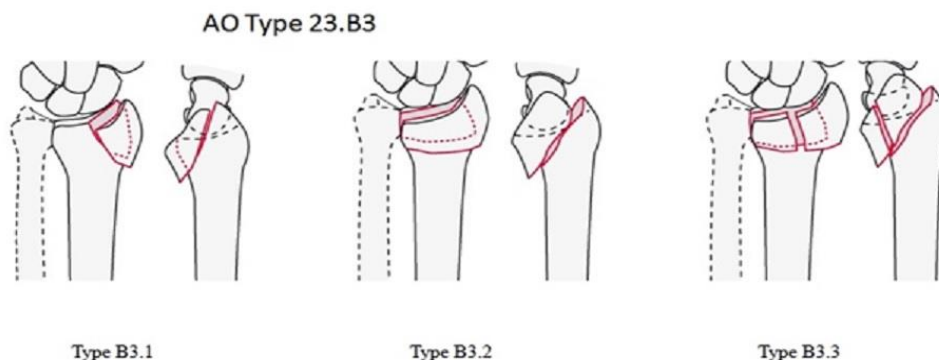


Fig. 1: AO classification of Type 23.B3
Type B3.1 - a small volar fragment, with the sigmoid notch intact
Type B3.2 - a large volar fragment that includes the sigmoid notch
Type B3.3-comminuted volar fragment

Preoperative Protocol:

All the patients with volar Barton’s fracture were evaluated with X-ray of Wrist Anteroposterior and Lateral views. Haematoma block is given to reduce pain and assist closed reduction. Immediate closed reduction and below elbow plaster slabs were applied and post reduction X-rays were taken. This assists to reduce pain, swelling and deformity. The post reduction X-rays assist in understanding the fracture

pattern better, which would help in pre operative planning of fixation of fracture and judge acceptable parameters of fracture reduction (Table.1 & Fig. 2). Concurrently a detailed preoperative work up is done for fitness for surgery which includes laboratory investigations, chest X-rays, ECG and Echocardiogram when needed. Patient is operated as early as feasible either under General or regional anaesthesia.

Table 1: Normal and Acceptable Parameters

Radiographic parameter	Normal	Acceptable
Radial length	± 2mm comparing level of lunate facet to ulnar head	No more than 2mm of shortening relative to ulnar head
Radial inclination	23° as measured from lunate facet to radial styloid	No less than 10°
Palmar tilt	11° volar tilt	Neutral
Intra-articular step or gap	None	Less than 2mm of Either

- Radial inclination = 23°
- Radial length = 12mm
- Palmar tilt = 10°
- Scapholunate angle = 60° +/- 15°

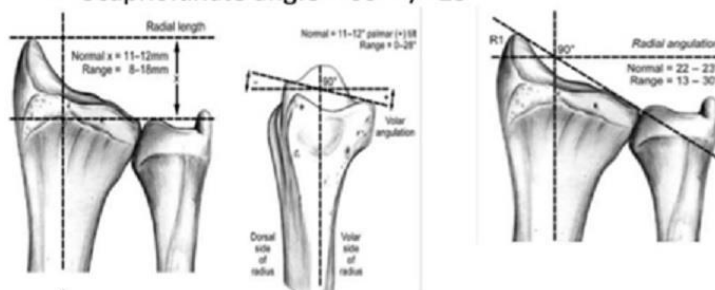


Fig. 2: normal parameters of wrist

Surgical technique:

The patient was placed on operating table in supine position and upper limb placed over hand table. Tourniquet was used in most of the patients. X-ray Image Intensifier(C-Arm) is mandatory in all cases to

check the reduction and assist the fixation of fracture. The fracture was reached using Ellis approach in all the cases. An 8-cm incision is made on the radial border of the flexor carpi radialis tendon. The v-shape of the distal part of the incision provides better access to the

articular surface (Fig 3). The incision is carried through the flexor carpi radialis tendon sheath. The tendon sheath is opened and the forearm fascia on the radial border of the flexor carpi radialis is incised. The forearm fascial incision should be made along the radial side of the flexor carpi radialis tendon to ensure that the palmar cutaneous branch of the median nerve (Fig 4), which arises near the ulnar side of the flexor carpi radialis tendon is protected. The index finger of the surgeon is then swept under the flexor pollicis longus muscle to gain rapid exposure of the pronator quadrates (Fig 5). Retract the flexor pollicis longus tendon radial side and the median nerve and the other tendons ulnar side. An L-shaped incision is made over the radial border of the pronator quadratus to prevent full elevation of that structure from the radius (Fig 6). After

exposing the fracture site we place the rolled towel under the wrist to facilitate the reduction and after reducing the fracture and fixed with —T buttress plate to the proximal fragment, the distal transverse part of the plate acts as a buttress and holds the fracture in reduced position. Two screws are usually required in the proximal fragment, and usually no screw is inserted through the distal part of the plate into the fracture fragments, the reduction of the fracture and restoration of the articular surface are confirmed by direct observation and checked under C- arm(Fig 7). Additional k-wires or screws can be used if necessary for a good reduction. Replace the pronator quadratus over the plate to its origin on the radius and close the wound without drain after perfect anastomosis and sterile dressings applied.

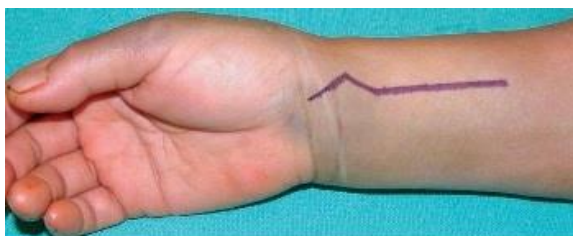


Fig. 3

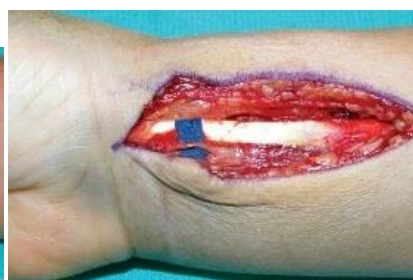

Fig. 4

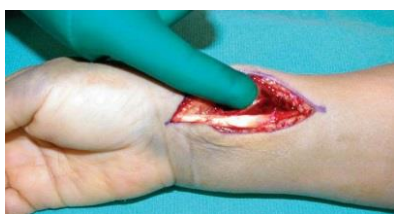

Fig. 5

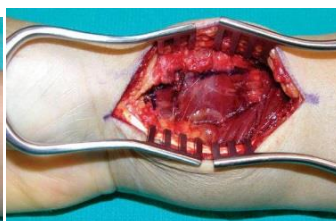


Fig. 6

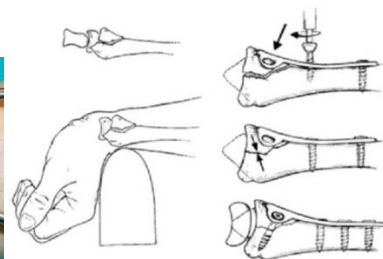


Fig. 7

Post Operative Protocol:

We routinely recommend wrist brace for all patients for periods of two weeks. Intermittent active and gentle assisted passive wrist mobilization started from Day 1. Patients were reviewed at 2nd week for suture removal and functional score was assessed at 4th, 8th, 12th week then every 6 months. All the patients were followed up for a minimum period of 2 years. The maximum follow up was for 3 years 3 months. Grip strength was measured by Dynamometer, Range of movements measured by hand held Goniometer. The functional score is a clinical scoring system of Green and O'Brien 1978[15], modified by Cooney *et al.*; 1980 Score (Table. 2)[16].

RESULTS

We had 28 patients with volar Barton's fracture. All the patients had unilateral involvement none had bilateral involvement. Volar Barton's fractures constituted of 5.12% of all distal radius fractures (28 of 546). There were 19(67.89%) male

patients and 9(32.14%) female patients. Male to female ratio was 2.1:1 in our study. 16(57.14%) patients had fracture on right side and 12(42.86%) had on left. The youngest patient in the study was 21 years and oldest 56 years. There were 4 patients in age group 20-30 years, 16 patients in 31-40 years, 4 patients in 41-50 years and 2 patients in 51-60 years. Mean age was 35.3 years; median was 34 years and mode 31 years.

23(75%) patients were injured because of Road Traffic Accident (RTA), 3(10.7%) patients had slip and fall at home and 4(14.3%) patients were injured in contact sports. 2 (7.14%) fractures were Type B3.1, 18(64.29%) fractures were Type B3.2 and 8(28.57%) fractures were Type B3.3.

There were 5 patients with associated injuries. One patient had associated fracture of shaft of tibia. One had associated fracture of shaft of femur. One had involvement of fracture of ipsilateral clavicle. One patient had associated ipsilateral fracture of humerus.

One patient had pneumothorax with multiple rib fractures. The minimum follow up period was 2 years and maximum 3 years 3 months. The mean follow up period was 2 years 8 months.

On analysis of functions, there were 16 patients did not have any pain, 8 patients had mild pain, 3 patients moderate pain and one patient had severe pain and was out of work due to pain.

13 patients had full normal grip strength when compared to opposite side. 8 patients more than 90% hand grip (less than 10% reduction or compromise). 6 patients had grip strengths between 75-90% and only one patient had less than 50% hand grip.

Of 28 patients Range of movements Total arc (Flexion + Extension), 23 patients had >140° of movements, 4 patients had 100° to 140°. One patient had 90° of range of movements.

Active supination of the involved wrist averaged 85 degrees (range 60 to 90 degrees) and active pronation of the involved wrist averaged 75 degrees (range 60 to 80 degrees), compared with 90 degree and

80 degree degrees, respectively, for the contralateral wrist.

Active radial deviation of the involved wrist averaged 27 degrees (range 10 to 30 degrees) and active ulnar deviation averaged 44 degrees (range 30 to 50 degrees), compared with 30 degrees and 49 degrees, respectively, for the contralateral wrist.

According Modified Cooney's, Green and O'Brien scoring system, 16(57.14%) patients had excellent results (score 90 to 100), 9 (32.14%) of them had Good results (score 80 to 89), 2 (7.14%) patients had fair results (score 65 to 79), and one (3.6%) patients had poor result (score <65).

In our study about 89.3% patients had well to excellent results.

2(100%) patients with Type B3.1 fracture and 14 of 18(77.8%) patients with Type B3.2 fractures had excellent results and 4 of 18(22.2%) with Type B3.2 fractures had good results. 5(62.5%) of 8 patients with Type B3.3 fracture had good results, 2(25%) of 8 patients with Type B3.3 fracture had fair results and 1(12.5%) of 8 patients with Type B3.3 had poor results.

Table 2: Modified Cooney, Green and O'Brien functional score for wrist [15, 16]

Category	Findings	Score
pain	No pain	25
	Mild occasional	20
	Mild, regular, no significant effect on activity	15
	Moderate, activity reduced, no pain at rest	10
	Severe, pain at rest	0
Range of movements(arc) of	>140°	25
	100 to 140° degree	20
	70° to 99° degree	15
	40° to 69° degree	10
	<40° degree	0
Hand grip (compared to normal side)	Normal	25
	75 to 90 %	20
	50 to 74 %	15
	25 to 49%	10
	<24%	0
Activity	No Limitations	25
	Normal duties, Some medication	20
	Light duties due to wrist pain	15
	Unable to work	0
Final Results	Excellent 90-100	
	Good 80-89	
	Fair 65-79	
	Poor <65	

DISCUSSION

Volar Barton's fracture is an unstable intraarticular anterior rim fracture of distal radius associated with anterior subluxation or dislocation of wrist joint. The primary goal in treatment of this injury

is to provide good reduction and immediate stability to achieve anatomic fracture union, allow the quick return of hand function and avoid complications [17, 18, 19]. Fracture healing depends on a minimal gap, adequate stability, and sufficient blood supply [20].

Volar Barton's fractures are inadequately treated by conservative means with high rate malunion and joint subluxation. Reduction of Barton's fracture-dislocation is often very difficult to achieve by manipulation and closed reduction and even in cases where manipulation and closed reduction is successful, re-dislocation occurs frequently no matter what kind of plaster cast is used, hence open reduction is necessary to restore the correct alignment of the fragments. For the distal radius, massive cancellous bone can speed the fracture healing process. Therefore, a nonunion at this area is rare. On the other hand, malunion is not uncommon; volar Barton's fractures often produce volar subluxation of the carpus [2, 3]. The principle of treatment is mainly to provide anatomic reduction and stabilization [3]. A malunion of a volar Barton's fracture can cause serious disability, which is very complicated to treat. Additionally, the articular cartilage may be severely injured and cannot regenerate [21, 22]. Therefore, prevention of a malunited volar Barton's fracture is extremely important to avoid having to treat a malunion which can lead to instability, stiffness, poor function and early osteoarthritis of wrist. To avoid poor function of the joints, wrist and finger range-of-motion exercises should be implemented as early as possible. This is especially important for Barton's fractures that have intraarticular involvement. Once adhesion in the joint occurs, treatment becomes very complicated. Both intra-articular and extra-articular release techniques are very difficult.

Various studies have shown good functional results and good satisfaction rates of volar plating are 77-94% [2, 3, 23, 24]. We have treated 28 patients with volar Barton's fracture with open reduction and internal fixation (osteosynthesis) with volar plating and studied their functional outcome. 89.3% (25 of 28) patients had excellent to good results. Fair results were seen only 2 patients (7.14%) and Poor results were seen in only 1 patient (3.6%). All the patients with Type B3.1 fracture had excellent results. All the patients with Type B3.2 fractures had excellent results (14 of 18) to good results (4 of 8). 5 of 8 patients with Type B3.3 fractures had good results. All the patients with Fair to poor results were seen with Type B3.3 fractures only. Two patients with Type B3.3 had fair results and one patient had poor results.

The patient with poor outcome had an associated fracture femur and was operated concomitantly for both the fractures on 7th day of injury. He developed carpal tunnel syndrome at 4 weeks and after confirmation of diagnosis by nerve conduction studies, surgical exploration and release of median nerve was undertaken. We found that the nerve was caught within the fibrous tissue. The same patient later developed reflex sympathetic dystrophy, which lead to severe stiffness of wrist and hand joints and there was

prolonged rehabilitation period which lead to poor outcome.

The multifragmented nature of the articular surface in Type B3.3 fractures necessitated the use of additional implants to supplement the volar T plate in four patients in our study. The surgeon should be prepared to use an additional Kirschner wire or screw to secure a volarly displaced fragment consisting of the styloid process or the lunate facet.

CONCLUSIONS

Volar Barton's fractures are best treated with volar plate osteosynthesis. It is a uncomplicated procedure and allows early mobilization thus gives good final functional outcome. Volar plate osteosynthesis can be considered as "Gold Standard" treatment for volar Barton's fracture with its high surgical success and good functional outcomes. Long term studies would be good to find long term functional outcomes and long term complications associated with this treatment modality.

REFERENCES

1. Peltier LF; Eponymic fractures: John Rhea Barton and Barton's fractures. *Surgery*, 1953; 34, 960.
2. Jupiter JB, Fernandez DL, Toh CL, Fellman T, Ring D; Operative treatment of volar intraarticular fractures of the distal end of the radius. *J Bone Joint Surg Am*. 1996; 78:1817–1828.
3. Aggarwal AK, Nagi ON; Open reduction and internal fixation of volar Barton's fractures: a prospective study. *J Orthop Surg (Hong Kong)*. 2004; 12:230–234.
4. Mehara AK, Rastogi S, Bhan S, Dave PK; Classification and treatment of volar Barton fractures. *Injury*. 1993; 24:55–59.
5. Thompson GH, Grant TT; Barton's fractures-reverse Barton's fractures. Confusing eponyms. *Clin Orthop Relat Res*. 1977; 122:210–221.
6. Ellis J; Smith's and Barton's fractures. A method of treatment. *J Bone Joint Surg Br* 1965; 47:724-7.
7. Woodyard JE; A review of Smith's fractures. *J Bone Joint Surg Br* 1969; 51:324-9.
8. Vasenius J; Operative treatment of distal radius fractures. *Scand J Surg*. 2008; 97:290–296.
9. Bartl C, Stengel D, Bruckner T, Rossion I, Luntz S, Seiler C *et al.*; Open reduction and internal fixation versus casting for highly comminuted and intra-articular fractures of the distal radius (ORCHID): protocol for a randomized clinical multi-center trial. *Trials*. 2011; 12(1):84.
10. Dicipinigaitis P, Wolinsky P, Hiebert R, Egol K, Koval K, Tejwani N; Can external fixation maintain reduction after distal radius fractures. *J Trauma*. 2004; 57:845–850.
11. Dai MH, Wu CC, Liu HT, Wang I, Yu C, Wang K *et al.*; Treatment of volar Barton's fractures: comparison between two common surgical

- techniques. *Chang Gung Med J.* 2006; 29(4):388–394.
12. Harness N, Ring D, Jupiter JB; Volar Barton's fractures with concomitant dorsal fracture in older patients. *J Hand Surg Am.* 2004; 29:439–445.
 13. Wright TW, Horodyski M, Smith DW; Functional outcome of unstable distal radius fractures: ORIF with a volar fixed-angle tin plate versus external fixation. *J Hand Surg Am.* 2005; 30:289–299.
 14. Müller ME, Nazarian S, Koch P, Schatzken J; *The Comprehensive Classification of Fractures of Long Bones.* New York, NY: Springer; 1990.
 15. Green, D.P, E.T. O'Brien; Open reduction of carpal dislocations: Indications and operative techniques. *J. Hand. Surg. Am.*, 1978; 3: 250-265.
 16. Cooney WP, Dobyns JH, Linscheid RL; Complications of Colles fractures. *J. Bone. Joint Surg. Am.*, 1980; 62: 613-619.
 17. Minegishi H, Dohi O, An S, Sato H; Treatment of unstable distal radius fractures with the volar locking plate. *Ups J Med Sci.* 2011; 116:280–284.
 18. Ark J, Jupiter JB; The rationale for precise management of distal radius fractures. *Orthop Clin North Am.* 1993; 24:205–210.
 19. Bradway JK, Amadio PC, Cooney WP; Open reduction and internal fixation of displaced, comminuted intra-articular fractures of the distal end of the radius. *J Bone Joint Surg Am.* 1989; 71:839–847.
 20. Karlstrom G, Olerud S; Fractures of the tibial shaft; a critical evaluation of treatment alternatives. *Clin Orthop Relat Res.* 1974; 105:82–115.
 21. Mow VC, Proctor CS, Kelly MA; Biomechanics of articular cartilage. In: Nordin M, Frankel VH, eds. *Basic Biomechanics of the Musculoskeletal System.* 2nd ed. Philadelphia: Lea & Febiger, 1989:31-58.
 22. West RV, Fu FH; Soft-tissue physiology and repair. In: Vaccaro AR, ed. *Orthopaedic Knowledge Update 8.* Rosemont, IL: American Academy of Orthopedic Surgeons, 2005:15-27.
 23. Pattee GA, Thompson GH; Anterior and posterior marginal fracture-dislocations of the distal radius. An analysis of the results of treatment. *Clin Orthop Relat Res.* 1988; 231:183-95.
 24. Jose C. De Oliveira; Barton's Fractures. *J Bone Joint Surg Am.* 1973; 55:586-594.