

Original Research Article

Ultrasonography of Thyroglossal Duct Cyst; central solid component as a predictor of malignancy– experience with seven cases

Omar Sharief Kirmani¹, Shahnawaz Bashir², Syed Ruzina Firdose³, Shah Naveed⁴, Tanveer Hassan Banday⁵, Sajjad Ahmad Dar⁶, Rouf Ahmed⁷

¹Associate Professor, Department Of Radiodiagnosis and Imaging, Govt. Medical College, Srinagar, India

²PDCC HPB Interventional Radiology, Department of Interventional Radiology, Institute of Liver and Biliary Sciences, New Delhi, India

³Lecturer, Department Of Radiodiagnosis and Imaging, Govt. Medical College, Srinagar, India

⁴Resident Surgical Oncology, Cancer Institute and Research, Patna, India

⁵Consultant, Department of Gastroenterology, BGS Global Hospital, India

⁶Professor and head, Department Of Radiodiagnosis and Imaging, Govt. Medical College, Srinagar, India

⁷Professor and Head, Department of ENT and HNS, Govt. Medical College, Srinagar, India

***Corresponding author**

Shahnawaz Bashir

Email: dr.shahnawazbashir@gmail.com

Abstract: Thyroglossal duct carcinoma (TGDC) is a rare disease with few reported series. We review our experience of seven cases to help preoperative diagnosis and thus the management of this rare condition. A review of the clinical presentation, fine needle aspiration cytology (FNAC) and histological diagnosis was done in seven patients with ultrasound (USG) documented “solid internal component” in a thyroglossal duct cyst. The Ultrasound features were analyzed in detail. Ultrasound of the neck and image-guided FNAC of the cyst may be adequate initial investigation for thyroglossal cysts. FNAC by itself is not a good investigation to diagnose TGDC as rate of false-negatives and inadequate specimens are high. Solid internal component with echogenic micro calcifications on imaging was predictive of carcinoma within a thyroglossal cyst in seven out of seven cases. To our knowledge, our paper is the first series of cases of its kind with emphasis on imaging and preoperative diagnosis of thyroglossal cyst carcinoma.

Keywords: Thyroglossal duct carcinoma, papillary carcinoma thyroid (PTC), Ultrasound (USG), fine needle aspiration cytology (FNAC), solid internal component.

INTRODUCTION

The thyroid gland descends from the foramen cecum to its location at the point below the thyroid cartilage. It leaves behind an epithelial tract known as the thyroglossal tract; this tract usually disappears during the 5th–10th gestational weeks. The descent of the thyroid through the anterior midline neck explains several anomalies that relate to thyroid pathology. Along the pathway of thyroid descent, a cyst with ciliated pseudo stratified epithelium and variable amounts of thyroid tissue may remain which is called thyroglossal duct cysts. Thyroglossal duct cyst is the most common congenital anomaly in thyroid development and occurs in 7% of the adult population [1]. Thyroglossal duct cyst accounts for 70% of congenital neck masses [2] and usually manifests as an enlarging painless neck mass in children or young adults. If infected it may present as a red warm painful lump. In most circumstances diagnosis can be made by history and physical examination [3]. It may move with swallowing and classically elevates on tongue

protrusion. Brentano in 1911 and Uchermann in 1915 are credited as being among the first to describe a neoplasm in a thyroglossal duct remnant; the median age at presentation is 40 years and most patients are asymptomatic (cited by Weiss and Orlich) [4].

The incidence of carcinoma in thyroglossal duct cysts is less than 1%. [5,6]. In a 2004 review of 215 cases, 80% were papillary carcinoma [5,7]. Other cancers in decreasing frequency were squamous cell carcinoma, follicular carcinoma, and Hürthle cell, insular and rarely anaplastic carcinoma. Medullary carcinoma has not been reported in a thyroglossal cyst [5, 8-10].

A review of the clinical presentation, fine needle aspiration cytology (FNAC) and histological diagnosis was done in seven patients with ultrasound (USG) documented “solid internal component” in a thyroglossal duct cyst scanned in past three years. The FNAC diagnosis, USG findings and histopathological

diagnosis were analyzed. Particular emphasis was given on the preoperative ultrasonography (USG) findings, which could help to reach a preoperative diagnosis of TGDC or suspicion of TGDC.

The purpose of this paper is to describe the ultrasound imaging features of thyroglossal duct cyst with solid internal component; and to find the significance of a central solid component as a predictor of papillary carcinoma.

CASES

The cases are summarized in table 1 and the USG findings in table 2. The patients' age varied from

18 years to 50 years. There were 4 females and 3 males. All the patients had clinically palpable swelling in the neck in the midline or paramedian location. Only one case (case no. 2) was known case of thyroglossal cyst carcinoma (PTC by FNAC) before the USG was performed. The USG findings were highly specific for the malignancy. The most important findings were "presence of an internal solid nodular component within the cystic lesion" and the "tiny calcifications in the solid nodular component" which were seen in all the seven cases. Lateral cervical lymphadenopathy was seen in three case with level I and II nodes. Blind FNAC was positive in only one case. Whereas USG guided FNAC confirmed malignancy in all the five out of five cases.

Table 1: Summary of the results observed.

S. n.	Age (yrs)	G	Symptoms	location	Blind FNAC diagnosis	USG diagnosis	USG guided FNAC Diagnosis	Lymph node enlargement	surgery	Histopathological examination
1	18	M	Swelling	Left paramedian	TGC	TGC with solid internal component	PTC	nil	Sistrunks	PTC
2	25	F	Swelling	Midline infrahyoid	TGC with papillary carcinoma	TGC with solid internal component	Not done	Bilateral level II	Sistrunks operation with excision of level II lymph node	PTC
3	21	F	Swelling	Right Paramedian	TGC	TGC with solid internal component	PTC	nill	Sistrunks	PTC
4	30	M	Swelling	Midline Infrahyoid	TGC	TGC with solid internal component	PTC	nill	Sistrunks	PTC
5	50	M	Swelling	Midline	TGC	TGC with solid internal component	PTC	Bilateral level II	Sistrunks operation with excision of level II lymph node	PTC
6	25	F	Swelling	Left paramedian	TGC	TGC with solid internal component	PTC	nill	Sistrunks	PTC
7	36	F	Recurrence of swelling	Midline	Not done	TGC with solid internal component	Not done	Level I	Sistrunks operation with excision of level I lymph node	PTC

FNAC= fine needle aspiration cytology, USG = Ultrasonography, TGC = thyroglossal cyst, PTC = papillary carcinoma thyroid.

The patient at serial 7 was an adult female with a previous history of thyroglossal cyst excision 12 years

back and now presented with a recurrence of swelling from past 2 years (Fig. 1a). The USG showed a cystic

lesion with a solid internal component and micro calcifications in the solid internal component (fig. 1 b and c). Based on these findings we reported the USG as recurrent thyroglossal cyst with possible PTC. No preoperative FNAC was done in this patient. The patient was operated and the specimen was sent for the

histopathological examination. However, initial biopsy report mentioned a thyroglossal cyst. There was no mention of PTC. We requested for revision of the diagnosis, and the reviewing pathologist reported the case as PTC in a thyroglossal cyst! This emphasizes the role of preoperative USG.

Table 2: Ultrasonographic findings in the thyroglossal cyst with papillary carcinoma

S. NO.	Cystic lesion in the neck	Internal solid mass in the cyst	Micro-calcifications in the internal solid mass	Thyroid echogenicity	Cervical lymphadenopathy	Histopathological Diagnosis
1	Yes	Yes	Yes	Normal	No	Papillary ca in TGC
2	Yes	Yes	Yes	Normal	Yes	Papillary ca in TGC
3	Yes	Yes	Yes	Normal	No	Papillary ca in TGC
4	Yes	Yes	Yes	Normal	No	Papillary ca in TGC
5	Yes	Yes	Yes	Normal	Yes	Papillary ca in TGC
6	Yes	Yes	Yes	Normal	No	Papillary ca in TGC
7	Yes	Yes	Yes	Normal	Yes	Papillary ca in TGC

TGC = thyroglossal cyst, ca = carcinoma

In our series of cases, we observed certain atypical USG imaging features in all the seven cases, which arose suspicion of malignancy. These atypical features were the solid internal globular component associated with multiple tiny echogenic foci (micro calcifications) (Fig. 1 and 2). Enlarged lymph nodes

were observed in three cases. All the seven cases with these findings proved to be papillary thyroid carcinoma on histopathology. As such we suggest that USG may predict the presence of papillary carcinoma in a thyroglossal cyst with these atypical imaging findings.

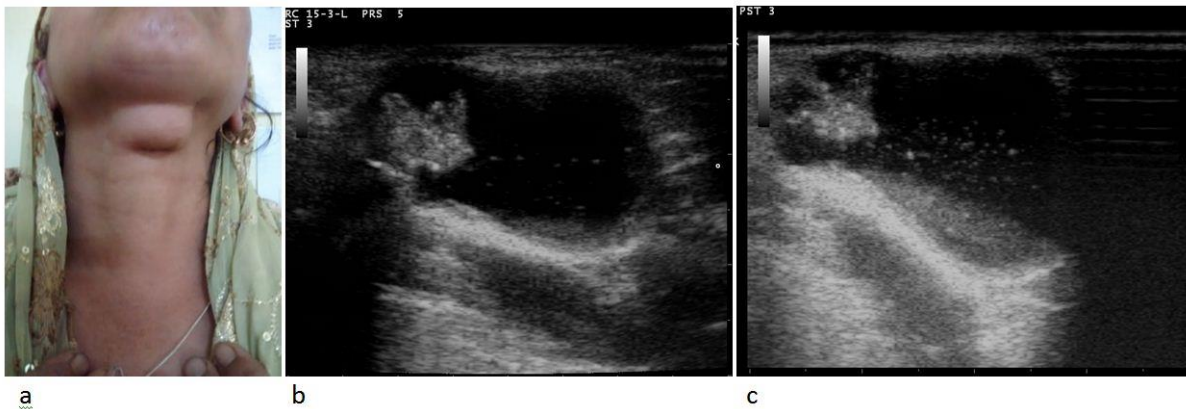


Fig 1: A, Photo of the patient (case 7) showing anterior midline swelling in the upper neck. B, A cystic lesion is seen with presence of a small internal component. C, Note the tiny echogenic foci (micro calcifications) in the internal component. Debris is also seen in the fluid of the cyst.

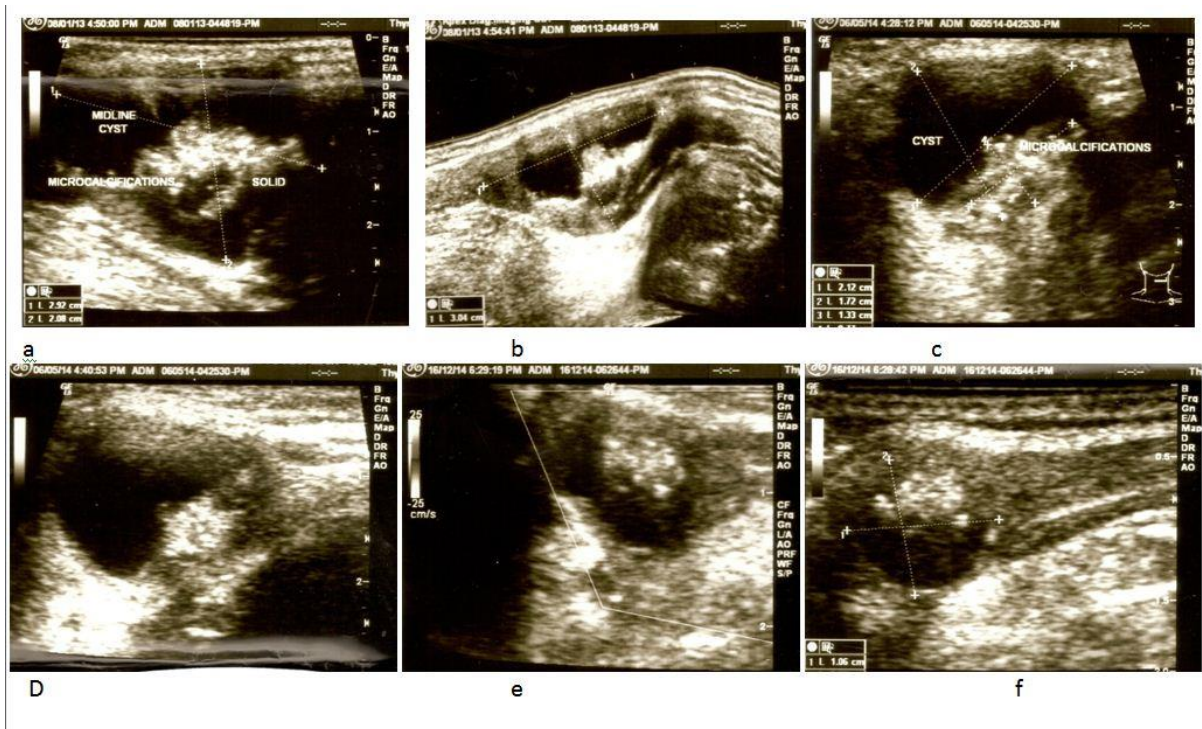


Fig 2: a, solid internal component in a thyroglossal cyst with micro calcifications. b, panoramic view of the same lesion. c and d, another patient with a thyroglossal cyst carcinoma. e and f, another patient with thyroglossal cyst carcinoma

DISCUSSION

Thyroglossal duct cysts develop from persistence of the mid portion of the thyroglossal duct which is an embryonic structure that traces the path of the descent of the thyroid gland. The duct is normally obliterated at around the 8th–10th week of gestation, but if the duct fails to involute completely, the remaining epithelial tissue can develop a thyroglossal cyst (TGC). Previous studies have suggested that this failure to involute occurs in approximately 7% of the population [11]. Typically, TGC manifest as an enlarging, painless, midline neck mass in children or young adults that moves upward with tongue protrusion [12, 13, 14]. Rarely, the cyst may localize to the floor of the mouth [15, 16]. The age ranged between 18 to 50 years. There was a female preponderance seen in our series with a 4:3 female to male gender ratio.

The etiology of the papillary carcinoma arising in a thyroglossal duct cyst is unclear but, generally, there are two theories which can explain this phenomenon, de novo origin and spread from a primary thyroid gland tumor [17]. Most authors support the theory of primary de novo origin by the ectopic thyroid nests of the cyst wall rather than the metastatic spread from a primary thyroid gland tumor through the duct from the thyroid carcinoma. The other theory explains synchronous occurrence of thyroglossal duct cyst carcinoma and thyroid carcinoma, which are reported to

be even rarer, as multifocal tumor [18]. Papillary carcinoma is the most common malignancy in thyroglossal duct cyst (80%), followed by “mixed” papillary-follicular carcinoma (8%) and squamous cell carcinoma (6%). The other 6% include very rare cases of epidermoid, Hürthle cell (oxyphilic), follicular, and anaplastic (undifferentiated) carcinomas [19]. The concomitant occurrence of papillary carcinoma in the thyroid and thyroglossal cyst has also been reported.

Imaging diagnostic techniques, including ultrasound, scintigraphy and CT, are usually unable to preoperatively diagnose malignant disease [20] and fine needle aspiration yields a correct result in only 66% of the cases [21]. The USG in a thyroglossal cyst usually reveals a well defined cystic lesion with anechoic fluid inside. The walls are thin. No internal vascularity is seen. However, in some cases, the internal fluid may contain debris.

Recently Aculate reported a case of Papillary carcinoma in TGC in a 21 year old woman in whom USG showed a predominantly cystic lesion lying between the hyoid and thyroid cartilages with a central solid component. Post operatively histopathological examination showed a small papillary thyroid carcinoma confined to the wall of the cyst [22]. Barton *et al.*; reported that carcinoma should be considered in thyroglossal duct cysts that have a mural nodule or

calcification on CT [23]. We observed that solid internal component and micro calcifications on imaging can predict carcinoma within a thyroglossal duct cyst up to 100% cases.

The role of FNAC in diagnosing papillary carcinoma in thyroglossal duct cyst has been studied. Published literature quotes a true positive rate of 53% and a false negative rate of 47%.16 [24]. In a series of cases reviewed by Bardales *et al.*; preoperative diagnosis of malignancy was made in 56% of cases [25]. Yang *et al.*; attribute the high false-negativity to hypocellularity that results from dilution by the cystic contents. Therefore, it is important to repeat and aspirate any residual solid regions after the cyst has been decompressed [23]. In predominantly cystic lesions, obtaining an ultrasound-guided biopsy specimen from the solid component of the mass is preferable; however, routine FNAC of all TGC, especially in children, may not be cost –effective because of low frequency of occurrence of carcinoma [19].

The prognosis for papillary TGDC is excellent, with occurrence of metastatic disease in less than 2% of cases [26]. There is still controversy regarding the need to remove the thyroid gland in the case of a papillary carcinoma of the TGD. Some authors recommend thyroidectomy in cases where (a) the thyroid gland is found to be nodular, with a cold nodule in a thyroid iodine uptake scan; (b) enlarged lymph nodes are present, or (c) a history of neck irradiation exists [27]. Others add that In the case of large tumors >1 cm, invasion through the duct cyst wall or suspect foci in the thyroid gland, a total thyroidectomy followed by I-131 ablation and thyroid-stimulating hormone suppression should be done [28].

It was concluded that pre-operative USG is a very useful investigation in patients of TGC. It has a very high positive predictive value in the diagnosis of TGDC. It can also detect lymphadenopathy with certainty. Associated thyroid lesions are also evaluated. However TGDC being a very rare entity, a prospective double blinded study with a large number of patients could not be done by us. As such the exact sensitivity and specificity of USG cannot be commented about. Also, many patients with other histological sub types of TGDC were not observed.

Thus USG should be ordered in the routine preoperative workup of patients with thyroglossal cyst. It was also concluded that FNAC should preferably be done under USG guidance, as blind FNAC has a very high false negative rate.

CONCLUSION

Because of the rarity of TGDC, this diagnosis may be missed, drastically affecting the appropriateness of the treatment provided. USG can lead to a preoperative diagnosis of thyroglossal duct carcinoma, as a central solid nodular component within the cyst with micro calcifications. USG is also used to guide the FNAC. USG may also be useful tool in post operative follow up.

REFERENCES:

1. Aghaghazvini L, Mazaher H, Sharifian H, Aghaghazvini S, Assadi S; “Invasive thyroglossal duct cyst papillary carcinoma: a case report,” *Journal of Medical Case Reports*, 2009; 3: 9308.
2. Allard RH; The thyroglossal cyst. *Head and Neck Surgery* 1982; 5(2):134–46.
3. Davenport M; ABC of general surgery in children: lumps and swellings of the head and neck. *British Medical Journal* 1996; 312(7027):368–71
4. Weiss SD, Orlich CC; Primary papillary carcinoma of a thyroglossal duct cyst: report of a case and literature review. *Br J Surg* 1991; 78: 87–89.
5. Luna-Oritz, Hurtado Lopez, Valderrama-Landaeata, Ruiz Vega; Thyroglossal duct cyst with papillary carcinoma: What must be done? *Thyroid* 2004; 14(5).
6. Park M, Yoon J, Jegal Y, Lee J; Papillary thyroglossal duct cyst carcinoma with synchronous occult papillary thyroid microcarcinoma. *Yonsei Med J* 2010; 51(4):609-11.
7. Cherian MP, Nair B, Thomas S, Somanathan T, Sebastian P; Synchronous papillary carcinoma in thyroglossal duct cyst and thyroid gland: Case report and review of literature. *Head Neck* 2009; 31(10):1387-91.
8. Kennedy Thomas L, Whitaker Mark, Wadih George; Thyroglossal duct carcinoma: A rational approach to management. *The Laryngoscope* 1998; 108: 1154-58.
9. Mobini J, Krouse TB, Klinghoffer JF; Squamous cell carcinoma arising in a thyroglossal duct cyst. *Am Surg* 1974; 40: 290-94.
10. Livolsi VA, Perzin KH, Savetsky L; Carcinoma arising in median ectopic thyroid (including thyroglossal duct tissue). *Cancer* 1974; 34: 1303-15.
11. Ellis PD, van Nostrand AW; The applied anatomy of thyroglossal tract remnants. *Laryngoscope* 1977; 87(5 Pt 1):765–70.

12. Telander RL, Deane SA; Thyroglossal and branchial cleft cysts and sinuses. *Surgical Clinics of North America* 1977; 57(4):779–91
13. Davenport M; ABC of general surgery in children: lumps and swellings of the head and neck. *British Medical Journal* 1996; 312(7027):368–71
14. Telander RL, Filston HC; Review of head and neck lesions in infancy and childhood. *Surgical Clinics of North America* 1992; 72(6):1429–47
15. Reede DL, Bergeron RT, Som PM; CT of thyroglossal duct cysts. *Radiology* 1985; 157(1):121–5 [Epub 1985/10/01].
16. Dolata J; Thyroglossal duct cyst in the mouth floor: an unusual location. *Otolaryngology: Head and Neck Surgery* 1994; 110(6):580–3
17. Balalaa N, Megahed M, Al Ashari M, Branicki F; “Thyroglossal duct cyst papillary carcinoma,” *Case Reports in Oncology*, 2011; 4(1):39–43.
18. Pribitkin EA, Friedman O; “Papillary carcinoma in a thyroglossal duct remnant,” *Archives of Otolaryngology: Head and Neck Surgery*, 2002; 128(4):461–462.
19. Heshmati, Hassan M, Fatourehchi, Vahab, van Heerden, Joy A, Hay, Ian D Goellner, John R; Thyroglossal duct carcinoma : Report of 12 cases; *Mayo Clinic Proceedings*; 1997;72(4): 315-319.
20. Martin-Perez E, Larranaga E, Marron C, Monje F; Primary papillary carcinoma arising in a thyroglossal duct cyst. *European Journal of Surgery* 1997; 163(2):143–5
21. Bardales RH, Suhrland MJ, Korourian S, Schaefer RF, Hanna EY, Stanley MW; Cytologic findings in thyroglossal duct carcinoma. *American Journal of Clinical Pathology* 1996; 106(5):615–9
22. Aculate N.R, Jones H.B, Bansal A, Hoa M.W; Papillary carcinoma within a thyroglossal duct cyst: significance of a central solid component on ultrasound imaging. *Br J Oral Maxillofac Surg.* 2014; 52(3): 277–278.
23. Barton F, Branstetter, Jane L Weissman, Thomas L Kennedy, Whitaker Mark; The CT appearance of thyroglossal duct carcinoma. *AJNR Am J Neuroradiol.* 2000; 21:1547-50.
24. Yang YJ, Hagher S, Wanamaker JR, Powers CN; Diagnosis of papillary carcinoma in a thyroglossal duct cyst by fine-needle aspiration biopsy. *Arch Pathol Lab Med* 2000; 124: 139-42.
25. Bardales RH, Suhrland MJ, Korourian S, Schaefer RF, Hanna EY, Stanley MW; Cytologic findings in thyroglossal duct carcinoma. *Am J Clin Pathol.* 1996; 106: 615-19.
26. Park M, Yoon J, Jegal Y, Lee J; Papillary thyroglossal duct cyst carcinoma with synchronous occult papillary thyroid microcarcinoma. *Yonsei Med J* 2010; 51(4):609-11.
27. Dedivitis RA, Guimarães AV; Papillary thyroid carcinoma in thyroglossal duct cyst. *Int Surg* 2000; 85:198–201.
28. Kristensen S, Juul A, Moesner J; Thyroglossal duct carcinoma. *J Laryngol Otol* 1984; 98:1277–1280.