

Original Research Article

Surgical management of displaced fractures of the neck of the radius in children: open reduction and temporary internal fixation in whom closed reduction has failed: A prospective study

Dr. Balaji. B¹, Dr. K. Venkatachalam², Dr. Hitesh Bhandari¹

¹Final year M.S. Ortho PG, ²Professor

Department of Orthopaedics, Sree Balaji Medical College and Hospital, No.7, Works Road, New Colony, Chromepet, Chennai – 600044, Tamil nadu, India.

***Corresponding author**

Dr. Balaji. B

Email: sairam137@yahoo.co.in

Abstract: Pediatric radial neck fractures account for 5 to 10% of all elbow fractures. The treatment of radial neck fractures in children varies according to the displacement, angulation, and skeletal maturity. Open reduction is advocated for comminuted fractures and cases where closed reduction has failed. Thus open reduction and temporary internal fixation of pediatric radial neck fractures have to be chosen selectively for apt indications. This study includes 22 children with fractures of the radial neck who were treated at SBMCH, Chromepet between January 2010 and December 2015. Fractures were classified according to the classification system described by Judet et al. The patients are evaluated using MEPS score and radiographs at 8-12 weeks and at 6 months. The patients were followed 12 - 60 months [mean of 24 months]. According to MEPS score 7 [31.81%] had excellent results, 7[31.81%] had good outcomes and 8[36.38%] had fair to poor outcomes. Post op neck angle was excellent to good in 14 [63.64%] and fair to poor in 8[36.37%] patients. Our study established that contrary to other literature, that good results can be obtained in carefully selected cases with gentle manipulative surgery. Younger the age group and earlier the case taken up for surgery better are the functional outcome.

Keywords: Pediatric radial neck fractures, fractures in children, open reduction and temporary internal fixation.

INTRODUCTION:

Pediatric radial neck fractures account for 5 to 10% of all elbow fractures [1, 2]. The site of fracture in childhood is either through physis with a metaphyseal fragment [Type II Salter Harris] or through the neck proper [3-4mm distal to the epiphyseal plate]. 90% of the fractures are of the Type II Salter – Harris. In children, proximal radial epiphysis is cartilagenous and is more prone to fracture than the hard articular surface of the radial head. The fractures may have angulation or lateral translation of the radial head to a variable degree. These types of fractures occur after the ossification centre of the proximal radius epiphysis appears [about the age of 10 years]. The treatment of radial neck fractures in children varies according to the displacement, angulation, and skeletal maturity. Open reduction is advocated for comminuted fractures and cases where closed reduction has failed. The purpose of this prospective study is to evaluate the outcome of open reduction and temporary internal fixation of pediatric radial neck fractures with proper indication. Most fractures are undisplaced or minimally displaced [Judet type I and II fractures] and can be treated

conservatively with closed reduction and cast application with good outcome [3]. However displaced radial neck fractures with more than 30° angulations [Judet type III and IV fractures] should be surgically treated [4, 5]. There are several surgical interventions for Judet type III and IV fractures, which include elastic stable intramedullary nailing [ESIN] [6], percutaneous pin reduction [7] and open reduction with or without internal fixation [8]. Open reduction of radial neck fractures are best avoided due to poor functional outcome and higher rates of complications. Only in cases where closed reduction has failed or when the fracture is comminuted, open reduction is pursued. Open reduction has been found to be associated with a greater loss of motion, increased rates of osteonecrosis and synostosis. This prospective study aims to evaluate the outcome of open reduction and temporary internal fixation of pediatric radial neck fractures in which initial closed reduction had failed.

MATERIALS AND METHODS:

This study includes 22 children with fractures of the radial neck fracture who were treated at SBMCH,

Chromept between January 2010 and December 2015 [60 months of patient recruitment].The study was conduced in March 2017, so that atleast there was a

minimum follow up period was 14 months. Fractures were classified according to the classification system described by Judet *et al.*;

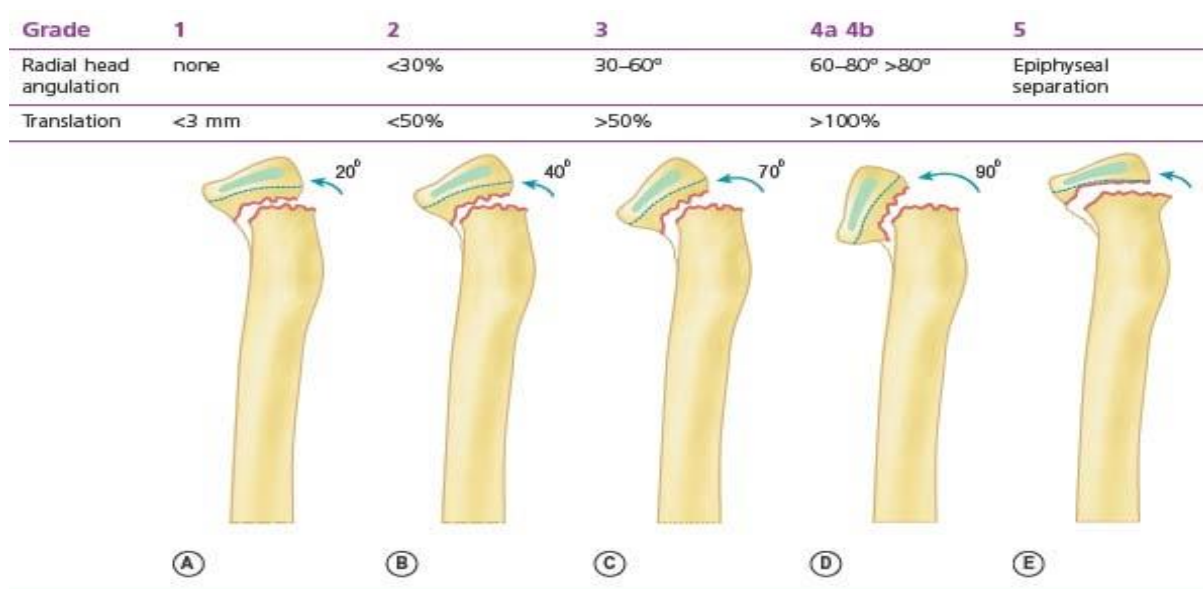


Fig 1: Judet *et al.*; classification of radial neck fractures.

Inclusion criteria:

- Closed fractures.
- Displaced radial neck fracture with an angulation of more than 30° [All are Judet type-3 and type-4] in children with open physeal plates [6-16 years] in whom closed surgical method has failed.
- The time from injury to surgery ranged from 1day to 10days.

Exclusion Criteria:

- Judet type 1 and 2 fractures.
- Open fractures.
- Fractures older than 10 days.

All children were initially tried by closed method and had not achieved acceptable reduction. The open reduction was performed through posterolateral approach for elbow (Kocher approach). The fracture

was reduced under vision and fixed with 1.5mm smooth single K-wire. In five patients two K-wires had to be used. All K-wires were passed from the proximal fragment to distal metaphyseal or diaphyseal cortex without crossing the capitulum. The K-wire was left protruding out of the skin and was bent over to prevent migration. A long arm cast with the forearm in a neutral position was applied for 21 days. Five associated olecranon fractures were treated by closed reduction and fixation with dual percutaneous k-wires. All children were evaluated clinically and radiologically at the end of 8 and 12 weeks, and thereafter at 6 monthly intervals. The follow- up period ranged from 14 to 60 months, with a mean of 24 months. The patients were evaluated for range of motion [ROM], radiological evaluation of alignment, functional results using the Mayo elbow performance score [MEPS] [Fig.2], and early or late complications.

MAYO ELBOW PERFORMANCE SCORE

Adapted from: Gill DR, JBJS 1998;80A:1327

Criteria	Points	Patient Score
Pain (45 points)		
None	45	= 45
Mild	30	
Moderate	15	
Severe	0	
ROM		
>100 degrees	20	= 20
50-100 degrees	15	
<50 degree	5	
Stability (10 points)		
Stable	10	= 10
Moderate instability	5	
Gross instability	0	
Daily function (25 points)		
Combing hair	5	= 25
Feeding oneself	5	
Hygiene	5	
Putting on shirt	5	
Putting on shoes	5	
Patient Score= 100		

> 90 points = excellent, 75 to 89 points = good, 60 to 74 points = fair, and less than 60 points = poor
 Stable = no apparent varus-valgus laxity clinically, moderate instability = less than 10 degrees of varus-valgus laxity, and gross instability = at least 10 degrees of varus-valgus laxity.

Fig 2: Mayo elbow performance score.

RESULTS:

Table 1: Association between Post op neck angle and MEPS SCORE among total patients

Post op neck angle	MEPS SCORE				Total
	poor	fair	good	excellent	
Poor	2	0	0	0	2
fair	1	1	0	0	2
Good	0	0	3	3	6
excellent	0	4	4	4	12
total	3	5	7	7	22

Flexion and extension of elbow, pronation and supination of the forearm and the angle of the extended elbows were measured by using a goniometer. Radial

head angulation was measured by the angle between the perpendicular of the axis of the displaced radial epiphysis and the long axis of the radial shaft.

Table 2: Radiological criteria for healed radial neck fractures

Radial head angulation	Assesment criteria
Anatomical	excellent
>20 degree	Good
20-40 degree	Fair
>40 degree	poor

The joint's stability was graded as stable, mildly unstable or unstable. The functional score is determined on the basis of the patient's ability to perform normal activities of daily living. The total score ranges from 5 to 100 points, with higher scores

indicating better function. If the total score is between 90 and 100 points, it can be considered excellent outcome; between 75 and 89 points is good; between 60 and 74 points is fair and less than 60 points is poor.

Table 3: Sex distribution of Patients

Gender	N	%
Male	16	72.73
Female	6	27.27
Total	22	100 %

In this study of all 22 patients, 16[72.73%] were males and 6[27.27%] were females.

Table 4: Age distribution of Patients

Age in years	Male	Female	Total	% in age
6-8	2	1	3	13.63
8-10	2	0	2	9.10
10-12	3	2	5	22.72
12-14	3	1	4	18.19
14-16	6	2	8	36.36
Total	16	6	22	100

In this study Mean age was 13 in males and 11 in females with 12 being the total mean.

Table 5: Distribution of Post op neck angle and MEPS SCORE

Results	Post op neck angle		MEPS SCORE	
	N	%	N	%
Excellent	12	54.55	7	31.81
Good	6	27.27	7	31.81
Fair	2	9.09	5	22.73
Poor	2	9.09	3	13.65
Total	22	100	22	100

Table 6: Correlation between timing of surgery and MEPS score.

Days elapsed after injury	MEPS SCORE				total	% in age
	Excellent	Good	Fair	poor		
1-2	5	6			11	50
3-4	2	1			3	13.64
5-6			4		4	18.18
7-8			1	1	2	9.09
9-10				2	2	9.09
Total	7	7	5	3	22	100

Table 7: Age vs. MEPS score

Age in years	MEPS SCORE				N
	Excellent	Good	Fair	Poor	
6-8	2	1	0	0	3
8-10	1	1	0	0	2
10-12	2	1	1	1	5
12-14	2	0	1	1	4
14-16	2	2	2	2	8
Total	9	5	4	4	22
% age	40.92	22.72	18.18	18.18	100%

Illustrative case 1 – Showing excellent functional outcome

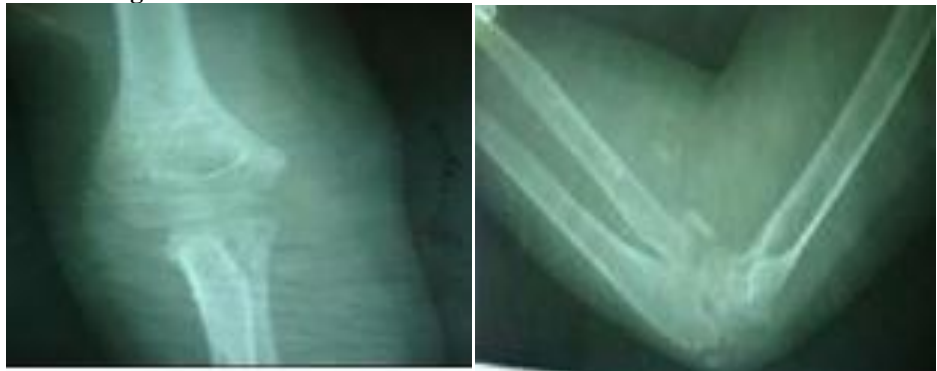

Fig 3: Pre op X Ray AP view and Lateral view

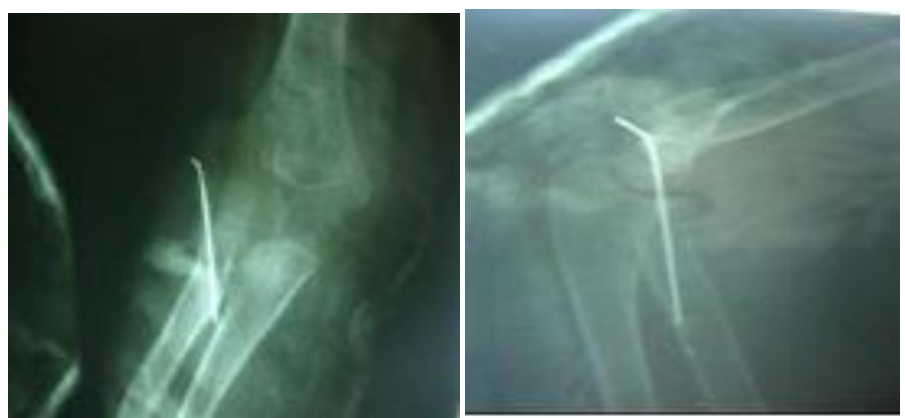

Fig 4: Post op X Ray AP & Lateral images.

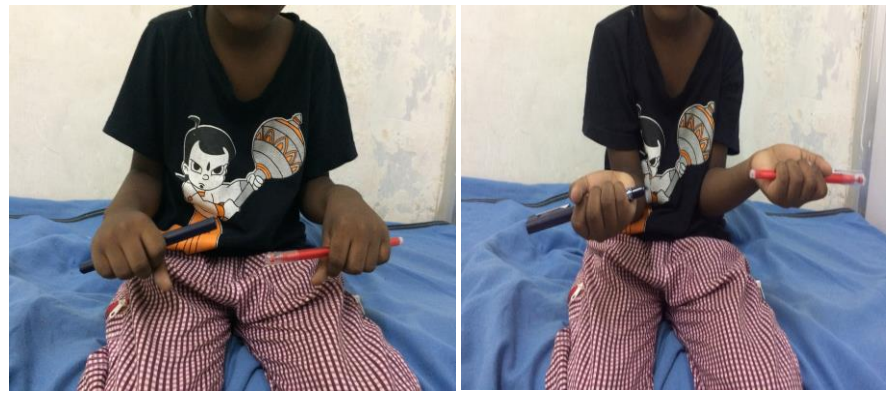

Fig 5: Clinical picture showing good outcome.

Illustrative Case 2: Showing poor functional outcome.

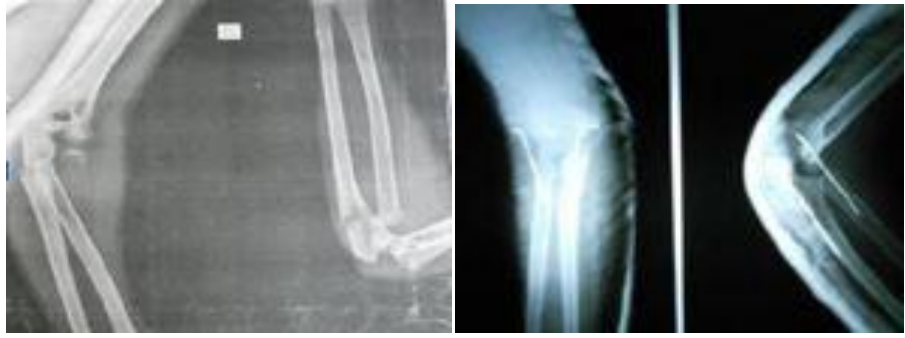

Fig 6: Pre op X ray

Post op X Ray

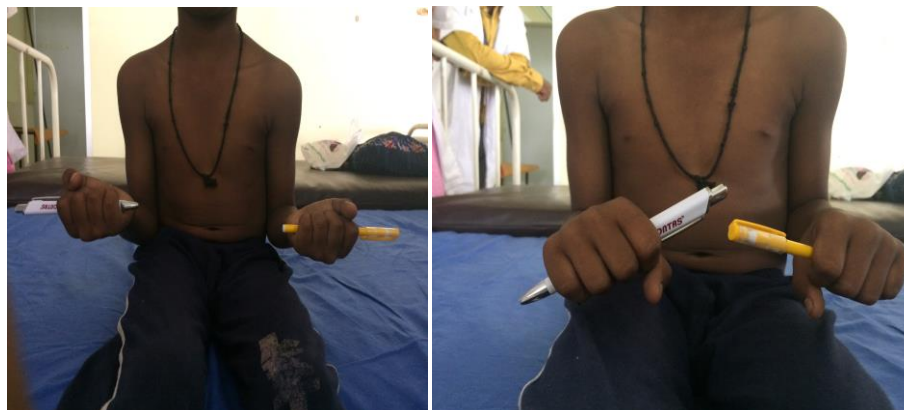

Fig 7: Clinical picture showing poor outcome. Note the limitation of pronation on the right side.

DISCUSSION:

Our conclusions are in disagreement with the majority of authors and widely reported literature that open reduction leads to unfavourable outcomes [1-4]. In our series based on the clinical evaluation criteria presented, there are 9 (40.92%) excellent, 5(22.72%) good, 4 (18.18%) fair and 4 (18.18%) poor results. Different authors have reported vast range of poor outcome following ORIF, with only excellent outcome in 50% [12], 42% [13], and 38% [14] cases. Almost half the treated patient had an excellent outcome, indicating that in carefully selected cases outcome may be acceptable. Less invasive closed reduction methods must precede before open reduction. The open Reduction method of treatment is associated with high incidence of complications like, avascular necrosis, proximal synostosis, heterotopic ossification, infection, premature physal closure, radial head overgrowth and loss of ROM. These instances are higher than after closed reduction [5, 2, 4, 10]. Some radial neck fractures, in particular severely displaced, are impossible to reduce with closed method and require open reduction [6-8]. Open reduction is inevitable in cases of comminuted fractures, interposition of the capsule or of the annular ligament between the head and the neck, totally displaced, and fracture dislocation [9].

The factors which influence the final outcome of the radial neck fracture are age of the child, greater initial fracture displacement, delay in surgery, associated injuries, open treatment and residual angulation may contribute to poor outcomes. In our study it was clearly established that cases undertaken for surgery within 2 days had a 50% excellent outcome. Delay in operating adversely reflects the functional outcome. Age is also a good predictor for the long-term result. The remodelling process varies with the age of the patient. The young children have greater remodelling potential and hence greater degrees of residual angulation can be accepted [11]. However, the proximal physis of the radius is responsible for only 20–30% of the growth of the radius and therefore

spontaneous fracture remodelling is restricted. In our study in the age group 6-10 years all 5 patients had excellent or good outcomes. But in the age group of 10-14 years only 5 out of 9 patients had excellent to good results. In the age group 14-16 year 4 out of 8 patients had excellent to good results. In our study a residual angulation of 35 degree after closed reduction was considered acceptable, angle greater than 35 degree were considered as indication for open reduction internal fixation. In most published studies, concomitant injuries were associated with unfavourable results [1, 11, 14]. In our series two patients who had olecranon fracture and both had poor outcomes.

CONCLUSION:

In the management of paediatric radial neck fracture open reduction and internal fixation should be reserved for cases of residual angle more than 35 degree or with gross comminution. Our study established that contrary to other literature good results can be obtained in carefully selected cases with gentle manipulative surgery. Younger the age group and earlier the case taken up for surgery, better are the functional outcome.

REFERENCES:

1. Steele JA, Graham HK. Angulated radial neck fractures in children. A prospective study of percutaneous reduction. *Bone & Joint Journal*. 1992 Sep 1; 74(5):760-4.
2. Waters PM, Stewart SL. Radial neck fracture non-union in children. *Journal of Pediatric Orthopaedics*. 2001 Sep 1; 21(5):570-6.
3. Métaizeau JP. Reduction and osteosynthesis of radial neck fractures in children by centro medullary pinning. *Injury*. 2005 Feb 28; 36(1):S75-7.
4. Tibone JE, Stoltz M. Fractures of the radial head and neck in children. *J Bone Joint Surg Am*. 1981 Jan 1; 63(1):100-6.
5. Newman JH. Displaced radial neck fractures in children. *Injury*. 1977 Nov 1; 9(2):114-21.
6. Fowles JV, Kassab MT. Observations concerning

- radial neck fractures in children. *Journal of Pediatric Orthopaedics*. 1986 Jan 1; 6(1):57.
7. Steinberg EL, Golomb D, Salama R, Wientroub S. Radial head and neck fractures in children. *Journal of Pediatric Orthopaedics*. 1988 Jan 1; 8(1):35-40.
 8. Pesudo JV, Aracil J, Barcelo M. Leverage method in displaced fractures of the radial neck in children. *Clinical orthopaedics and related research*. 1982 Sep 1; 169:215-8.
 9. Schmittenbecher PP, Haevernick B, Herold A, Knorr P, Schmid E. Treatment decision, method of osteosynthesis, and outcome in radial neck fractures in children: a multicenter study. *Journal of Pediatric Orthopaedics*. 2005 Jan 1; 25(1):45-50.
 10. Steele JA, Graham HK. Angulated radial neck fractures in children. A prospective study of percutaneous reduction. *Bone & Joint Journal*. 1992 Sep 1; 74(5):760-4.
 11. Metaizeau JP, Lascombes P, Lemelle JL, Finlayson D, Prevot J. Reduction and fixation of displaced radial neck fractures by closed intramedullary pinning. *Journal of Pediatric Orthopaedics*. 1993 May 1; 13(3):355-60.
 12. Vocke AK, Von Laer L. Displaced fractures of the radial neck in children: long-term results and prognosis of conservative treatment. *Journal of Pediatric Orthopaedics B*. 1998 Jul 1; 7(3):217-22.
 13. Steinberg EL, Golomb D, Salama R, Wientroub S. Radial head and neck fractures in children. *Journal of Pediatric Orthopaedics*. 1988 Jan 1; 8(1):35-40.
 14. Vahvanen V, Gripenberc L. Fracture of the radial neck in children: a long-term follow-up study of 43 cases. *Acta Orthopaedica Scandinavica*. 1978 Jan 1; 49(1):32-8.