

## Case Report

**Giant Median Nerve Schwannoma: A Case Report**

Youssef Elbir\*<sup>1</sup>, Monsef Bofettal, Imad Elghordaf<sup>1</sup>, Yassine Sedrati<sup>1</sup>, Karim Bennani<sup>1</sup>, Rida-Allah Bassir<sup>1</sup>, Ahmed El Bardouni<sup>1</sup>, Mohamed S Berrada<sup>1</sup>, Faiza Arab<sup>2</sup>, Hanane lamine<sup>2</sup>, Jawad Tadili<sup>2</sup>, Ali kettani<sup>2</sup>, Mamoun Faroudy<sup>2</sup>

<sup>1</sup>Orthopedic surgery department of Ibn Sina hospital, University Mohamed V, Rabat, Morocco

<sup>2</sup>Anesthesia reanimation surgical department of Ibn Sina hospital RUCH, University Mohamed V, Rabat, Morocco

**\*Corresponding author**

Youssef Elbir

Email: [elbir.youssef3@gmail.com](mailto:elbir.youssef3@gmail.com)

**Abstract:** Schwannoma is the most common benign tumor of peripheral nerve. Only 7% of schwannomas arise from the median nerve. It usually presents solitary swelling along the course of the nerve however multiple lesions may be present in cases of NF type 1. Schwannoma is generally presented as an asymptomatic mass. Discomfort may be the only complaint of the patient. EMG, MRI, and USG are helpful in the diagnosis. Surgical removal is usually curative.

**Keywords:** Schwannoma, tumor, peripheral nerve.

**INTRODUCTION**

Schwannoma is known as neurilemmoma, first described by Verocay in 1908, is an encapsulated Neoplasm, which arises from Schwann cells in the peripheral nerve sheaths [3, 15].

It is the most common primary solitary tumour among peripheral nerve tumour [7]. Schwannoma usually grow slowly and appear as painless swellings for several years before being Diagnosed. EMG (electromyography), MRI (magnetic resonance imaging), and USG (ultrasonography) are helpful in the diagnosis. Surgical removal is usually curative. We report an unusual case of giant schwannoma of the median nerve.

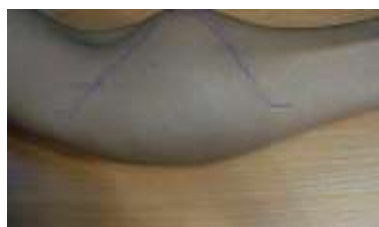**CASE REPORT**

34 years old Moroccan male, was admitted with a twenty four months history of soft tissue

swelling at the left forearm. He initially noticed a small swelling on the left forearm which eventually increased in size, associated to numbness present only for the last 6 months.

There was no family history of neurofibromatosis and no associated clinical features. No history of significant trauma was recalled.

In physical examination a 8 cm × 4 cm non tender, Firm swelling located on the volar side of the proximal third of the left forearm (Figure 1). Mobility restricted in both directions. No cutaneous pigmented lesions were found. There were no concomitant paresthesias or loss of strength in the territory of the median nerve. Percussion over the mass produced Tinel's like sensation along the median nerve.



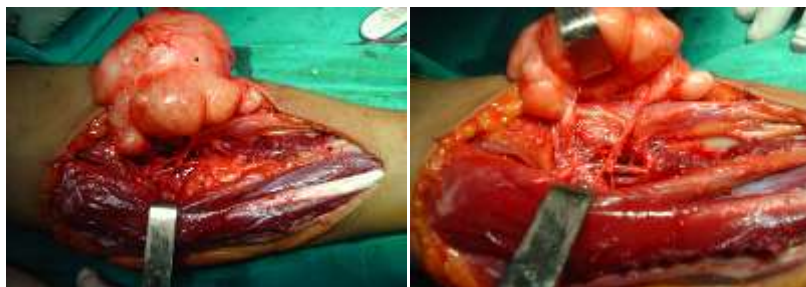
**Fig-1: Mass on the volar side of the left forearm**

Routine laboratory data was normal, including complete blood count, renal and liver function tests. Erythrocyte sedimentation rate (ESR) was 33. Radiology and electromyography (EMG) were normal.

The ultrasound showed that the mass was subcutaneous although limited and homogeneous measuring 9 cm in diameter. The patient refused to undergo MRI examination due to economy reasons.

The appearance was compatible with a tumor of nervous origin. Biopsy was performed and histological examination showed the characteristic pattern of schwannoma.

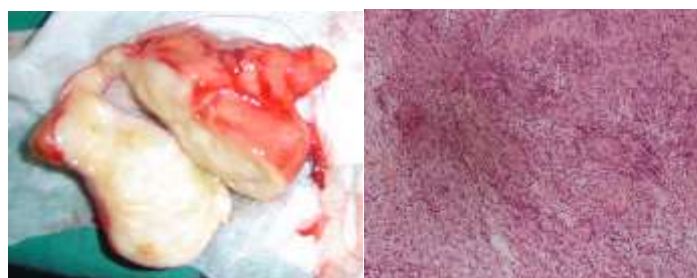
A longitudinal incision centered over the tumor bulk was performed. Surgical exploration brought to light an encapsulated tumor firmly attached to the median nerve, which was easily resected (Figure 2).



**Fig-2: Intraoperative view of the lesion showing that the mass at the forearm was originated from the median nerve**

Histological examination of the tumoral structure confirmed the diagnosis of benign schwannoma (Figure 3). The post-operative period was uneventful and the patient did very well.

Long-term 48 months follow-up revealed no recurrence of the tumor and full resolution of his preoperative symptoms (Figure 4).



**Fig-3: Histopathology of the mass**



**Fig-4: Patient at 48 months follows up**

## DISCUSSION

Schwannomas are rare tumours, but they are the most common primary neural tumours of the upper limb and account for less than 5%. They mostly located on its volar surface. 75% of schwannoma of the upper extremity occur at elbow or distal to it, only 7% arise from the median nerve [2, 5, 7].

Typically, the tumor appears between the second and fifth decades of life, with no racial and gender difference. They are usually 2.5cms in size but may grow up to 4-5 cms, and appear generally as solitary lesions. The incidence of multiple schwannomas has been reported as 1% to 23% [2, 4, 9].

The reported interval between onset of symptoms and surgery has varied from a few months to years [7].

The symptoms of schwannomas are nonspecific and can mimic those of any type of soft-tissue mass. Patients most frequently notice a painless mass, but less commonly there may be a neurologic deficit. Palpation or compression of the lesion may produce radiating pain in a specific nerve distribution [5, 8, 12].

On MRI, gadolinium enhanced T1-weighted and T2-weighted MRIs are particularly useful in

diagnosing schwannomas. MRI can provide useful information about morphological data on the median nerve tumours. However, it cannot provide dynamic information [4]. Conversely, Ultrasonography gives detailed informative images during static and dynamic positions such as flexion and extension maneuvers, showing the nerve in relation to the surrounding musculotendinous structures. Schwannomas appear as sharply delineated, hypoechoic, and homogenous masses with posterior acoustic enhancement sonographically [7, 12, 15].

EMG studies may reveal prolonged sensory latency and diminished or absent sensory-evoked potentials. The risk of malignant transformation being approximated at 18% in neurofibromatosis type 1 and 5% in schwannomas [1, 7].

Complete excision of the mass remains the gold-standard treatment for the disease. Although recurrence is rare, some relapses have been reported in the Literature [12, 15].

Paresthesia is the most frequently reported postoperative complication [3]. The surgeon must resect fascicular groups without penetrating them, thus allowing their enucleation while preserving nerve continuity. Avoiding unnecessary sacrifice of functionally motor and sensory branches.

## CONCLUSION

Schwannomas are rare peripheral nerve tumors that have important diagnostic and radiographic features. Awareness, thorough history taking, and physical examination are important in a correct diagnosis of schwannomas. Surgical resection is associated with good outcomes. The recurrence rate is low.

## REFERENCES:

1. Gundes H, Tosun B, Muezzinoglu B, Alici T. A very large Schwannoma originating from the median nerve in carpal tunnel. *J Peripher Nerv Syst.* 2004;9:190–2.
2. Bhatti AM, Alo GO, Power DM, Masood A, Thuse HG. Lobulated schwannoma of the median nerve: pitfalls in diagnostic imaging. *J Comput Assist Tomogr.* 2005;29:330–2.
3. Dr. N. Mariappan. Ancient schwannoma of the median nerve: a case report and review of the literature of nerve tumors. *IOSR Journal of Dental and Medical Sciences (IOSR-JDMS).* 2014; 13(12): 10-17.
4. Ahlawat S, Chhabra A, Blakely J. Magnetic Resonance Neurography of Peripheral Nerve Tumors and Tumorlike Conditions. *Neuroimag Clin N Am.* 2014; 24: 171-192
5. Aslam N, Kerr G. Multiple schwannomas of the median nerve: a case report and literature review. *Hand Surgery.* 2003; 8(2):249–252.
6. Rekha A, Ravi A. Sciatic nerve schwannoma. *Int J Low Extrem Wounds.* 2004;3:165–7.
7. Ogoose A, Hotta T, Morita T. Tumors of peripheral nerves: correlation of symptoms, clinical signs, imaging features, and histologic diagnosis. *Skeletal Radiol.* 1999;28:183–8.
8. MacDonell RAL, Schwartz MS, Swash M. Carpal tunnel syndrome: which finger should be tested? An analysis sensory conduction in digital branches of the median nerve. *Muscle Nerve.* 1990;13:601–6.
9. Omezzine SJ, Zaara B, Ben Ali M, Abid F, Sassi N, Hamza HA. A rare cause of chronic sciatic pain: schwannoma of the sciatic nerve. *J Clin Orthop Trauma.* 2013;4:89–92.
10. Lamond RC, Fox B. Management of peripheral nerve tumors. *Limb Preservation.* 2004;11:1–4.
11. Thiebot J, Laissy JR, Delangre T, Biga N, Liotard A. Benign solitary neurinomas of the sciatic popliteal nerves CT study. *Neuroradiology.* 1991;33:186–8.
12. Kim SM, Seo SW, Lee JY, Sung KS. Surgical outcome of schwannomas arising from major peripheral nerves in the lower limb. *Int Orthop.* 2012;36:1721–5.
13. Gonzalvo A, Fowler A, Cook RJ, Little NS, Wheeler H, McDonald KL. Schwannomatosis, sporadic schwannomatosis, and familial schwannomatosis: A surgical series with long-term follow-up. *Clinical article. J Neurosurg.* 2011;114:756-62.
14. Kütahya H, Güleç A, Güzel Y, Kacira B, Toker S. Schwannoma of the median nerve at the wrist and Palmar Regions of the Hand: a Rare Case Report. *Case reports in orthopedics,* 2013.
15. Sandberg K, Nilsson J, Sjøe Nielsen N, Dahlin LB. Tumours of peripheral nerves in the upper extremity: A 22-year epidemiological study. *Scand J Plast Reconstr Surg Hand Surg.* 2009;43:43-9.