

Unusual Complication of Central Venous Catheterization: A Left Internal Jugular Vein Catheter Malposition into the Right Subclavian Vein

Ismail Aissa^{1*}, Aziz Benakrout¹, Mustapha Bensghir¹, Hicham Balkhi¹

¹Department of Anesthesiology and Intensive Care, Military Hospital Mohammed V, Faculty of Medicine and Pharmacy of Rabat, Mohammed V University, Rabat, Morocco

DOI: <https://doi.org/10.36347/sasjm.2024.v10i11.007>

| Received: 07.10.2024 | Accepted: 11.11.2024 | Published: 14.11.2024

*Corresponding author: Ismail Aissa

Department of Anesthesiology and Intensive Care, Military Hospital Mohammed V, Faculty of Medicine and Pharmacy of Rabat, Mohammed V University, Rabat, Morocco

Abstract

Case Report

Most frequently central venous catheterisation complications described in literature are: haematoma at the insertion site, pneumothorax, arterial puncture, thrombosis and infection. We report a case of 56-year-old man with giant liposarcoma of the thigh undergoing a hip disarticulation procedure who presented an unusual complication of central venous catheterization of the left internal jugular vein which is malposition on the subclavian vein of contralateral side. We discuss possible mechanisms, associated risks, and the means to prevent such complication.

Keywords: Central Venous Catheterization, Malposition, Subclavian Vein, Complications, Internal Jugular Vein.

Copyright © 2024 The Author(s): This is an open-access article distributed under the terms of the Creative Commons Attribution 4.0 International License (CC BY-NC 4.0) which permits unrestricted use, distribution, and reproduction in any medium for non-commercial use provided the original author and source are credited.

INTRODUCTION

Central venous catheterisation (CVC) is common practice in the management of serious patients and in some cases in the perioperative period, for the interest of; monitoring central venous pressure (CVP), administering vasoactive amines or certain irritant or hypertonic products, fluid resuscitation and sometimes because of the impossibility of finding peripheral venous access [1]. Catheterisation of the internal jugular vein (IJV) is usually quick and easy, however lack of time, resources and/or experience can sometimes lead to blind insertion of the CVC, resulting in one or more complications. The most frequently described complications are: haematoma at the insertion site, pneumothorax, arterial puncture, thrombosis and infection [2, 3]. Through the observation of an unusual complication of a left IJV catheterisation, which is subclavian migration on the contralateral side, we discuss the possible mechanisms of this malposition, the associated risks, and the means of prevention.

CASE REPORT

A 56-year-old man was treated for giant liposarcoma of the thigh with liver metastasis undergoing chemotherapy. The course was marked by a significant increase in tumor size, invasion of the skin and signs of bacterial superinfection. The patient was

admitted to the oncology department for local care and antibiotic therapy, but did not improve significantly, which led to the indication of hip disarticulation. In the operating room a CVC was indicated for fluid resuscitation and possible use of vasoactive amines. A blind cannulation of the left IJV was performed with a 7 Fr triple lumen catheter using surface anatomical landmarks according to the Seldinger technique. Although venipuncture was easy, the progress of the *metallic guidewire* was hampered after about 10 cm by some kind of obstacle on which it stumbled but without preventing progress. The catheter was inserted through the guidewire without incident. After checking for blood reflux and purging all the channels of air, the CVC was fixed at 16 cm. The surgical procedure was laboriously performed over a period of three hours. The patient experienced haemodynamic instability, which was controlled by blood transfusion and the use of vasoactive amines. She was then transferred to intensive care unit for postoperative management. The clinical evolution was favorable with timely extubation and haemodynamic stabilisation. A post-extubation chest X-ray revealed malposition of the CVC tip in the right subclavian vein (SCV) next to the chemotherapy catheter (Figure 1). It was then carefully removed without incident. After 24 hours, the patient was transferred back to her original department.

Citation: Ismail Aissa, Aziz Benakrout, Mustapha Bensghir, Hicham Balkhi. Unusual Complication of Central Venous Catheterization: A Left Internal Jugular Vein Catheter Malposition into the Right Subclavian Vein. SAS J Med, 2024 Nov 10(11): 1334-1337.

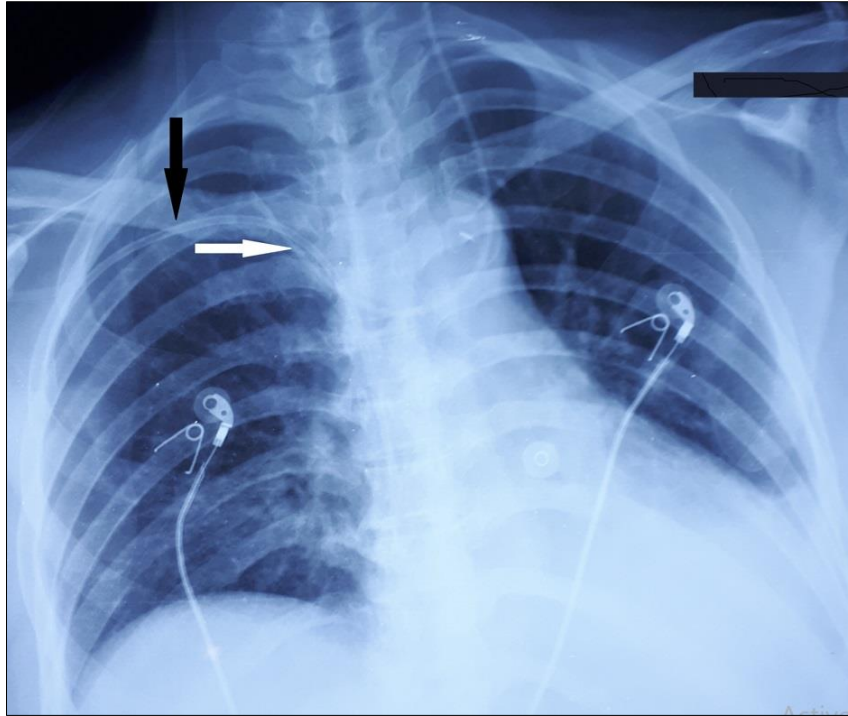


Figure 1: Chest X-ray showing malposition of the left internal jugular catheter tip in the right subclavian vein next to the chemotherapy catheter.

DISCUSSION

Practitioners often prefer cannulation of the right IJV to the left for several reasons: this vein offers a relatively straight path to the superior vena cava (SVC), while the left IJV joins the left SVC at an almost right angle, in addition the left pulmonary dome is higher than that on the right which increases the risk of pneumothorax, and finally cannulation of the left IJV increases the risk of injury to the thoracic duct [1]. Nevertheless, we chose the left IJV to avoid any possible interaction with the chemotherapy catheter in the right SCV.

When cannulating the IJV, the literature recommends having the tip of the CVC at the point of union of the SVC and right atrium (RA); this position is located approximately in the second intercostal space [1]. The length of catheter required can be estimated by placing it on the chest. McGee WT *et al.*, 1993 have shown that catheter insertion to a depth of 16.5 cm is optimal for adults of medium length [4]. In our patient it was inserted and fixed at 16 cm.

CVC malposition is relatively uncommon (5.01%) [5], it may occur at the time of insertion or at any time later. Their location may be intravascular or occasionally extravascular. Some malpositions go unnoticed or are diagnosed late, while others are associated with serious consequences. Malpositions in the VSC increase risks of venous dysfunctions and/or thrombosis [6, 7].

Incidence of this type of complication depends on various factors such as experience of the operator, the

approach chosen and the type of vein cannulated [8], as well as some anatomical factors such as acute angulation of vessels, tortuosity and venous stenosis [9]. Several theories have been put forward to explain the mechanisms of CVC malposition; the catheter tip sometimes does not end at the desired level, which may facilitate the subsequent occurrence of malposition spontaneously or secondary to pressure changes in the thoracic cavity caused by coughing, sneezing, breathing or weight lifting [10]. A too high perfusion rate can also cause the tip to migrate.

Catheter migration from the left IJV to the right CSV is an unusual complication rarely described in the literature, probably because this vein is much less cannulated than the right one. In our patient, this complication could be explained by the presence of the chemotherapy catheter in the CSV, on which the metal guidewire initially came up against at the level of CSV and then changed direction towards the right CSV.

A good knowledge of vascular anatomy is necessary for correct positioning of the CVC. Ultrasound (US) guidance has shown effectiveness in reducing the rate of complications during CVC insertion [11]. Nevertheless, malposition of CVC tip is not completely avoidable, either at the time of insertion or later. It is advisable to use US scanning along the cannulated vein to locate the catheter, even after an apparently uneventful insertion.

During the procedure some situations should alert practitioners, such as resistance to progression of guidewire or catheter, or poor/absent aspiration of blood

after insertion. In our patient the first resistance to progression of the guidewire attracted our attention, but the easy progression of the catheter through the guidewire and the free aspiration of blood through the 3 lumens reassured us. Identifying a malpositioned CVC is not always easy, as the flow of blood from the catheter lumen even freely after insertion does not rule out malposition [12].

After the procedure a chest X-ray should be systematically done to confirm correct CVC placement and exclude any malposition or other complication. CVCs inserted in the operating room are usually checked by postoperative chest X-ray a few hours after insertion, which may delay the diagnosis of this type of complication, hence the importance of fluoroscopy in guiding the CVC insertion procedure in real time.

Interpretation of central venous pressure (CVP) waveform on the multiparameter monitor can be useful in identifying CVC malposition, since an erroneous CVP value and a suboptimal waveform curve should attract the practitioner's attention [13]. Also, a missing CVP waveform on the monitor despite; exclusion of any sensor or cable malfunction, rinsing the unit and repeated zeroing of the system is an important clue to suspect malposition of the CVC tip.

The endocavitary ECG technique showed its effectiveness in reducing incidence of malposition, especially in clinical situations where radiological verification is contraindicated (pregnancy) or difficult to perform (pre-hospital medicine) [14]. The CVC is introduced through a metal guidewire acting as an electrode; as the guide-catheter set advances the entrance into RA is accompanied by amplification of the P wave, the set is then withdrawn 2 cm after the position in which the amplification of the P wave disappeared (about 2 cm above the RA) which indicates the optimum position of the CVC tip [14].

Transesophageal echocardiography has been defined as a very effective method for checking the position of the CVC tip and avoiding malposition, but remains an invasive and more expensive technique [15].

CONCLUSION

Right IJV should be preferred over left IJV whenever a CVC is indicated. Migration into the contralateral SCV is exceptional, but exposes the patient to an increased risk of venous dysfunctions and thrombosis. Particular attention should be paid to checking the position of the CVC, especially in the presence of a chemotherapy catheter; ultrasound guidance during and after the procedure is useful but not sufficient, and certain atypical events should attract attention, such as resistance to progression of the guidewire and/or catheter, poor aspiration of blood after insertion, and an abnormal PVC waveform. A quick confirmation of the CVC position and its tip should be

obtained by chest X-ray. When possible, the use of fluoroscopy and/or endocavitary ECG to guide the CVC insertion procedure may be effective in preventing malposition and other procedural complications.

REFERENCES

1. Taylor, R.W., & Palagiri, A.V. (2007). Central venous catheterization. *Crit Care Med*, 35(5), 1390-6.
2. McGee, D. C., & Gould, M. K. (2003). Preventing complications of central venous catheterization. *N Engl J Med*, 348(12), 1123-33.
3. Raad, I. I., Luna, M., Khalil, S. A., Costerton, J. W., Lam, C., Bodey, G. P. (1994). The relationship between the thrombotic and infectious complications of central venous catheters. *JAMA*, 271(13), 1014-6.
4. McGee, W. T., Ackerman, B. L., Rouben, L. R., Prasad, V. M., Bandi, V., & Mallory, D. L. (1993). Accurate placement of central venous catheters: A prospective, randomized, multicenter trial. *Crit Care Med*, 21(8), 1118-23.
5. Gibson, F., & Bodenham, A. (2013). Misplaced central venous catheters: Applied anatomy and practical management. *Br J Anaesth*, 110(3), 333-46.
6. Petersen, J., Delaney, J. H., Brakstad, M. T., Rowbotham, R. K., & Bagley Jr, C. M. (1999). Silicone venous access devices positioned with their tips high in the superior vena cava are more likely to malfunction. *Am J Surg*, 178(1), 38-41.
7. Caers, J., Fontaine, C., Vinh-Hung, V., De Mey, J., Ponnet, G., Oost, C. ... & Lacor, P. (2005). Catheter tip position as a risk factor for thrombosis associated with the use of subcutaneous infusion ports. *Support Care Cancer*, 13(5), 325-31.
8. Schummer, W., Schummer, C., Rose, N., Niesen, W. D., & Sakka, S. G. (2007). Mechanical complications and malpositions of central venous cannulations by experienced operators: a prospective study of 1794 catheterizations in critically ill patients. *Intensive Care Med*, 33(6), 1055-9.
9. Bannon, M. P., Heller, S. F., & Rivera, M. (2011). Anatomic considerations for central venous cannulation. *Risk Manag Healthc Policy*, 4, 27-39
10. Rasuli, P., Hammond, D. I., & Peterkin, I. R. (1992). Spontaneous intrajugular migration of long-term central venous access catheters. *Radiology*, 182(3), 822-4
11. Randolph, A. G., Cook, D. J., Gonzales, C. A., & Pribble, C. G. (1996). Ultrasound guidance for placement of central venous catheters: a meta-analysis of the literature. *Crit Care Med*, 24(12), 2053-8
12. Hohlieder, M., Schubert, H. M., Biebl, M., Kolbitsch, C., Moser, P. L., & Lorenz, I. H. (2004). Successful aspiration of blood does not exclude malposition of a large-bore central venous catheter. *Can J Anaesth*, 51(1), 89-90.

13. Agrawal, P., Gupta, B., D'souza, N. (2010). Coiled central venous catheter in superior vena cava. *Indian J Anaesth*, 54(4), 351-2.
14. Pittiruti, M., La Greca, A., & Scoppettuolo, G. (2011). The electrocardiographic method for positioning the tip of central venous catheters. *J Vasc Access*, 12(4), 280-91.
15. Yunseok, J., Ho-Geol, R., Seun-Zhoo, Y., Jim-Hee, K., Jae-Hyon, B. (2006). Transesophageal echocardiographic evaluation of ECG guided central venous catheter placement. *Can J Anesth*, 53(10), 978-83