

Mediterranean Spotted Fever: Epidemiological, Clinical, Paraclinical, and Evolutionary Aspects: About 12 Cases

Khadija Danaoui^{1*}, Rania El Fargani¹, Wiame Ait Driss¹, Malika Idalene¹, Noura Tassi¹

¹Department of Infectious Diseases, CHU Mohammed VI, Faculty of Medicine and Pharmacy of Marrakech, Cadi Ayad University, Marrakech, Morocco

DOI: [10.36347/sasjm.2024.v10i07.003](https://doi.org/10.36347/sasjm.2024.v10i07.003)

| Received: 17.05.2024 | Accepted: 28.06.2024 | Published: 02.07.2024

*Corresponding author: Khadija Danaoui

Department of Infectious Diseases, CHU Mohammed VI, Faculty of Medicine and Pharmacy of Marrakech, Cadi Ayad University, Marrakech, Morocco

Abstract

Original Research Article

Mediterranean spotted fever (MSF) is a disease caused by an obligate intracellular bacterium: *Rickettsia conorii*, which infects humans through a vector (the brown dog tick). The first case of this infection was reported in Tunis in 1910 [1], and the characteristic inoculation lesion of the infection, or "black spot," was subsequently described in 1925 in Marseille. In 1930, the role of the brown dog tick *Rhipicephalus sanguineus* in transmitting the disease was discovered [2], and the causal bacterium, *R. conorii*, was identified [2]. Through this retrospective study, we present an analysis of all patients treated for rickettsiosis between 2008 and 2022 at the infectious diseases department of CHU Mohamed VI in Marrakech, addressing epidemiological, clinical, paraclinical, and evolutionary aspects. Diagnosis should prompt immediate treatment with doxycycline to prevent any progression of the disease to severe forms, especially in patients with comorbidities.

Keywords: Mediterranean spotted fever; *Rickettsia conorii*; Black spot; Fever; Infection.

Copyright © 2024 The Author(s): This is an open-access article distributed under the terms of the Creative Commons Attribution 4.0 International License (CC BY-NC 4.0) which permits unrestricted use, distribution, and reproduction in any medium for non-commercial use provided the original author and source are credited.

INTRODUCTION

Mediterranean spotted fever (MSF) is a disease caused by an obligate intracellular bacterium: *Rickettsia conorii*, infecting humans through a vector (brown dog tick). The first case of this infection was reported in Tunis in 1910 [1], and the characteristic inoculation eschar of the infection, or "black spot," was subsequently described in 1925 in Marseille. Finally, in 1930, the role of the brown dog tick *Rhipicephalus sanguineus* in transmitting the disease was discovered [2], and the causal bacterium *R. conorii* was identified [2].

MATERIALS AND METHODS

We conducted a retrospective study on all patients treated for rickettsiosis between 2008 and 2022 at the infectious diseases department of CHU Mohamed VI in Marrakech.

RESULTS

Epidemiological characteristics:

There were 9 men and 3 women, with a mean age of 43 years (range: 20-75 years). 8 patients reported contact with dogs, with a history of insect bite mentioned in just 5 of our patients.

Clinical signs:

The majority of patients, after an average incubation period of 6 days, presented with a classical form of the disease combining fever, rash, and often eschar: maculopapular rash and fever in all patients, blackish spot in 7 patients, myalgia and headache in 5 patients, and finally, purpuric spots and asthenia were noted in 4 patients (Figure 1).

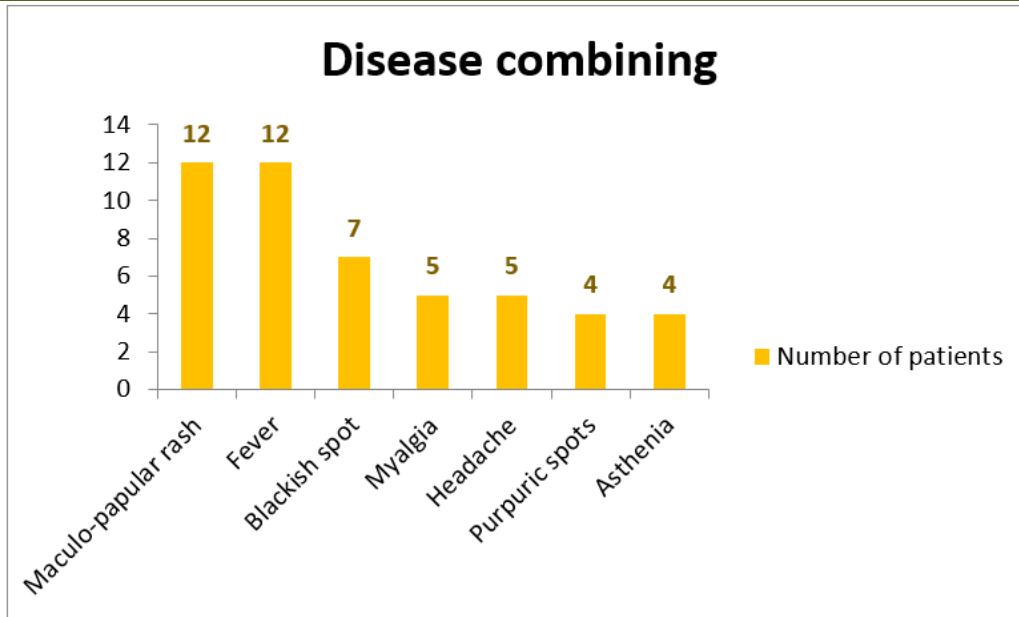


Figure 1: Clinical signs

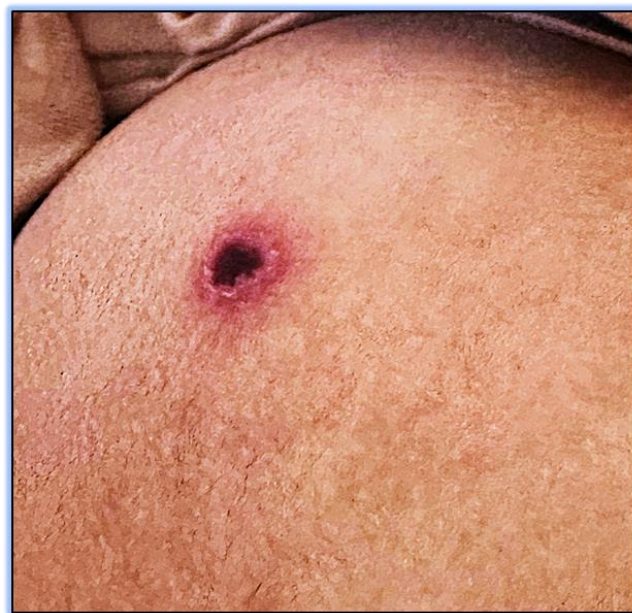

Figure 2: Black spot

Paraclinical:

a- Serology:

Serology (*Rickettsia conorii*) using indirect immunofluorescence was performed in 6 patients, with negative results. Diagnosis was based on a combination of anamnestic and clinical findings.

b- Biological assessment:

Balance sheet	Anomalies	Counts
CBC	Anemia	2
	Thrombocytopenia	3
	Leukocytosis	7
AST/ALT	Cytolysis	6
ionogram	Hyponatremia	3

Treatment

For treatment, all patients were prescribed Doxycycline 200 mg/day with an average treatment duration of 5 days (range: 3-7 days).

Progression

All patients showed favorable progression, with clinical and biological improvement.

DISCUSSION

First described in Tunisia by Conor and Bruch in 1911 as "boutonneuse fever of Tunisia," MSF occurs endemically in the Mediterranean region with summer epidemic outbreaks. It is also found in sub-Saharan Africa, India, around the Black Sea, and even up to

Vladivostok. The frequency in Morocco is still poorly understood [3], however, it appears to be common in our climates [4]. It affects both sexes equally and all age groups, with a predominance in children and individuals over 60 years old [3]. The disease is transmitted by the brown dog tick called *Rhipicephalus sanguineus* [2]. Tick infection is hereditary through transovarian and transstadial transmission. The tick thus serves as both reservoir and vector of the disease [5].

MSF is secondary to *R. conorii* released by the tick at the site of the bite during a blood meal where it causes a local lesion (black eschar: Pierrri's black spot). The tick attachment time must be at least 20 hours to transmit the disease [5], and tick bites are painless. The bacterium crosses the skin or mucous membranes, multiplies in the endothelial cells of small blood vessels, causing vasculitis with endothelial proliferation, perivascular infiltration, and thrombosis. Endovascularitis is responsible for the rash, encephalitic signs, and cutaneous and tissue gangrene [5].

The average incubation period is about one week before the onset of the disease. This is characterized by the sudden onset of high fever (39-40 °C), a maculopapular skin rash involving the palms and soles, and in most cases, an inoculation eschar at the site of the bite, which is characteristic of this infection. This was the case in our series. Arthromyalgia may also accompany the clinical picture. The rash can sometimes be purpuric in severe forms, and the differential diagnosis then includes purpura fulminans. Ocular involvement may occur, with conjunctivitis, especially in cases of conjunctival inoculation after handling the infecting tick [6], or cases of uveitis or chorioretinitis resulting from more severe vascular involvement [7, 8]. In all series reporting cases of MSF, a certain number of patients present severe forms of the disease (5 to 15% of cases) [9], with neurological involvement (meningitis, meningoencephalitis) or multi-organ failure [9]. These conditions occur preferentially in patients with comorbidities such as the elderly, but also those with diabetes, chronic alcoholism, or G6PD deficiency [9]. The overall prognosis depends on the speed of diagnosis and the initiation of appropriate treatment.

Diagnosis is based on presumptive evidence, geographical location, season, fever, and rash. The presence of a black eschar entry point is of paramount importance. All our cases presented with fever and a rash; the eschar was absent in only one patient. Definitive diagnosis relies on indirect immunofluorescence, the reference serological test, by detecting IgM or seroconversion, or a significant increase (fourfold) in antibody titers in two sera taken seven to ten days apart, with a titer greater than 1/60. In our series, serology was performed in only six patients. Direct diagnosis is reserved for severe forms: biopsy of the black eschar and direct immunofluorescence to search for the germ and

isolate the germ by culture on cell medium from plasma [10,11].

Prognosis depends on the individual and the therapeutic delay. MSF has a false reputation for benignity. Its mortality rate is estimated at between 2 and 2.5% for hospitalized patients [11]. Early treatment shortens the duration of symptoms and prevents unfavorable progression [9]. Current therapies recommend the use of doxycycline as the treatment of choice or minocycline at a dose of 200 mg/day for eight days. All our patients were treated with doxycycline with good clinical and biological outcomes. This treatment should lead to afebrile status within 24 to 72 hours unless in severe forms where the course remains unfavorable despite appropriate therapy. In cases of severe, especially neurological forms, allergy, or contraindication to cyclines, fluoroquinolones for seven days remain the best reliable and effective treatment [18]. Macrolides could be used for ten days in children and pregnant women [11,12]. The best prophylaxis relies on controlling the vector, stray dogs, and owning dogs at home since there is no vaccination [9]. After tick bites, antibiotic prophylaxis is not recommended because there is no consensus on its use.

Tick removal is done using tick removers obtained from veterinarians without leaving any embedded remnants.

CONCLUSION

Any summertime eruptive fever with eschar after a stay in an endemic area should be considered and treated as Mediterranean spotted fever until proven otherwise. The advent of PCR targeting *R. conorii* on eschar swabs performed at the National Reference Center is a new rapid and sensitive tool that facilitates the diagnosis of this infection [13].

BIBLIOGRAPHIE

1. Conor, A. & Bruch, A. (1910). Une fièvre éruptive observée en Tunisie. *Bulletin De La Societe De Pathologie Exotique Et De Ses Filiales*; Tome 3.
2. Parola, P., Paddock, C.D. & Raoult, D. (2005). Tick-borne rickettsioses around the world: emerging diseases challenging old concepts. *Clin Microbiol Rev*;18:719–56. doi:10.1128/CMR.18.4.719-756.2005.
3. Brouqui, P., Delmont, J., Raoult, D. & Bourgeade, A. (1992). État actuel des connaissances sur l'épidémiologie des rickettsioses en Afrique. *Bull Soc Pathol Exot*;85:359–64.
4. Mossedaq, R., Slassi, I., El, Alaoui-Faris., Alaoui-Rachidi, F., Al Mas-moudi, M. & Chkili, T. (1992). Forme grave de fièvre boutonnière méditerranéenne (à propos d'un cas). *Maroc Méd*;14:47–9.
5. Raoult, D. & Brouqui, P. (1998). *Les rickettsioses*. Paris: Éditions Elsevier.

6. Brissos, J., de Sousa, R. & Santos, A.S. (2015). Rickettsial infection caused by accidental conjunctival inoculation. *BMJ Case Rep*. doi:10.1136/bcr-2014-207029.
7. Boudebouch, N., Sarih, M. & Socolovschi, C. (2009). Spotted fever group rickettsioses documented in Morocco. *Clin Microbiol Infect*;15 Suppl 2:257–8. doi:10.1111/j.1469-0691.2008.02276.x.
8. Pinna, A., Sechi, L.A. & Serru, A., (2000). Endogenous panuveitis in a patient with *Rickettsia conorii* infection. *Acta Ophthalmol Scand*; 78:608–9.
9. Singh, S., Eldin, C. & Kowalczywska, M., (2013). Axenic culture of fastidious and intracellular bacteria. *Trends Microbiol*; 21:92–9. doi:10.1016/j.tim.2012.10.007.
10. Bouchaib, H., Eldin, C. & Laroche, M. (2018). Tick and fleaborne rickettsioses in TiziOuzou, Algeria: Implications for travel medicine. *Travel Med Infect Dis*; 26:51–7. doi:10.1016/j.tmaid.2018.11.005.
11. Faraoua, Abdelmoula, F., Kourda, M., Touati, M. & Souissi, R. (2000). La fièvre boutonneuse méditerranéenne : à propos d'un cas. *Maghreb Med*; 20:260–1.
12. Raoult, D., Weiller, P.J., Chagnon, A., Chaudet, H., Gallais, H. & Casanova, P. (1986). Mediterranean spotted fever: clinical, laboratory and epidemiological features of 199 cases. *Am J Trop Med Hyg*; 845:50
13. Cascio, A., Colomba, C., Antinori, S., Paterson, D-L. & Titone, L. (2002). Clarithromycin vs Azithromycin in the treatment of Mediterranean spotted fever in children: A Randomized Controlled Trial. *Clin Infect Dis*; 34:154–8.
14. Renvoisé, A., Rolain, J-M. & Socolovschi, C., (2012). Widespread use of real-time PCR for rickettsial diagnosis. *FEMS Immunol Med Microbiol*; 64:126–9. doi:10.1111/j.1574-695X.2011.00899.x.