

## Central Catheter Complicated with Fatal Pulmonary Embolism in a Patient under Chronic Hemodialysis: A Case Report

Tangara, M<sup>1</sup>, Traore, O<sup>2\*</sup>, Toure, A<sup>1</sup>, Maiga, D<sup>1</sup>, Bilumbu, F<sup>1</sup>, Josepha, N<sup>1</sup>, Samake, M<sup>1</sup>, Kouma, A<sup>3</sup>, Sy, S<sup>1</sup>, Kongoulba, M<sup>1</sup>, Yattara, H<sup>1</sup>

<sup>1</sup>Nephrology and Hemodialysis Department of the Point G University Hospital, Bamako, Mali

<sup>2</sup>Radiology Department of the Point "G" University Hospital Center, Bamako, Mali

<sup>3</sup>Radiology Department of the Luxembourg Mother-Child Hospital, Bamako, Mali

DOI: <https://doi.org/10.36347/sasjm.2025.v1i101.004>

Received: 25.11.2024 | Accepted: 29.12.2024 | Published: 06.01.2025

\*Corresponding author: Traore, O

Radiology Department of the Point "G" University Hospital Center, Bamako, Mali

### Abstract

### Case Report

**Introduction:** The use of central venous catheter is a common practice in hemodialysis in Mali. Its use exposes to risks such as infection, stenosis, thrombosis among others. Pulmonary embolism is a rare but serious complication. The aim of our work was to offer advice on the diagnosis, risk factors, treatment and prevention of deep vein thrombosis following the placement of a central catheter. **Observation:** This was a 56-year-old woman, a housewife living in the city of Bamako. She had been on chronic hemodialysis for 6 months due to nephroangiosclerosis, at a rate of two four-hour sessions per week through a right femoral catheter. Before her hospitalization, she had a fever, physical asthenia, anorexia, a feeling of heavy leg on the right and abdominal pain. The clinical examination found a conscious patient, with little color and normal parameters, a swelling of the right leg with pain and redness. The biological assessment revealed hypochromic microcytic anemia, Procalcitonin at 2.75ng/l. The Doppler of the right lower limb confirmed deep vein thrombosis. The pulsed cardiac Doppler and the ECG confirmed the diagnosis of pulmonary embolism. Curative treatment of venous thrombosis was started. The immediate aftermath was marked by respiratory problems requiring oxygen therapy, acute circulatory failure syndrome with coldness of the extremities. The outcome was unfavorable with the death of the patient. **Conclusion:** The use of central venous catheter for hemodialysis as first-line treatment remains frequent in Mali. Patients should benefit from increased monitoring and prophylactic treatment to prevent the occurrence of thromboembolic events.

**Keywords:** Central catheter, Pulmonary embolism and chronic hemodialysis.

Copyright © 2025 The Author(s): This is an open-access article distributed under the terms of the Creative Commons Attribution 4.0 International License (CC BY-NC 4.0) which permits unrestricted use, distribution, and reproduction in any medium for non-commercial use provided the original author and source are credited.

## INTRODUCTION

The use of central venous catheter is a common practice in hemodialysis in Mali following a late diagnosis and management of chronic kidney disease. Its use exposes to risks such as infection, stenosis, thrombosis among others. Pulmonary embolism is a rare but serious complication. It is often secondary to attempts at mechanical or fibrinolysis clearance and is likely to compromise the patient's prognosis [1]. The objective of this observation was to provide advice on the diagnosis, risk factors, treatment and prevention of deep venous thrombosis secondary to the placement of a central catheter.

## OBSERVATION

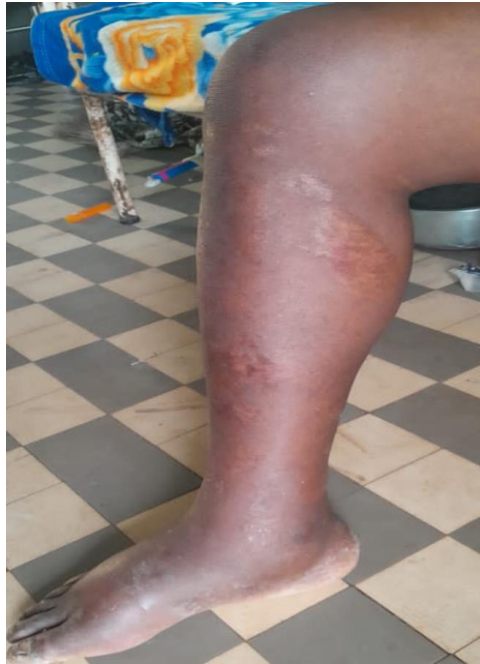This was a 56-year-old woman, a housewife living in the city of Bamako. She had been on chronic

hemodialysis for 6 months due to nephroangiosclerosis, at a rate of two four-hour sessions per week through a right femoral catheter. Ten days before her hospitalization, she had clinically presented with fever, physical asthenia, anorexia, a feeling of heavy leg on the right and abdominal pain. The physical examination found a conscious patient, with little color, BP = 12/06, T ° = 37 ° 6, HR = 97 beats / min, FR = 23 cycles / min, a swelling of the right leg with pain and redness (Figure 1). The biological assessment had highlighted hypochromic microcytic anemia with the hemoglobin level (Hb = 9.7 g / dl); white blood cells (GB=8100), platelets (Pq=290000), CRP at 91ng/l and Procalcitonin at 2.75ng/l. Doppler of the right lower limb was requested and confirmed deep venous thrombosis extending to the right iliac veins to the ipsilateral popliteal (Figure 2).

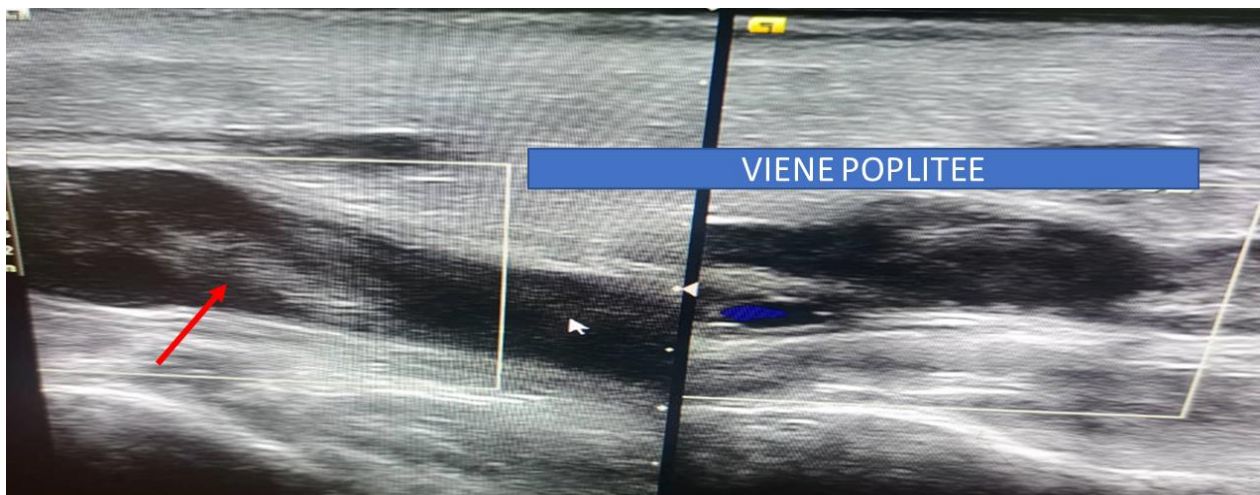
**Citation:** Tangara, M, Traore, O, Toure, A, Maiga, D, Bilumbu, F, Josepha, N, Samake, M, Kouma, A, Sy, S, Kongoulba, M, Yattara, H. Central Catheter Complicated with Fatal Pulmonary Embolism in a Patient under Chronic Hemodialysis: A Case Report. SAS J Med, 2025 Jan 11(1): 13-15.

The pulsed cardiac Doppler and the ECG performed urgently had confirmed the diagnosis of pulmonary embolism. The patient had not then benefited from the CT scan type angiography in view of the emergency signs. The curative treatment of venous thrombosis was started by a bolus of 9500 IU of Calciparin every 12 hours. The immediate aftermath was marked by intense respiratory discomfort then acute

respiratory distress which had required nursing and oxygen therapy, an acute circulatory failure syndrome (BP = 7 / 50 mmhg) with coldness of the extremities was present. The evolution was unfavorable by death because the patient had succumbed to her embolism within 30 minutes after by cardio-circulatory arrest despite the therapeutic attempts of the resuscitators, the pulmonologists and the cardiologists.



**Figure 1: Photograph of a leg and foot showing swelling from venous thrombosis after catheter placement**



**Figure 2: Doppler ultrasound of the right lower limb revealed endoluminal echogenic material in the left popliteal vein (red arrow), making the vein completely incompressible under the probe, thus concluding that there was deep vein thrombosis**

## DISCUSSION

Dialysis patients with a central venous catheter are at risk of occlusion of one or more central veins. Deep vein thrombosis (DVT) on a catheter most often affects the lower limbs and occurs in a deep vein (deep phlebitis). Despite the absence of very specific symptoms, it should be treated because it can lead to sometimes serious complications, in particular

pulmonary embolism responsible for 10 to 20,000 deaths per year in France [1]. There are multiple risk factors, including the use of large caliber catheters with multiple lumens (triple lumen catheters) [2, 3], a poorly placed catheter tip, installation on the left side, concomitant infection, history of DVT and hereditary thrombophilias.

The good practice guide for hemodialysis (K DOQI) recommended the use of less than 20% of

temporary central catheters in a hemodialysis unit [4]. A first study conducted in Dakar found in 89.20% of patients a central venous catheter as the first hemodialysis access [5]. Our patient had been wearing a right femoral catheter as the first-line hemodialysis access for six months. The best way to prevent DVT secondary to the placement of a central catheter in a chronic hemodialysis patient is to avoid the central catheter while making an arteriovenous fistula in the preterminal stages of chronic kidney disease. The use of a small caliber catheter and removing it as soon as it is no longer necessary. And to perform thromboprophylaxis.

## CONCLUSION

The use of central venous catheter for hemodialysis as first-line treatment remains frequent in Mali. The placement of a central venous catheter requires the search for chromogenic risk factors. Patients must benefit from increased monitoring and prophylactic treatment to prevent the occurrence of thromboembolic events.

**Consent:** Informed consent was obtained from the patient and her parents.

**Conflict of Interest:** The authors declare that there is no conflict of interest for this study.

## REFERENCE

1. Sakakibara, Y., Jikuya, T., Soma, S., & Kikuchi, H. (1998). Prevention of pulmonary embolization during excision of an infected venous thrombus. *The Thoracic and cardiovascular surgeon*, 46(03), 162-164.
2. Contreras, G., Liu, P. Y., Elzinga, L., Anger, M. S., Lee, J., Robert, N., ... & Pulliam, J. (2003). A multicenter, prospective, randomized, comparative evaluation of dual-versus triple-lumen catheters for hemodialysis and apheresis in 485 patients. *American journal of kidney diseases*, 42(2), 315-324.
3. Mamzer-Bruneel, M. F., Carron, P. L., Touam, M., Péraldi, M. N., & Kreis, H. (2001). Indications of central venous access in the context of acute renal insufficiency. *Nephrologie*, 22(8), 465-467.
4. NKF-K/ DOQI. (2001). Clinical guidelines for vascular access: update 2000. *Am J Kidney Dis*, 37(1 Suppl 1), S137-181. doi: 10.1016/s0272-6386(01)70007-8.
5. Kane, Y., Cissé, M. M., & Gaye, M. (2015). Problematic of vascular access for hemodialysis in sub-saherienne africa: experience of dakar. *Journal of Nephrology & Therapeutics*, 5, 216. doi:10.4172/2161-0959.1000216