

Jejunal Ectopic Varices Revealed by Massive Gastrointestinal Bleeding in a Patient with Portal Cavernoma: A Case Report

Walid Boukamza^{1*}, Fatimazahra El Jaouhari¹, Amina Faik¹, Salma El Amrani¹, Aicha Akjay¹, Hassan Ouaya¹, Houda Meyiz¹, Ihsane Mellouki¹

¹Department of Gastroenterology, Mohammed VI University Hospital Center, Tangier, Morocco

DOI: <https://doi.org/10.36347/sasjm.2026.v12i05.012>

| Received: 21.03.2026 | Accepted: 08.05.2026 | Published: 13.05.2026

*Corresponding author: Walid Boukamza

Department of Gastroenterology, Mohammed VI University Hospital Center, Tangier, Morocco

Abstract

Case Report

Ectopic varices represent a rare cause of gastrointestinal bleeding, accounting for less than 5% of bleeding episodes related to portal hypertension [1]. Jejunal localization is exceptional and represents both a diagnostic and therapeutic challenge. We report the case of a 25-year-old patient with no known history of liver disease who was admitted for melena evolving for six days associated with deterioration of general condition. Initial laboratory evaluation revealed severe anemia (hemoglobin: 3 g/dL) requiring transfusion of nine units of packed red blood cells. Abdominal CT angiography demonstrated a portal cavernoma extending to the superior mesenteric vein with suspicion of an ectopic varix in the proximal jejunum. Upper gastrointestinal endoscopy followed by enteroscopy revealed a large jejunal varix measuring approximately 4 cm with a central ulceration corresponding to the bleeding site. Hemostasis was achieved by endoscopic injection of 2 ml of cyanoacrylate (Histoacryl). Clinical evolution was favorable after hemodynamic stabilization and partial correction of anemia (hemoglobin: 8.32 g/dL). Jejunal ectopic varices are an exceptional but serious cause of gastrointestinal bleeding. Diagnosis relies on imaging and endoscopic evaluation. Injection of biological glue represents an effective emergency therapeutic option.

Keywords: Ectopic Varices, Jejunum, Portal Cavernoma, Gastrointestinal Bleeding, Portal Hypertension, Cyanoacrylate.

Copyright © 2026 The Author(s): This is an open-access article distributed under the terms of the Creative Commons Attribution 4.0 International License (CC BY-NC 4.0) which permits unrestricted use, distribution, and reproduction in any medium for non-commercial use provided the original author and source are credited.

INTRODUCTION

Portal hypertension classically leads to the development of esophageal and gastric varices. Ectopic varices, defined as porto-systemic collateral veins located outside the gastroesophageal region, are rare and account for less than 5% of variceal bleeding [1, 2].

Jejunal localization is particularly uncommon. It is most often observed in the context of extrahepatic portal vein obstruction or portal cavernoma [3, 4]. Their diagnosis is challenging due to their deep anatomical location and the limited accessibility by conventional endoscopic examinations.

We report a rare case of massive gastrointestinal bleeding revealing a jejunal ectopic varix associated with portal cavernoma in a young patient without known cirrhosis.

CASE PRESENTATION

A 25-year-old patient with no history of liver disease presented with recently diagnosed untreated hypertension, chronic anemia, and unexplored mucous diarrhea.

She was admitted for melena evolving for six days, associated with intense asthenia and progressive deterioration of general condition.

On clinical examination, the patient appeared pale and tachycardic, with signs of poor hemodynamic tolerance.

Initial laboratory evaluation revealed severe anemia with hemoglobin of 3 g/dL. Liver function tests were otherwise normal. The patient required transfusion of nine units of packed red blood cells.

Abdominal CT angiography revealed a portal cavernoma extending to the proximal superior mesenteric vein, circumferential thickening of the rectal

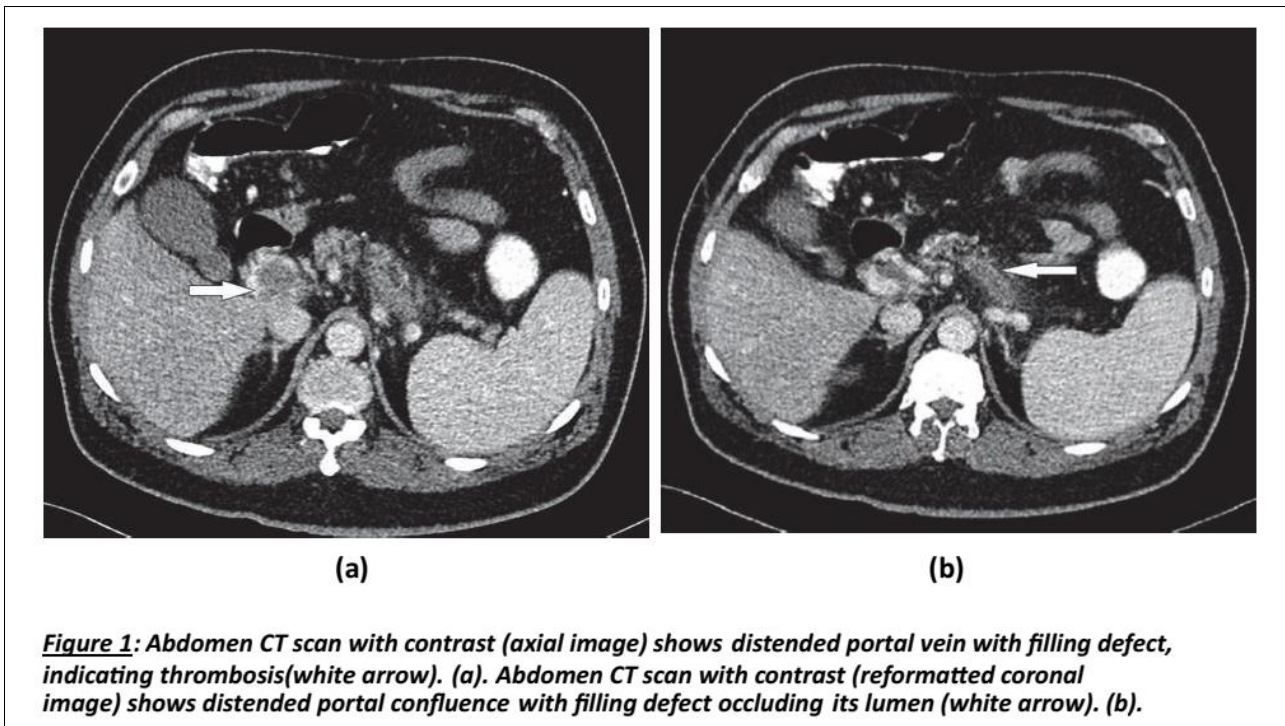
Citation: Walid Boukamza, Fatimazahra El Jaouhari, Amina Faik, Salma El Amrani, Aicha Akjay, Hassan Ouaya, Houda Meyiz, Ihsane Mellouki. Jejunal Ectopic Varices Revealed by Massive Gastrointestinal Bleeding in a Patient with Portal Cavernoma: A Case Report. SAS J Med, 2026 May 12(5): 432-436.

wall associated with significant infiltration of the mesorectal fat, and a small amount of peritoneal fluid

located in the pelvic region and in the right and left paracolic gutters.

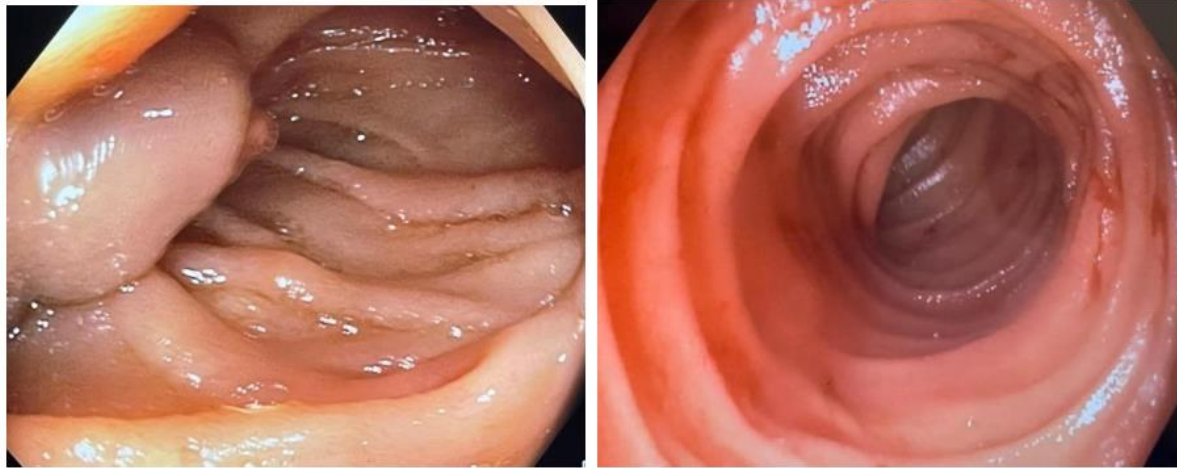Table 1: Summary of the main therapeutic options in ectopic varices

Therapeutic Options	Description	Pros	Cons
Endoscopic therapy	Use of band ligation, sclerotherapy or injection by cyanoacrylate.	Accessible. Available.	High risk of rebleeding.
TIPS	Transjugular intrahepatic portal systemic shunting. It is a shunt creation procedure. Often combined with concomitant embolization for better success and reduction of rebleeding rates.	High success in selected patients. Can be used as primary modality or salvage therapy.	Requires interventional radiologist. Not suitable in occlusive type of varices.
BRTO	Balloon occluded retrograde transvenous obliteration. A shunt closure procedure.	High success in gastric varices. Reported cases of success in ectopic intestinal varices.	Requires expert interventional radiologist. Nonfeasible in occluded type of varices.
Surgical Resection	Surgical removal of the bleeding segment.	Potentially a definitive therapy. Low risk of recurrence.	Risks associated with major intestinal surgery. Less suitable if cirrhotic. Usually a salvage therapy.



Upper gastrointestinal endoscopy did not reveal esophageal or gastric varices. Enteroscopy identified a

large jejunal varix approximately 4 cm in diameter with a central ulceration corresponding to the bleeding site.



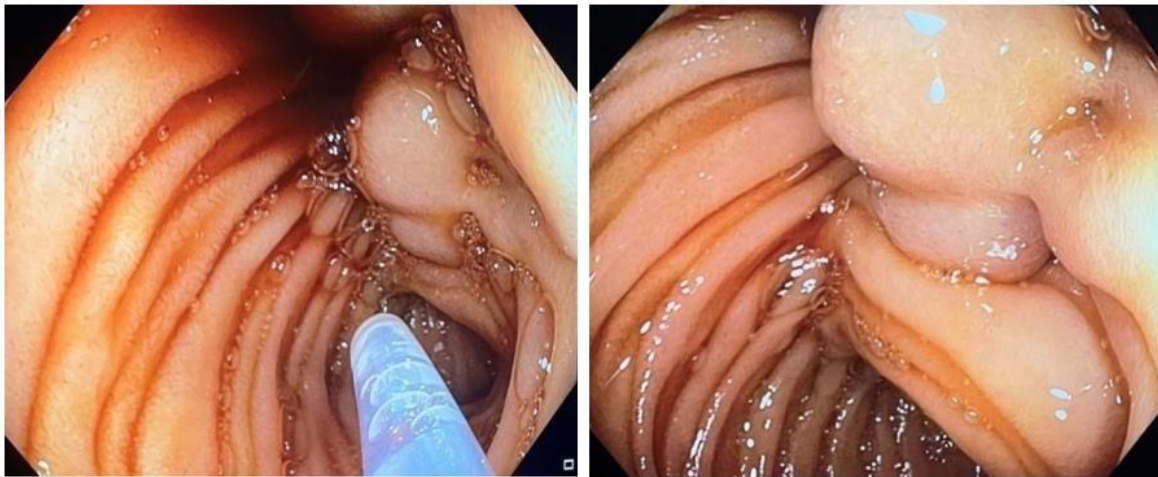
(a)

(b)

Figure 2 : Endoscopic appearance of the jejunal varices visualized during enteroscopy (a), showing stigmata of recent bleeding (b).

Endoscopic treatment with injection of 2 ml of cyanoacrylate (Histoacryl) achieved immediate

hemostasis, confirmed during endoscopic control. Subsequent colonoscopy revealed no abnormalities.



(c)

(d)

Figure 3 : Endoscopic treatment with injection of 2 ml of cyanoacrylate (Histoacryl) (c), achieving immediate hemostasis, confirmed on endoscopic control (d).

Clinical evolution was favorable after hemodynamic stabilization and partial correction of anemia, with hemoglobin increasing to 8.32 g/dL. Follow-up in hepatology consultation was scheduled for etiological evaluation and prevention of recurrence.

DISCUSSION

Ectopic varices correspond to porto-systemic collaterals located outside the gastroesophageal territory. Although rare, they may cause massive and potentially life-threatening gastrointestinal bleeding [2]. Jejunal localization is exceptional and is frequently associated

with extrahepatic portal vein obstruction, particularly in cases of portal cavernoma, as observed in our patient. Portal cavernoma results from chronic thrombosis of the portal vein leading to the formation of collateral venous channels bypassing the obstruction [3, 4].

Diagnosis is often delayed because standard endoscopic examinations may be normal. Cross-sectional imaging, particularly CT angiography, plays a key role in identifying the portal cavernoma and suggesting an ectopic location of varices. Enteroscopy allows direct visualization and endoscopic treatment [5].

Management of ectopic varices relies on several therapeutic options. These include endoscopic treatment such as cyanoacrylate injection or band ligation. Interventional radiology procedures such as transjugular intrahepatic portosystemic shunt (TIPS) or embolization may also be used. Surgical treatment may be considered in selected cases when other therapeutic approaches are not feasible or have failed [3, 4]. Injection of biological glue (cyanoacrylate) is an effective and rapid method for achieving hemostasis in emergency situations when the lesion is accessible [3]. Long-term management should focus on controlling portal hypertension and preventing recurrent bleeding.

Patients with intrahepatic portal hypertension undergoing abdominal surgery have an increased risk of developing ectopic intestinal varices due to postoperative adhesions that bring the abdominal organs into contact with the abdominal wall, leading to the formation of submucosal intestinal varices [9].

Chronic portomesenteric vein thrombosis may also lead to the development of jejunal varices and carries a high mortality rate if not properly managed [6–10]. This condition results in the formation of collateral venous circulation prone to bleeding.

Diagnosis of ectopic varices requires a high index of clinical suspicion. Several diagnostic modalities can be used to evaluate small bowel lesions, but push enteroscopy is more sensitive and also allows therapeutic intervention [12]. Capsule endoscopy may help identify small bowel varices but has limited value in acute gastrointestinal bleeding [2].

Management of ectopic varices remains the most challenging aspect of these cases due to the absence of clinical trials guiding treatment. Available evidence mainly consists of case reports and retrospective series. Therapeutic modalities include TIPS and balloon-occluded retrograde transvenous obliteration (BRTO), although these techniques carry their own risks and recurrence rates [13–15].

Other options include endoscopic band ligation or injection sclerotherapy with cyanoacrylate, as performed in our patient. Surgical resection of the affected bowel segment has also been described as a treatment option with low recurrence rates, although it carries significant risks, particularly in cirrhotic patients [16].

Recent publications have classified ectopic varices into occlusive and non-occlusive types based on hemodynamic criteria [15]. In our case, the patient presented occlusive ectopic varices resulting from portal hypertension secondary to chronic portomesenteric thrombosis. Management options for this type are limited to endoscopic or surgical approaches.

The role of beta-blockers in ectopic varices remains limited. Although theoretically beneficial, no strong evidence supports their effectiveness in extrahepatic portal hypertension.

Current recommendations emphasize the importance of a multidisciplinary approach involving gastroenterologists, interventional radiologists, and surgeons.

CONCLUSION

Jejunal ectopic varices is a rare but potentially life-threatening cause of gastrointestinal bleeding. The combination of imaging and enteroscopy allows accurate diagnosis, while cyanoacrylate injection represents an effective emergency therapeutic option.

Early multidisciplinary management is essential to improve prognosis.

REFERENCES

1. Norton ID, Andrews JC, Kamath PS. Management of ectopic varices. *Hepatology*. 1998;28:1154–1158.
2. Sharma D, Misra SP. Ectopic varices in portal hypertension. *Indian J Surg*. 2005;67:246–252.
3. Rockey DC. Occult and obscure gastrointestinal bleeding: causes and clinical management. *Nat Rev Gastroenterol Hepatol*. 2010;7:265–279.
4. Almadi MA, Almessabi A, Wong P, Ghali PM, Barkun A. Ectopic varices. *Gastrointest Endosc*. 2011;74:380–388.
5. De Palma GD, Rega M, Masone S, Persico F, Siciliano S, Patrone F, et al. Mucosal abnormalities of the small bowel in patients with cirrhosis and portal hypertension: a capsule endoscopy study. *Gastrointest Endosc*. 2005;62:529–534.
6. Raju GS, Gerson L, Das A, Lewis B. American Gastroenterological Association (AGA) Institute technical review on obscure gastrointestinal bleeding. *Gastroenterology*. 2007;133:1697–1717.
7. Leighton JA, Goldstein J, Hirota WK, Jacobson BC, Johanson JF, Mallery JS, et al. Obscure gastrointestinal bleeding. *Gastrointest Endosc*. 2003;58:650–655.
8. Tang SJ, Zanati S, Dubcenco E, Cirocco M, Christodoulou D, Kandel G, et al. Diagnosis of small-bowel varices by capsule endoscopy. *Gastrointest Endosc*. 2004;60:129–135.
9. Triester SL, Leighton JA, Leontiadis GI, Fleischer DE, Hara AK, Heigh RI, et al. A meta-analysis of the yield of capsule endoscopy compared to other diagnostic modalities in patients with obscure gastrointestinal bleeding. *Am J Gastroenterol*. 2005;100:2407–2418.
10. Joo YE, Kim HS, Choi SK, Rew JS, Kim HR, Kim SJ. Massive gastrointestinal bleeding from jejunal varices. *J Gastroenterol*. 2000;35:775–778.

11. Deshpande A, Sampat P, Bhargavan R, Sharma M. Bleeding isolated jejunal varices without portal hypertension. *ANZ J Surg*. 2008;78:814–815.
12. Bykov S, Becker A, Koltun L, Yudko E, Garty I. Massive bleeding from jejunal varices in a patient with thalassemia major detected by Tc-99m red blood cell scintigraphy. *Clin Nucl Med*. 2005;30:457–459.
13. Lim LG, Lee YM, Tan L, Chang S, Lim SG. Percutaneous paraumbilical embolization as an unconventional and successful treatment for bleeding jejunal varices. *World J Gastroenterol*. 2009; 15:3823–3826.
14. Getzlaff S, Benz CA, Schilling D, Riemann JF. Enteroscopic cyanoacrylate sclerotherapy of jejunal and gallbladder varices in a patient with portal hypertension. *Endoscopy*. 2001; 33:462–464.
15. Garcia-Tsao G, Abraldes JG, Berzigotti A, Bosch J. Portal hypertensive bleeding in cirrhosis: risk stratification, diagnosis, and management. *Hepatology*. 2017; 65:310– 335.
16. Saad WE, Lippert A, Saad NE, Caldwell S. Ectopic varices: anatomical classification, hemodynamic classification, and hemodynamic-based management. *Tech Vasc Interv Radiol*. 2013; 16:158–175.