

The Ileo Sigmoidal Node: A Rare Cause of Bowel Obstruction

A. Daki*, R. Taoussi, A. Laanait, A. Siwan, O. Kacimi, N. Touil, N. Chikhaoui

Service de radiologie des urgences, CHU Ibn Rochd, Casablanca

DOI: [10.36347/sasjm.2021.v07i07.007](https://doi.org/10.36347/sasjm.2021.v07i07.007)

| Received: 18.06.2021 | Accepted: 22.07.2021 | Published: 30.07.2021

*Corresponding author: Anouar Daki

Abstract

Case Report

The objective of this work is to highlight and discuss a rare cause of intestinal obstruction with a poor prognosis, through the case of an intestinal obstruction on ileo sigmoidal volvulus or (ileo sigmoidal node) for which we will discuss its clinical, paraclinical, therapeutic and evolutionary characteristics, with review of the literature. This is a 45 year old patient, without any particular pathological history, admitted for abdominal defence of sudden onset associated with a cessation of matter and gas, the biological work-up objective a hyperleucocytosis at 15000 (G/L), with a CRP at 45 mg/l, the abdominal film without preparation objective a gallic and colonic distension with the presence of a hydroareic level, An abdomino-pelvic CT scan was requested as a matter of urgency and showed distension of the gallbladder and colonic anses with evidence of a transitional level upstream of an ileo-sigmoid loop, immediate surgical management was required with a sigmoidectomy and resection of 25 cm of the small bowel. The postoperative follow-up was marked by a disappearance of the pain with resumption of intestinal transit. Although ileo sigmoidal volvulus is a rare cause of bowel obstruction, diagnosis should be made early to avoid bowel necrosis.

Keywords: Ileo Sigmoidal Node Bowel.

Copyright © 2021 The Author(s): This is an open-access article distributed under the terms of the Creative Commons Attribution **4.0 International License (CC BY-NC 4.0)** which permits unrestricted use, distribution, and reproduction in any medium for non-commercial use provided the original author and source are credited.

INTRODUCTION

The ileo-sigmoid volvulus, or sigmoid-linked knot, is a "knot" created by a volvulus of two intestinal segments, the sigmoid colon and the small intestine [1], more particularly the ileum. It is most often a volvulus of the small intestine around the sigmoid colon causing it to twist. Most often it manifests as abdominal guarding with intestinal obstruction.

We report the case of a small bowler and colonic obstruction revealed by abdominal pain with cessation of matter and gas evolving for 24 hours, and whose CT confirmed the ileo-sigmoid volvulus, with immediate surgical management showing extensive necrosis of the sigmoid and small bowel.

OBSERVATION

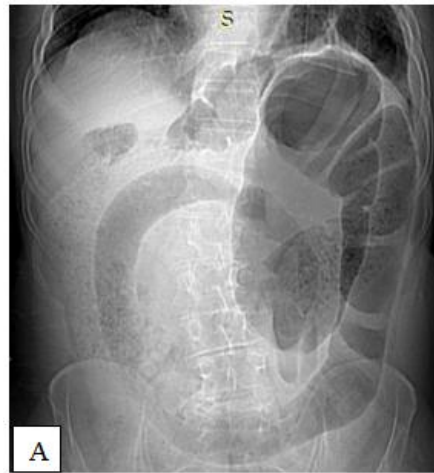The patient was a 45 year old man with no previous history of illness who presented with severe abdominal pain associated with cessation of matter and gas.

The examination on admission found a patient who was apyretic, hemodynamically and respiratorily stable, with generalized abdominal contracture, the

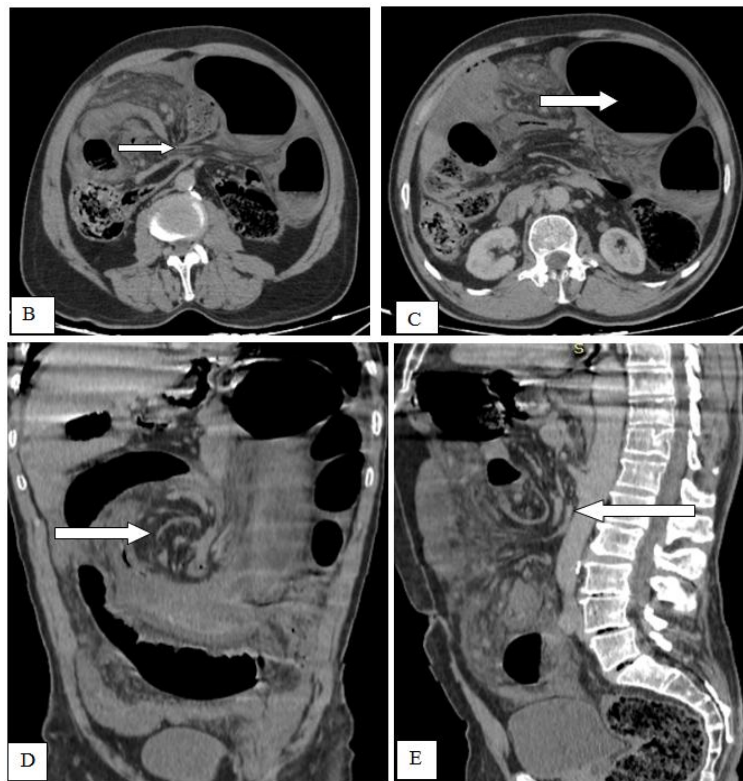
rectal examination showed an empty rectal ampulla with a trace of blood, an inflammatory assessment was carried out showing a VS of 62 mm at the first hour, a CRP of 45 mg/l and white blood cells of 15,000 elements/mm³.

An abdominal and pelvic CT scan was carried out as a matter of urgency, showing a double volvulus: with distension of the sigmoid colon and the appearance of a volvulus (figure B and C), rotation of the mesenteric vessels (figure D and E) and a lack of parietal enhancement, indicating ischaemic suffering. On the other hand, there is distension of the small intestine with a transitional zone at the foot of the sigmoid loop and a second rotation of the mesenteric vessels.

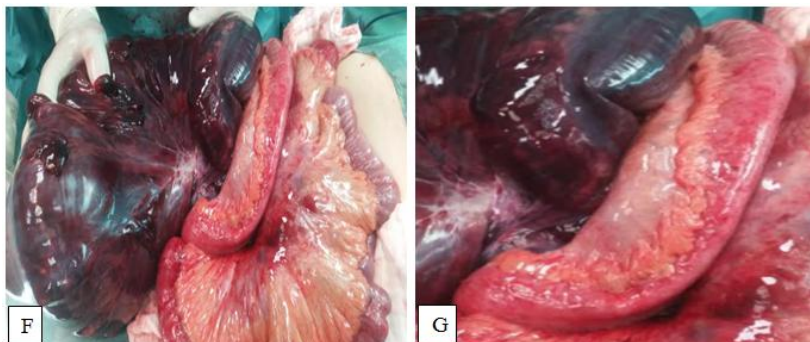
The patient underwent emergency surgery, confirming the volvulus of the sigmoid on a knot made by a small loop at the foot of the sigmoid loop. This double occlusion is complicated by pre-perforative necrosis of the sigmoid loop and the dilated small intestine (fig G and H). During this operation a sigmoidectomy is performed and approximately 25 cm of small bowel is resected.

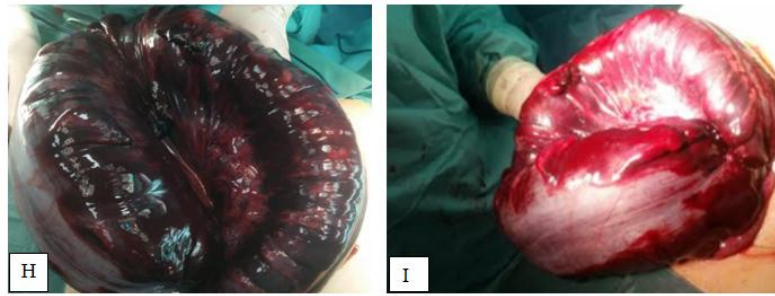


A X-Ray abdomen without preparation: showing sigmoid colon distension with strong suspicion of volvulus



Abdominal CT scan after injection of CP in axial (B and C), coronal (D) and sagittal (E) sections, showing significant dilatation of the sigmoid colon measured at 9 cm long axis (arrow in C) with evidence of the ileal node around the sigmoid (arrow in B, D and E)





Per operative images of the ileal node (F and G), and of the sigmoid volvulus with perforative necrosis (H and I)

DISCUSSION

The ileo-sigmoid node (ISN) is an entity described in Africa, Asia and Eastern Europe but remains rare, accounting for 7.6% of all sigmoid volvuli [2]. This mechanism of double strangulation of the mesenteric vessels to small bowel and the sigmoid causes immediate ischaemic suffering [3].

Clinical diagnosis must be made early in order to avoid intestinal necrosis; the clinical picture may be suggestive, but scannographic diagnosis is difficult given the atypicality of the semiological signs; the diagnosis is often made intraoperatively [4].

Atamanalp and al. Have suggested anatomical predispositions with a hypermobile small bowel, an excessively long meso or redundant sigmoid loops [5], whereas Shepherd explains ISN solely by a hypermobile small bowel that wraps around the foot of the narrow sigmoid meso. Alver, and al. describe 3 types of ISN, the mechanisms of which vary according to the digestive segment responsible for the torsion (active segment) [6, 7]: type I is represented by a small intestine looping around a passive sigmoid loop, type II results from the opposite phenomenon where the active sigmoid torsion attracts the passive small intestine, and finally type III corresponds to the exceptional situation where the ileo-caecal junction "cravats" the sigmoid loop. These mechanisms explain the poor prognosis, often with the presence of perforating or preperforating lesions [8].

CONCLUSION

The ileo-sigmoid node is a rare but serious entity of acute intestinal occlusion. Its rapid evolution explain the pejorative prognosis with often the presence of perforative towards digestive necrosis secondary to vascular strangulation should lead to urgent surgical intervention when a double volvulus is discovered on the CT scan.

Declaration of interests

The authors declare that they have no conflicts of interest in relation to this article. According to the

international or academic standard, the patient's consent was collected and retained by the authors.

Contribution of the authors

All authors have contributed equally to the conduct of this work. They also declare that they have read and approved the final version of the manuscript.

RÉFÉRENCE

1. Hirano, Y., Hara, T., Horichi, Y., Nozawa, H., Nakada, K., Oyama, K., ... & Kitagawa, K. (2005). Ileosigmoid knot: case report and CT findings. *Abdominal imaging*, 30(6), 674-676.
2. Tamura, M., Shinagawa, M., & Funaki, Y. (2004). Ileosigmoid knot: computed tomography findings and the mechanism of its formation. *ANZ journal of surgery*, 74(3), 184-186.
3. Hashimoto, T., Yamaguchi, J., Fujioka, H., Okada, H., Izawa, K., & Kanematsu, T. (2004). Two cases of ileosigmoid knot: the youngest reported patient and CT findings. *Hepato-gastroenterology*, 51(57), 771-773.
4. Atamanalp, S. S., Ören, D., Yildiran, M. İ., Başoğlu, M., Aydınli, B., Öztürk, G., & Salman, B. (2007). Ileosigmoidal knotting in children: A review of 9 cases. *World journal of surgery*, 31(1), 31-35.
5. Varoquaux, A., Ananian, P., Richa, H., Chagnaud, C., & Le Treut, Y. P. (2007). Ileosigmoid knot is an unusual and severe cause of bifocal bowel strangulation. *Gastroenterologie clinique et biologique*, 31(11), 975-977.
6. Fouquet, V., Berrebi, D., De Lagausie, P., Azeïfish, S., Chalard, F., Peuchmaur, M., & Aigrain, Y. (2006). Ileosigmoid knotting in a child: the first case report in a French girl. *Gastroentérologie clinique et biologique*, 30(12), 1414-1416.
7. Alver, O., Ören, D., Tireli, M., Kayabaşı, B., & Akdemir, D. (1993). Ileosigmoid knotting in Turkey. *Diseases of the colon & rectum*, 36(12), 1139-1147.
8. Lee, S. H., Park, Y. H., & Won, Y. S. (2000). The ileosigmoid knot: CT findings. *American Journal of Roentgenology*, 174(3), 685-687.