

## Schnyder Crystalline Corneal Dystrophy: A Case Report

El Mhadi Mohcine<sup>1\*</sup>, El Ouafi Aziz<sup>1</sup>, Boughanim Meryem<sup>1</sup>, Iferkhas Said<sup>1</sup>

<sup>1</sup>Ophthalmology Department of the Military Hospital Moulay Ismail of Meknes, Morocco

DOI: [10.36347/sasjm.2022.v08i02.001](https://doi.org/10.36347/sasjm.2022.v08i02.001)

| Received: 16.12.2021 | Accepted: 29.01.2022 | Published: 03.02.2022

\*Corresponding author: El Mhadi Mohcine

Ophthalmology Department of the Military Hospital Moulay Ismail of Meknes, Morocco

### Abstract

### Case Report

Schnyder crystalline corneal dystrophy (SCCD) is a rare hereditary corneal pathology, the clinical forms of which can be varied. It is classically characterized by the presence of central corneal disc or ring opacities, with or without the presence of crystals, and sometimes the association with a peripheral corneal arch or the limbic belt of Vogt. Its pathogenesis is linked to an abnormality in lipid metabolism with accumulation of lipids (phospholipids or cholesterol) in the cornea. We report the case of a 30-year-old patient, with no particular history, presenting a progressive decrease in visual acuity linked to central corneal opacities, in disc form following an accumulation of iridescent crystals in the central portion of the stroma, with a peripheral lipid arc all evolving for 15 years, and we describe its aspects in anterior segment optical coherence tomography and in vivo confocal microscopy. The purpose of our case is to recall the clinical and biological characteristics of Schnyder crystalline corneal dystrophy, and to underline the risk of occurrence of diffuse vascular damage secondary to a lipid disorder favoring cardiovascular accidents. Ophthalmologists should be aware of the ocular and general signs of Schnyder's dystrophy in order to preserve functional visual and vital cardiovascular prognosis.

**Keywords:** Schnyder crystalline corneal dystrophy; Anterior segment optical coherence tomography; In vivo confocal microscopy; hypercholesterolemia.

**Copyright © 2022 The Author(s):** This is an open-access article distributed under the terms of the Creative Commons Attribution **4.0 International License (CC BY-NC 4.0)** which permits unrestricted use, distribution, and reproduction in any medium for non-commercial use provided the original author and source are credited.

## INTRODUCTION

Schnyder crystalline corneal dystrophy (SCCD) is a rare hereditary corneal pathology, the clinical forms of which can be varied. It is classically characterized by the presence of central corneal disc or ring opacities, with or without the presence of crystals, and sometimes the association with a peripheral corneal arch or the limbic belt of Vogt [1].

Its pathogenesis is linked to an abnormality in lipid metabolism with accumulation of lipids (phospholipids or cholesterol) in the cornea.

We report the case of a 30-year-old patient with a progressive decrease in visual acuity related to crystalline corneal dystrophy.

The purpose of our observation is to recall the clinical and biological characteristics of Schnyder's corneal dystrophy, and to underline the risk of occurrence of diffuse vascular damage favoring cardiovascular accidents [2].

## CLINICAL OBSERVATION

A 30-year-old woman was referred to us for a progressive decline in her visual acuity. The patient reported the appearance of white spots in her eyes, gradually increasing in size over the past 15 years.

Her personal and family history, especially general and ophthalmologic were unremarkable.

The best corrected visual acuity was 3/10th on the right and 2/10th on the left, and the intraocular pressure was 14 mmHg on the right and 16 mmHg on the left.

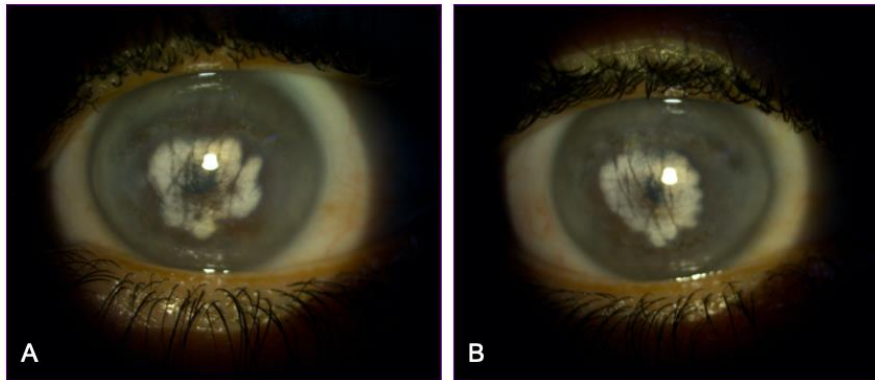
Biomicroscopic examination revealed bilateral and symmetrical involvement with central corneal opacities, in disc form, following an accumulation of iridescent crystals in the central portion of the stroma, a peripheral lipid arc with a haze in the middle periphery (Figure 1).

The anterior segments were quiet. After dilation, the fundus was normal in both eyes, with no retinal abnormality.

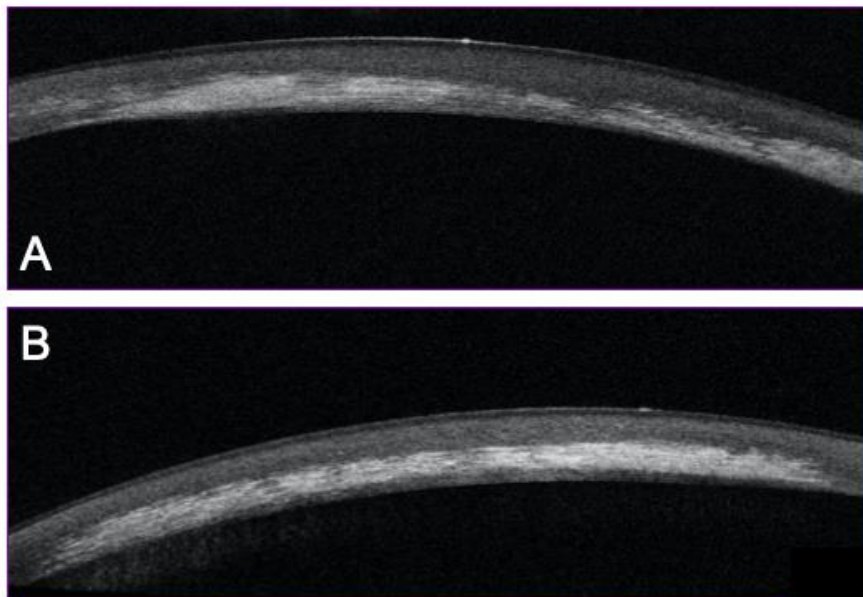
The patient had an anterior segment optical coherence tomography (OCT) performed using the OCT-Topcon® non-contact optical imaging system to obtain high resolution sections of the cornea or iridocorneal angle [3]. On the images obtained, zones of

hyper-reflectivity corresponding to the location of the lesions were visible at the level of the stroma. The examination confirms the involvement of the entire depth of the stroma, including the posterior stroma (Figure 2).

The general examination of our patient is without abnormality. A biological assessment was carried out revealing no lipid disorder.



**Figure 1: Biomicroscopic photography (A) Right eye, (B) Left eye. Revealing bilateral and symmetrical involvement with central corneal opacities, in disc form, following an accumulation of iridescent crystals in the central portion of the stroma, a peripheral lipid arc with a haze in the middle periphery**



**Figure 2: Anterior segment optical coherence tomography performed using topcon® OCT. (A) Right eye, (B) Left eye. Showing zones of hyper-reflectivity involving the entire anterior and posterior stroma**

**DISCUSSION**

Schnyder crystalline corneal dystrophy (SCCD) is a rare hereditary corneal pathology, the clinical forms of which can be varied. Described for the first time in 1924 by Van Went and Wibaut, it was defined in 1929 by Schnyder as an individualized hereditary entity [4].

It is transmitted in the autosomal dominant manner, the responsible gene being located on the short arm of chromosome 1: 1p36-p34.1 [5]. Sporadic forms have been described, which could be the case for the one reaching this patient who did not present a similar case in her family. The signs found in this dystrophy result from the accumulation of cholesterol and

phospholipids in the corneal stroma associated with a degeneration of collagen fibrils [1].

SCCD is typically characterized by the presence of fine crystals producing a round or oval, annular or disc-shaped central opacity in the anterior stroma. Recently, this notion has been challenged [6], and it is currently well established that crystals are present in about 50% of cases [7], as is the case for our patient. It usually begins early, diagnosed rather during the third or fourth decade. It is most often asymptomatic and only rarely causes a decrease in visual acuity, particularly in the annular form without central involvement [8].

In patients with this pathology, hypercholesterolemia must be sought during the interrogation and be the subject of a specific assessment in order to be treated if necessary [1]. Other classic associations should also be sought, such as genu valgum [9], chondrodystrophy or atherosclerosis with diffuse vascular pain.

Schnyder crystalline corneal dystrophy is usually without posterior segment involvement. However, it may be associated with chorioretinal involvement secondary to chronic vascular disease [2].

The knowledge of the clinical characteristics of this dystrophy allows us to make the differential diagnosis with other types of stromal dystrophies (granular, macular, speckled, amyloid dystrophies), these are evoked in the presence of central disc involvement. As well as other pathologies due to the deposition of crystals in the cornea how side effects of fluoroquinolones or other drugs such as chlorpromazine, chloroquine, and clofazamine, Bietti's crystal dystrophy, cystinosis, infectious crystal keratopathy and lymphoproliferative diseases such as monoclonal gammopathy and myeloma [10]. Our patient had no history of use of fluoroquinolones or any other medication, infection or systemic disease.

The in vivo confocal microscopy aspects of several cases of Schnyder's dystrophy have already been described [11, 12] in particular the altered appearance of the stroma in relation to the accumulation of lipids at its level, the stromal deposits which are hyperreflective with a filiform appearance and organization in a crystal lattice or in parallel lines and disorganization of the subepithelial nerve plexus.

Histological involvement in Schnyder's dystrophy is typically subepithelial and anterior stromal with destruction of Bowman's layer [13]. In addition, abnormalities of the deep stroma, endothelium and basal layer of the epithelium have also been described, as is the case for our patient [14].

No treatment is available to stop the progression of this disease. However, several surgical techniques can be proposed, the choice of which depends on the depth of the damage to the stroma: therapeutic photokeratectomy, in the case of very superficial deposits, penetrating or lamellar keratoplasty, corneal transplantation [1]. The therapeutic decision could be based on the results of confocal microscopy in vivo, but especially of the OCT of the anterior segment which make it possible to precisely locate the damage at the corneal level. However, biomicroscopic analysis is often sufficient to establish the indication for treatment, the interest of confocal microscopy in vivo could be above all to detect crystals not visible at the optical level in order to confirm the diagnosis in difficult cases.

## CONCLUSION

The clinical case reported here, very suggestive of Schnyder's dystrophy, underlines the importance of clinical examination for diagnosis.

Faced with the existence of crystalline corneal deposits, Schnyder's dystrophy should be considered and search for chorioretinal involvement, family history and associated pathologies such as hypercholesterolemia and diffuse atherosclerosis.

In vivo confocal microscopy and anterior segment OCT find aspects that are non-specific but well correlated to the histological location of the lesion, and can thus be an aid to therapeutic choices.

Ophthalmologists should be aware of the ocular and general signs of Schnyder's dystrophy in order to preserve functional visual and vital cardiovascular prognosis.

**Conflicts of interest:** The authors do not declare any conflict of interest.

## Authors Contributions

El Mhadi Mohcine and El Ouafi Azize are the main authors. Boughanim Meryem is the second author. Iferkhash Said is the head of ophthalmology department.

## REFERENCES

1. Foster, C. S., Azar, D. T., & Dohlman, C. H. (2005). Stromal and Pre-Desemet's Dystrophies. In: Smolin and Thoft's, editors. *The Cornea*. 4th ed. Lippincott/WW; p.833-835.
2. Cochard, C., Roussel, B., Bettembourg, O., Larvor, A. Y., Ropars, Y. M., & Cochener, B. (2008). 367 Dystrophie cornéenne cristalline associée à une atteinte chorioretinienne. *Journal Français d'Ophthalmologie*, 31, 124.
3. Bellotti, A., Labbé, A., Fayol, N., El Mahtoufi, A., & Baudouin, C. (2007). Apport de l'OCT pour

- l'étude du glaucome néovasculaire. *Journal français d'ophtalmologie*, 30(6), 586-591.
4. Schnyder, W. F. (1929). Mitteilung uber einen neuen Typus von Familiarer Hornhauterkrankung. *Schweiz Med Wochenschr*, 59, 559-571.
  5. Evans, C. J., Dudakova, L., Skalicka, P., Mahelkova, G., Horinek, A., Hardcastle, A. J., ... & Liskova, P. (2018). Schnyder corneal dystrophy and associated phenotypes caused by novel and recurrent mutations in the UBIAD1 gene. *BMC ophthalmology*, 18(1), 1-7.
  6. Weiss, J. S. (1996). Schnyder crystalline dystrophy sine crystals: recommendation for a revision of nomenclature. *Ophthalmology*, 103(3), 465-473.
  7. Rittenbach, T. L. (2013). A case of Schnyder corneal dystrophy with crystals. *Optometry and Vision Science*, 90(12), e301-e304.
  8. Brasnu, E., Dupas, B., Hoang-Xuan, T., Baudouin, C., & Gatinel, D. (2010). Schnyder's crystalline-like corneal dystrophy: a case report. *Journal français d'ophtalmologie*, 33(4), 264-e1.
  9. Hoang-Xuan, T., Pouliquen, Y., & Gasteau, J. (1985). Schnyder's crystalline dystrophy. II. Association with genu valgum. *Journal français d'ophtalmologie*, 8(11), 743-747.
  10. Kurtul, B. E., Elbeyli, A., Ozcan, D. O., Ozcan, S. C., & Karaaslan, A. (2020). Schnyder Corneal Dystrophy: A Rare Case Report. *Nepalese Journal of Ophthalmology*, 12(1), 110-113.
  11. Ciancaglini, M., Carpineto, P., Doronzo, E., Nubile, M., Zuppari, E., & Mastropasqua, L. (2001). Morphological evaluation of Schnyder's central crystalline dystrophy by confocal microscopy before and after phototherapeutic keratectomy. *Journal of Cataract & Refractive Surgery*, 27(11), 1892-1895.
  12. Vesaluoma, M. H., Linna, T. U., Sankila, E. M., Weiss, J. S., & Tervo, T. M. (1999). In vivo confocal microscopy of a family with Schnyder crystalline corneal dystrophy. *Ophthalmology*, 106(5), 944-951.
  13. Hoang-Xuan, T., Pouliquen, Y., Savoldelli, M., & Gasteau, J. (1985). Schnyder's crystalline dystrophy: study of a case in optical microscopy and ultrastructure. *J Fr Ophtalmol*, 8, 735-742.
  14. Freddo, T. F., Polack, F. M., & Leibowitz, H. M. (1989). Ultrastructural changes in the posterior layers of the cornea in Schnyder's crystalline dystrophy. *Cornea*, 8(3), 170-177.