

Case Report

Large operable Ewing sarcoma of the pancreas: Report of a case and review of the literature

Dr. Navneet Kumar¹, Dr. Garima Sharma², Dr. Shalu Gupta³, Dr. Ram Daga⁴, Dr. Irfan Hussain⁵,
Dr. Sami Anwar Khan⁶

^{1,2,6}Residents, ⁴Assistant Prof. (G.I. surgery), ³Associate Prof. (General Surgery), Department of General Surgery, S.M.S. Medical College, Jaipur(302004), Rajasthan, India.

*Corresponding author

Dr. Navneet Kumar

Email: dr.navneetk2011@gmail.com

Abstract: Extra osseous ewing sarcoma is rare which mainly arise in paravertebral soft tissue and associated with CNS and ewing sarcoma of abdominal viscera is very rare. Only 14 to 18 cases of EES/pPNET arising in the pancreas have been reported so far in literature. We report a case 22 year boy presented with 15 days history of pain and lump abdomen. CT shows 18 *12cm mass in head of pancreas with central necrosis. CT scan showed no signs of metastatic tumor spread. Whipple procedure done for this patient, diagnosis of ewing sarcoma was confirmed by histology and immunohistochemistry.on IHC tumor was positive foe nuron specific enolase, KI 67 and MIC-2 and negative for pancytokeratin and progesterone. After surgery all margin was negative 8 LN was removed which was negative for metastasis. Patient has taken chemotherapy (6 cycle of VAC-vincristine adriamycine cyclophosfamide) and doing well after 6 month of operation .CT after 3 month of surgery was normal there was no evidence of disease .so any pancreatic mass which grows rapidly and patient present with short history we should think about PNET/ES and consider it as a differential diagnosis.

Keywords: Ewing's sarcoma, Extraosseous Ewing's, sarcoma, Primitive neuroectodermal tumor, PNET, Pancreas

INTRODUCTION

Ewing sacoma is after the name of James Ewing who first describe the disease as a "diffuse endothelioma of bone. Ewing sarcoma cover a huge spectrum of tumor which shows small hyperchromatic nucli withpale cytoplasm arranged in broad sheets with minimal intercellular marerial these tumor are positive for nural marker.typicaly all tumor of this family shere a same genetic abnormality namly a t(11;22) translocation.

Usually ewing sarcoma is disease of bone children n young adult affected mainly.these tumor mainly compose of small round cell having hyperchromatic nucli scant pale cytoplasm.ewing sarcoma mainly metastasise through hematogenous route to lung and other bones occasionally it may arise from soft tissue (Extraosseous Ewing's Sarcoma [4].

Two theory is given to explane its origin first ewing sarcoma arise from a primitive cell of nural crest(embryologic tissue) derived second it arise from resident cell called mesenchymal stem cells that have a capability to transform to other type of tissue become. These tumor not only shere same kind of histopathological feature under microcope but also have same kind of genetic abnormality called

translocationPathologists have long known that Ewing sarcoma looks very similar to an even rarer soft tissue tumor called primitive neuroectodermal tumor (PNET). By the early 1980's, ES and PNET were found to not only have similar features when examined under a microscope, but in greater than 95% of cases they also had an identical genetic abnormality called a translocation¹⁵. Subsequently, these two type of tumors have been grouped into a family of cancers entitled Ewing's Sarcoma Family of Tumor (ESFT), all of which share this translocation.

In ESFT, the translocation is between chromosomes 11 and 22 and is referred to as t(11;22). The gene on chromosome 22 encodes the Ewing sarcoma gene (EWS)[16]. The gene from, named FLI1 present on chromosome 11 , is responsible for turning other genes on and off. This new fused gene, called EWS/FLI, encodes an altered fusion protein that regulates other genes that can give rise to cancers when inappropriately expressed [2].

Tefft gave a series of 5 patients with a small round blue cell tumor that histologically resembled ES but arose from the paravertebral soft tissues. Since then, Extraosseous ewing sarcoma has been recognized as a distinct disease entity. that affects young adults aged 10

to 30 years, with equal sex distribution. This is more aggressive than osseous ewing it is curable, with the best prognosis seen in patients younger than 16 years of age[17].

CASE REPORT

A 22 year old boy presented in surgery OPD with a short history of dull aching pain abdomen and

rapidly enlarging lump abdomen. On examination hard lump was present in right lumbar right hypochondrium and right side of umbilical region move slightly with respiration. Patient had mild jaundice CT shows 18 *12 cm mass in head of pancreas with internal necrosis and heterogenous enhancemen and body and tail was normal. No LN seen fat plane with surrounding structure was normal spared.

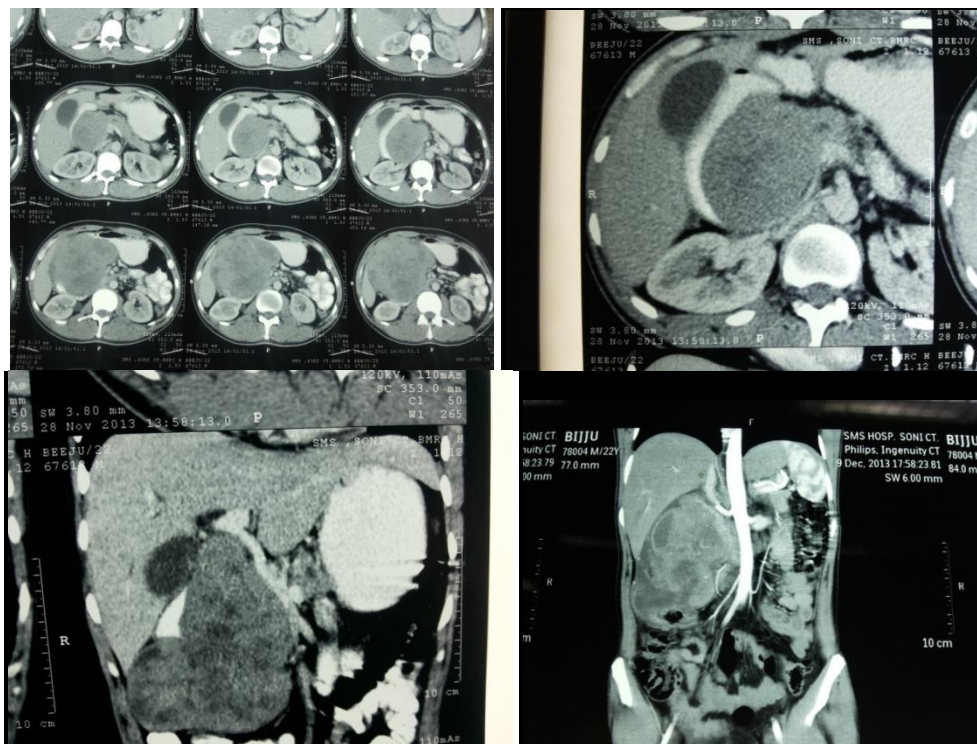


Fig- CT Scan Study

EUS gave same information EUS guided FNAC taken which came to be a undifferentiated small round cell malignant tumor. Routine blood investigation was normal except billirubin was mildly raised .Serum amylase and lipase was normal. Chest x-ray was normal. Surgery was planned and classical whipple procedure done. Per-op finding was, large solid tumor arising from head of pancreas around 20*15 cm size extending right side up

to lateral abdominal wall superiorly up to porta inferiorly below umbilicus and on left side up to 6cm left to mid line. Tumor was compressing the duodenum pushing transverse colon inferiorly. There was no evidence of metastasis. Grossly, the tumor was well-circumscribed, capsulated, measured 20*15 cm, and weighed 1200g. Cut section revealed a grey tan hemorrhagic solid and cystic tumor with areas of necrosis.

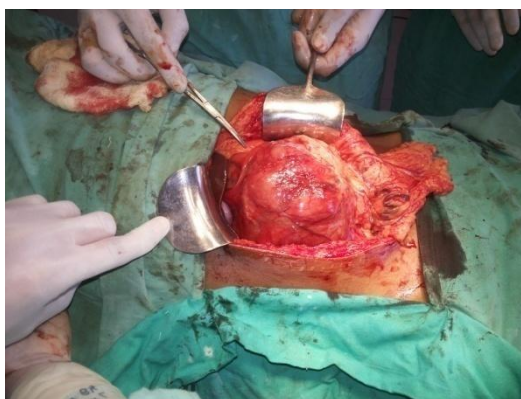


Fig-1: Large mass arising from head of pancreas. Duodenum is compressed over tumor stomach is displaced upward

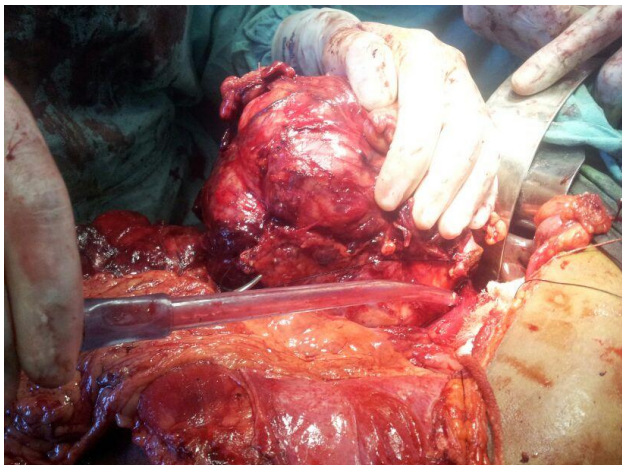


Fig-2: Large tumor displacing the SMV to the left side

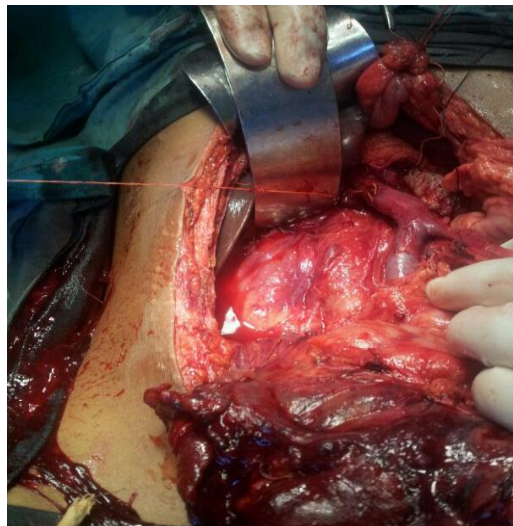


Fig-3: after resection the retroperitoneal tissue shows portal vein and junction of SMV and splenic vein, right kidney is displaced inferiorly.

On histopathological examination

Macroscopically

Tumor of 15*12 cm size (largest PNET in pancreas ever reported) in head of pancreas cut surface is grayish white.

Microscopically

Section from mass reveal a cellular malignant neoplasm composed of small oval to round cell arranged in a dissociated manner nuclei show fine chromatin, occasional mitotic figure is seen, pancreatic tissue seen in one area. All (pancreatic,intestinal,gastric and CBD) resected margin is negative of tumor all LN negative of tumor metastasis(0/8), GB shows feature of chronic cholecystitis

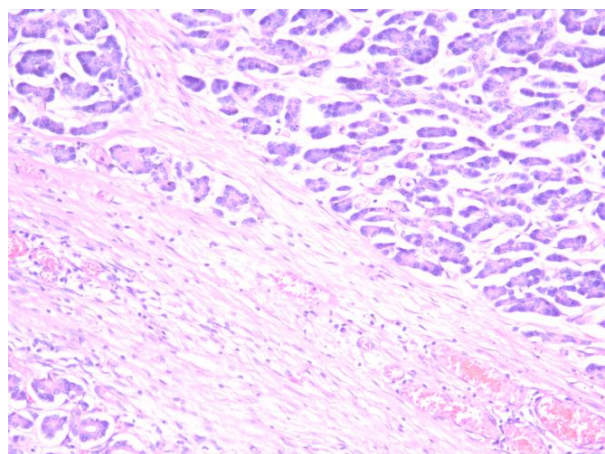
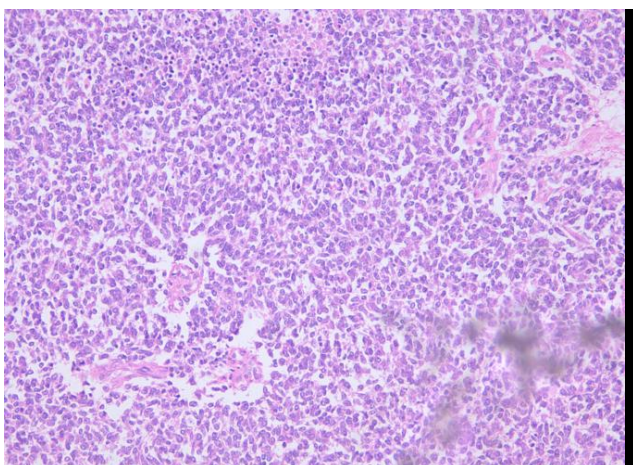


Fig-4 & 5: Sheets of small round cells with enlarged nuclei, fine stippled chromatin, and moderately clear to amphophilic cytoplasm (H&E stain)

On IHC examination

IHC showed tumor was positive for neuron specific enolase, KI 67 and MIC-2 and negative for pancytokeratin and diagnosis was made ewing sarcoma.

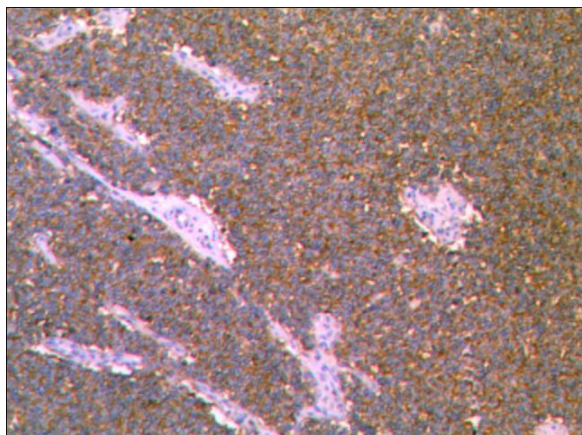


Fig-6: positive for CD-99

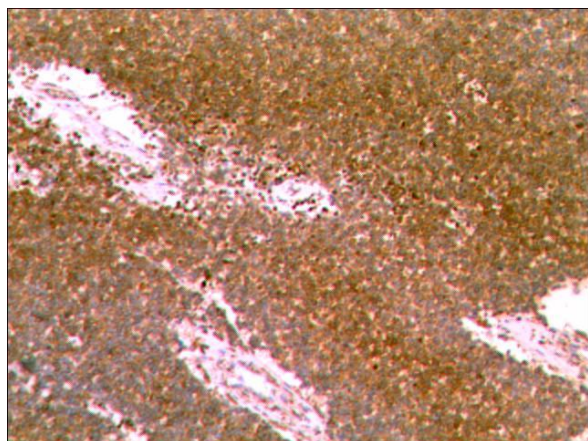


Fig-7: positive for NSE

Post operative course was uneventful and patient was discharged on postoperative day 6. Patient took adjuvant chemotherapy after 3 month of surgery CT is repeated which was normal.

DISCUSSION

Fourteen to eighteen cases of PNET of pancreas has been reported till now [5-14]. the patients ranged in age from 6 to 25 years (mean 18 years). 60% of the patients are male. mainly the patients presented with jaundice and/or abdominal pain. All of the tumors were located in the head of the pancreas, and they ranged in size from 3.5 to 9.0 cm. Light microscopy revealed the typical morphologic features of PNETs. By immunohistochemistry the neoplastic cells in cases expressed O13 (CD99, p30/32MIC2) [3].

Out of 16 cases till now reported most of tumor presented with pain and jaundice [8]. Pain is most consistent symptom [11], 4 presented with pain and mass in abdomen. Upper GI bleeding and anaemia, 2 very young girl age 2 and 6 presented with pubic hair, breast and vaginal bleeding on investigation there is increase estrogen level.

10 of the 16 tumors were located in the head of the pancreas. Tumor size varies from 3 to 15 cm in

largest diameter but in our case this is the largest tumor which is reported is of 15*12 cm size (CT 18*12cm).

CT scan and MRI used to be the investigation of choice in tumor arising from pancreas in our case we also do EUS and FNAC was taken through this which was came to be undifferentiated round cell malignant neoplasm but for PNET/ES image guided core biopsy is more useful for preoperative diagnosis by HPE and IHC study. it may arise any part of pancreas but mostly seen arising from head. Out of 16, 12 tumor was present in head of pancreas and periampullary lesion, 3 in body and tail of pancreas and 1 in uncinata process. Three patient presented with metastasis into the liver at initial presentation and in one tumor was infiltrated into transverse colon. Surgeries were planned according to size and site in pancreas. On microscopy, all cases exhibited same pattern, the sheets or lobules of small round tumor cells with round to oval nuclei and scant cytoplasm characteristic of the EFT. on Immunohistochemical staining all shows CD99 positive. Some proportion of the tumors stained positively for vimentin, cytokeratin and NSE. Focal Homer Wright rosettes were described in two cases. Molecular techniques such as FISH and polymerase chain reaction (PCR) demonstrated abnormalities of the EWSR1 gene in seven cases, and the t(11;22) was detected by conventional karyotyping in movahadi 7 cases series 1 patient died of operative complication, 1 died of disease after 4 year, 1 alive with recurrence at 27 month, 1 alive with no e/o disease at 33 month and 1 who underwent biopsy and adjuvant chemotherapy alive at 43 month. most of patient who timely underwent curative resection and taken adjuvant chemotherapy And they do well 3 to 4 year of follow up. (further followup is not available) and who did not taken adjuvant chemotherapy survival is short and recurrence is high in that cases. Overall there is no data to comment on recurrence and survival and prognosis of pancreatic PNET/ES due to lack of good long follow-up and only because few cases have been reported.

We can give an opinion that any mass arising in young patient in pancreas which is rapidly enlarging we should think of PNET/ES of pancreas as differential diagnosis. Curative resection and adjuvant chemotherapy should be the management and active follow-up for recurrence.

REFERENCES

1. De Alava E, Gerald WL; Molecular biology of the Ewing sarcoma/primitive neuroectodermal tumor family. J Clin Oncol, 2000; 18: 204-213.
2. Reilly C, Zenoni S, Hasan MK, Varadarajulu S, Tran TA, Sebastian G, Arnoletti JP; Primary pancreatic Ewing's sarcoma with portal vein tumor thrombosis. J Gastrointest Surg, 2013; 17(5):1015-1019.
3. Movahedi-Lankarani S, Hruban RH, Westra WH, Klimstra DS; Primitive neuroectodermal tumors of

- the pancreas. A report of seven cases of a rare neoplasm. *Am J Surg Pathol*, 2002; 26:1040–1047.
4. Obuz F, Kovanlikaya A, Olgun N, Sarialioglu F, Özer E; MR imaging of pancreatic metastasis from extraosseous Ewing's sarcoma. *Pancreas*, 2000; 20(1): 102-104.
 5. Bulchmann G, Schuster T, Haas RJ et al (2000) Primitive neuroectodermal tumor of the pancreas. An extremely rare tumor. Case report and review of the literature. *Klin Padiatr* 212: 185–188
 6. Movahedi-Lankarani S, Hruban RH, Westra WH et al.; Primitive neuroectodermal tumors of the pancreas. A report of seven cases of a rare neoplasm. *Am J Surg Pathol*, 2002; 26:1040–1047.
 7. Perek S, Perek A, Sarman K, Tuzun H, Buyukunal E; Primitive neuroectodermal tumor of the pancreas. A case report of an extremely rare tumor. *Pancreatology*, 2003; 2: 352–356.
 8. Welsch T, Mechttersheimer G, Aulmann S, Mueller SA, Buechler MW, Schmidt J, Kienle P; Huge primitive neuroectodermal tumor of the pancreas: report of a case and review of the literature. *World J Gastroenterol*, 2006, 12: 6070–6073.
 9. Schutte WP, Knight PJ; Precocious puberty because of a pancreatic neuroectodermal tumor. *J Pediatr Surg*, 2006; 41:1916–1918.
 10. Menon BS, Juraida E; Pancreatic primitive neuroectodermal tumor associated with precocious puberty. *Pediatr Blood Cancer*, 2009; 53: 518–519.
 11. Doi H, Ichikawa S, Hiraoka A, Ichiryu M, Nakahara H, Ochi H, Hasegawa T, et al.; Primitive neuroectodermal tumor of the pancreas. *Intern Med*, 2009; 48: 329–333.
 12. Jing H, Li F, Chen L, Zhang T, Zhao Y; Detection of recurrent pancreatic primitive neuroectodermal tumor by Tc-99m hydrazinonicotinyl-Tyr3-octreotide scan. *Clin Nucl Med*, 2011; 36: 54–55.
 13. Maxwell L, Hederman A, Jackson C, Sawaya D, Giles H, Nowicki MJ; Uncommon presentation of rare disorder-duodenal ulcer secondary to invasive pancreatic primitive neuroectodermal tumor: case report and review of the literature. *J Pediatr Hematol Oncol* (Epub ahead of print), 2011.
 14. Jayant K, Agrawal S, Agarwal R, Khoiwal S; Pancreatic Ewings Sarcoma-A Dreadful Tumor. *American Journal of Cancer Prevention*, 2013; 1(3): 24-26.
 15. Williams DL, Look AT, Melvin SL, Roberson PK, Dahl G, Flake T, Stass S; New chromosomal translocations correlate with specific immunophenotypes of childhood acute lymphoblastic leukemia. *Cell*, 1984; 36(1):101-109.
 16. Delattre O, Zucman J, Plougastel B, Desmaze C, Melot T, Peter M, Thomas G; Gene fusion with an ETS DNA-binding domain caused by chromosome translocation in human tumours. *Nature*, 1992; 359(6391):162-165.
 17. Tefft M, Vawter GF, Mitus A; Paravertebral "round cell" tumors in children. *Radiology*, 1969; 92:1501–1509.