

Original Research Article

Treatment of Symptomatic Osteochondral Defects of Talus with Arthroscopic Debridement and Microfractures

Abdulla. A. Zahrani

Faculty of Medicine, Taif University, Taif, 21944, KSA

*Corresponding author

Abdulla. A. Zahrani

Email: abdullazahrani@yahoo.com

Abstract: The aim of this study is to report the outcomes of the treatment of OCD of the talus using arthroscopic microfracture technique in King Abdul Aziz specialist Hospital, Taif, Saudi Arabia. Thirty one patients with symptomatic osteochondral defects of the talus were enrolled in this prospective clinical study between the years 2007 and 2015. The patients were treated with arthroscopic debridement and microfracture technique. Demographics, mechanism of injury, lesion characteristics, and the American Orthopaedic and Ankle Society score (AOFAS) was compared for the patients pre and postoperatively. The mean follow up was 36 ± 4 months. Male/female ratio was 1.8/1 with mean age 31.6 ± 6.8 years (median 27.8 years). Trauma was the cause in 77.5% of cases. The mean size of the lesion was 156 mm^2 and the median was 157.8 mm^2 . Medial lesions represented 61.3% of cases. Berndt' and Harty stage II represented 29% of the lesions, stage III was 22.6%, stage IV was 22.6%, and stage V (25.8%). The mean preoperative AOFAS score of all patients was found to be significantly improved postoperatively from 68.6 ± 15.4 to 93.3 ± 20.8 (P value < 0.5). 87.1% of patients were very satisfied from the operation and 12.9% patients were not satisfied. During the period of follow up no major complications were recorded. Arthroscopic debridement and microfracture for treatment of OCD of talus proved to be technically simple, safe and efficient in improving pain and function and the outcome was better in young patients with smaller lesions.

Keywords: osteochondral defects, arthroscopy, microfractures, Taif

INTRODUCTION

Single or multiple trauma leads to injury of the talar cartilage and subchondral bone with partial or complete detachment of the fragment [1, 2]. Similar to the OCD of knee and elbow, the ankle lesions produces ankle pain with variable degrees of functional impairment [3]. Many classifications of the injury are used; however, the most commonly used is Berndt and Harty classification which was based on plain radiography [4]. Originally it involved 4 stages and stage 5 was added by Loomer *et al.* [5].

Treatment of symptomatic osteochondral lesions include the non-surgical treatment with rest or cast immobilization in addition to surgical treatment which utilizes either open or arthroscopic techniques [6]. Recent studies proved that bone marrow stimulation using arthroscopic microfracture technique is a simple successful technique and gained popularity and acceptance among orthopedic surgeons from the beginning of this century [7-10]. The aim of this study is to report the outcomes of the treatment of OCD of the talus using arthroscopic microfracture technique in King Abdul Aziz specialist Hospital, Taif, Saudi Arabia.

PATIENT AND METHOD

Thirty one patients with symptomatic osteochondral defects of the talus were enrolled in this prospective clinical study after approval of the ethical board of the hospital and taking written informed consent from the patient. The study was done between the years 2007 and 2015. Demographics, mechanism of injury, lesion characteristics, and the American Orthopaedic and Ankle Society score (AOFAS) was compared for the patients pre and postoperatively. The AOFAS is not a patient-reported outcome tool and it was designed in 1994 for physicians to standardize the assessments of patients with foot or ankle disorders. It includes total of 100 points; 40 points for pain, 50 points for function and 10 points for Alignment [11].

Clinical history and examination were the first diagnostic tools followed by MRI to confirm the diagnosis, stage, and the size of the lesion. The patients were treated with arthroscopic debridement and microfracture technique [12]. The surgical procedure included arthroscopic exploration of the joint followed by identification of the lesion. Any degenerated or detached cartilages would be excised followed by curettage to stabilize the margins of the defect site prior to marrow stimulation. Following debridement of the

lesion, a microfracture awl was used to perforate the subchondral bone at 3-4-mm intervals to promote vascularization (Figures, 1-3). Any created loose bony particles which might act as loose bodies within the joint were properly removed. The mean follow up was 36±4 months.

Statistical analysis

SPSS 20.0 (SPSS, Chicago Illinois) was used for carrying out statistical analysis. Group differences were further analyzed by χ^2 and difference between means of continuous variables was tested by Student's t test. Pearson and Spearman's correlation tests were used to correlate between each parameter and different variants in the same group to find significant differences. Univariate analysis is used to correlate the changes in AOFAS with the patient stage. Level of significance was determined at $P < 0.05$.

RESULTS

Table 1 shows the demographics and preoperative patients' findings. Table 2 shows that the mean preoperative AOFAS score of all patients was found to be significantly improved postoperatively from 68.6±15.4 to 93.3±20.8 (P value < 0.5). The AOFAS score shows a highly significant correlation with the age (better in patients $<$ median age) and the size of the lesion (better in lesions $<$ median size) without significant variation in gender or the lesion site (medial or lateral). Univariate analysis failed to find a significant correlation between the score and the patient stage (Table 3). Twenty seven patients (87.1%) were very satisfied and satisfied from the operation and 12.9% of patients were not satisfied due to residual pain. During the period of follow up no major complications were recorded

Table-1: Patients' demographics and Preoperative findings

Demographics	
Patients number	31 (100)
Gender	
Male	20/31 (64.5)
Females	11/31 (35.5)
Mean age (±SD)	31.6±6.8 years
Median age	27.8 years
Preoperative findings	25/31(77.5)
History of trauma	8.5±1.7months
The mean preoperative duration of symptoms (±SD)	All patients (3 months or more)
Preoperative conservative treatment	
Preoperative patient stages	
- Stage II	9/31 (29)
- Stage III	7/31(22.6)
- Stage IV	7/31(22.6)
- Stage V	8/31(25.8)
Medial lesions	19/31 (61.3)
Mean diameter of the lesion (Mean surface area)	13.9 mm (156 mm ²)
Median diameter of the lesion (Median surface area)	14.0 mm (157.8 mm ²)
The mean preoperative AOFAS score (±SD)	66.6±15.4

SD; standard deviation, AOFAS; American Orthopaedic and Ankle Society

Table-2: Preoperative/postoperative changes in the mean AOFAS score in different patient groups

Patients' group	Preoperative Mean ± SD	Postoperative Mean ± SD	P-value (Significance)
For all patients	66.6±15.4	93.3±20.8.	<0.05 (S)
Patients < median age	66.8±14.2	97.7±18.6	<0.001 (HS)
Patients > median age	67.5±8.3	87.4±15.9	<0.05 (S)
Lesion < median surface area (157.8 mm ²)	64.1±9.3	97,9±12.4	<0.001 (HS)
Lesion >median surface area (157.8 mm ²)	68.9±14.7	89.5±12.4	<0.05 (S)
Medial lesions	68.4±12.9	91.9±15.3	<0.05 (S)
Lateral lesions	64,9±11.1	94.1±20.5	<0,05(S)
Males	64.7±14.8	93.5±17.3	<0.05 (S)
Females	69.9±13.2	91.4±18.9	<0.05 (S)

S; significant, IS; insignificant, HS; highly significant

Table -3: Univariate analysis of changes in AOFAS score as continuous and categorical variables in relation to the patient stage

Variables	Preoperative/postoperative mean AOFAS score		
	HR	(95% CI)	P value
Continuous	1.016	(1.009–1.018)	<0.05
Categorical			
Stage II (95.3±18.7)	1.605	(0.931–2.055)	0.128
Stage III (92.7±19.8)	1.558	(0.876–2.221)	0.134
Stage IV (92.1±16.5)	1.776	(0.749–2.069)	0.244
Stage V (93.2±17.2)	1.456	(0.853-2.240)	0.126

CI, confidence interval, HR, hazard ratio, AOFAS; American Orthopaedic and Ankle Society

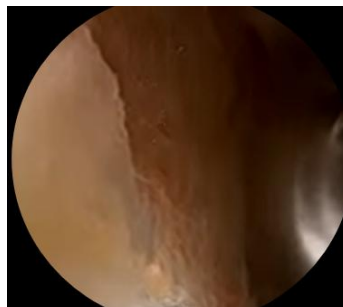

Fig-1: Curettage to stabilize the margins of the defect site

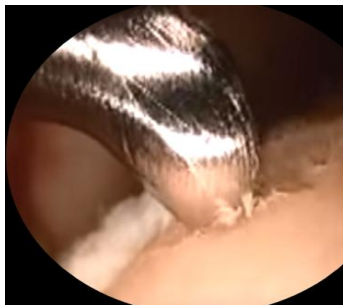


Fig-2: Microfracture awl was used to perforate the subchondral bone

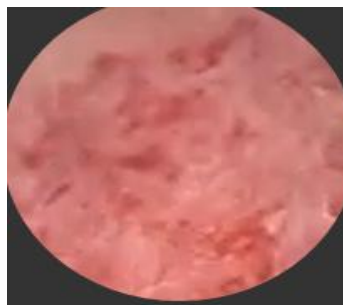

Fig-3: The created microfractures with 3-4 mm intervals

DISCUSSION

Osteochondral defects are rare conditions and the talus is the third site to be affected after knee and elbow with an incidence of 4% of all osteochondral lesions in the body; however, they have been found in more than 40% of patients after operative treatment of ankle fractures [1-3]. The rarity of this disorder explains

the small sample size in this study and several other studies [1].

History of trauma is found in more than 85% of cases [1] which are slightly higher than the findings in this study.

Persistent pain, swelling, and even instability are the commonest presentation and more severe symptoms as catching and grinding indicate possible loose body, though some cases are asymptomatic [3,13,14]. In this study all cases were symptomatic.

The hyaline articular cartilage and its underlying subchondral bone are affected in the talar OCD and according to Berndt and Harty study; the medial talar dome was affected in 57% of lesions and located laterally in 43% of cases [4]. In the present study medial lesions was slightly higher which may be related to limited number of the present cases. Raikin *et al.* suggested that higher contact pressures medial to the equator of the talar dome increase the likelihood of development of an OCD in this site [13].

Patients with an acute or chronic ankle pain should first undergo plain radiography which can be used to detect bony defects in the talar dome, but, will fail to detect a purely cartilaginous injury and underlying bone edema [15, 16].

MRI is the most sensitive diagnostic test and it is more specific than plain X-rays and CT and it can be used to identify lesions in bone and cartilage as well as associated ligament injuries. If X-rays are normal and an OLT is suspected, MRI is the next appropriate study [16, 17].

Berndt and Harty's original classification is based on plain radiography and Loomer *et al.* added stage V to this system [4,5]. The classification involves; Stage I: Subchondral compression (fracture) Stage II: Partial detachment of osteochondral fragment Stage III: Completely detached fragment without displacement from fracture bed Stage IV: Detached and displaced fragment Stage V: Subchondral cyst [5].

Other classification systems were developed as Ferkel and Sgaglione classification system based on CT, Hepple MRI classification [15,16]. Arthroscopic grading systems have also been developed; however, their usefulness depends on correlation to MRI findings and CT as some deep lesions may be present with intact overlying cartilage [17,18]. In this study the patient was diagnosed and staged according to plain radiography and confirmed by MRI.

Most of the authors recommend conservative treatment for Berndt and Harty type I and II lesions and small grade III lesions and consider that large grade III and any grade IV lesions in addition to patients with failed conservation are operative candidates [6, 19]. In the present study the mean duration of symptoms before arthroscopy were 8.5 ± 1.7 months and all patients experienced failure of conservative treatment for at least 3 months.

Tol *et al.* in their systematic review recorded a good success rate for nonoperative treatment and this percentage are considered by some investigators enough to suggest conservative treatment for all patients except those with loose body [19].

Surgical treatment aims at restoration of the talar dome to allow normal reactivity of the joint and prevents development of arthrosis [6-10, 19] Operative treatment involves, primary repair which works best for large OCD lesions if the cartilage is attached to a bone and appears healthy; however, it fails in sclerotic chronic lesions [10].

Autogenous osteochondral graft can be utilized to restore the integrity of the cartilaginous surface but carries the risk of second operative site [21].

Recent evolving techniques include; autologous chondrocyte implantation (ACI) or utilizing the collagen matrix to deliver the chondrocytes (MACI) [22, 23].

Marrow stimulating techniques have been used to treat OCD since 1959 when Pridie introduced the subchondral drilling [24]. Drilling gained popularity in 90s; however, since 2000 microfracturing has gained acceptance after being introduced by Steadman *et al.* as it carries the advantage as drilling in stimulating the bone marrow and avoids its thermal necrotic effect [25]. After sufficient debridement microfractures can be done by using drills or awls to perforate the base of the lesion and bring mesenchymal stem cells, growth factors, and healing proteins to the defect which eventually forms the fibrocartilage that fills the OCD [22, 23, 25]. Awls have a curved ends so it can treat the defects around the corner which cannot be reached by the drills [7,10]. Saxena *et al.* [26] and Lee *et al.* [8] verified in their study that debridement and microfracture had good to excellent outcome in 96% and 89% of cases respectively. In the present study a comparable success rate of 87.1% was achieved with patient satisfaction due improvement of pain and function. This study verified the significant correlation of postoperative improvement with younger age group of patients and those with lesions smaller than 157.8 mm^2 (median surface area in this study). Furthermore, 3 of the unsatisfied patient in this study had a lesions $>$ median surface area. Other studies found that lesions $>150 \text{ mm}^2$ had inferior outcome than smaller lesions [27, 28]. The variation in size between the results of this study and other studies may be related to the difference in sample size and patient characteristics. However, Polat *et al.* found no significant correlation between the size of the lesion and the long-term results of microfracture in the treatment of talus osteochondral lesions [29].

Our study found no significant correlation with gender, lesion site, and the patient stage.

Most of the studies [7-10, 20, 25-29] found that microfracturing technique was technically simple with low cost, safe, and had minimal postoperative pain which is in accordance with the findings of this study.

CONCLUSION

Arthroscopic debridement and microfracture for treatment of OCD of talus proved to be technically simple, safe and efficient in improving pain and function and the outcome was better in young patients with smaller lesions.

REFERENCES

1. Steinhagen J, Niggemeyer O, Bruns J. Ätiologie und Pathogenese der Osteochondrosis dissecans tali. *Der Orthopäde*. 2001 Jan 1;30(1):20-7.
2. Schachter AK, Chen AL, Reddy PD, Tejwani NC. Osteochondral lesions of the talus. *Journal of the American Academy of Orthopaedic Surgeons*. 2005 May 1;13(3):152-8.
3. Thomas JL, Christensen JC, Kravitz SR, Mendicino RW, Schuberth JM, Vanore JV, Weil LS, Zlotoff HJ, Bouché R, Baker J. The diagnosis and treatment of heel pain: a clinical practice guideline—revision 2010. *The Journal of Foot and Ankle Surgery*. 2010 Jun 30;49(3):S1-9.
4. Berndt AL, Harty M. Transchondral fractures (osteochondritis dissecans) of the talus. *J Bone Joint Surg Am*. 1959 Oct 1;41(7):1363-.
5. Loomer R, Fisher C, Lloyd-Smith R, Sisler J, Cooney T. Osteochondral lesions of the talus. *The American Journal of Sports Medicine*. 1993 Jan 1;21(1):13-9.
6. Zengerink M, Struijs PA, Tol JL, Van Dijk CN. Treatment of osteochondral lesions of the talus: a systematic review. *Knee Surgery, Sports Traumatology, Arthroscopy*. 2010 Feb 1;18(2):238-46.
7. Becher C, Thermann H. Results of microfracture in the treatment of articular cartilage defects of the talus. *Foot & ankle international*. 2005 Aug 1;26(8):583-9.
8. Lee KB, Bai LB, Chung JY, Seon JK. Arthroscopic microfracture for osteochondral lesions of the talus. *Knee Surgery, Sports Traumatology, Arthroscopy*. 2010 Feb 1;18(2):247-53.
9. Cerynik DL, Lewullis GE, Joves BC, Palmer MP, Tom JA. Outcomes of microfracture in professional basketball players. *Knee Surgery, Sports Traumatology, Arthroscopy*. 2009 Sep 1;17(9):1135-9.
10. Donnerwerth MP, Roukis TS. Outcome of arthroscopic debridement and microfracture as the primary treatment for osteochondral lesions of the talar dome. *Arthroscopy: The Journal of Arthroscopic & Related Surgery*. 2012 Dec 31;28(12):1902-7.
11. SooHoo NF, Vyas R, Samini D. Responsiveness of the foot function index, AOFAS clinical rating systems, and SF-36 after foot and ankle surgery. *Foot & ankle international*. 2006 Nov 1;27(11):930-4.
12. van Bergen CJ, de Leeuw PA, van Dijk CN. Potential pitfall in the microfracturing technique during the arthroscopic treatment of an osteochondral lesion. *Knee Surgery, Sports Traumatology, Arthroscopy*. 2009 Feb 1;17(2):184-7.
13. Raikin SM, Elias I, Zoga AC, Morrison WB, Besser MP, Schweitzer ME. Osteochondral lesions of the talus: localization and morphologic data from 424 patients using a novel anatomical grid scheme. *Foot & Ankle International*. 2007 Feb 1;28(2):154-61.
14. Ferkel RD, Lutter LD. Arthroscopic Surgery: The Foot & Ankle. *Foot & Ankle International*. 1996 Oct 1;17(10):651-2.
15. Hepple S, Winson IG, Glew D. Osteochondral lesions of the talus: a revised classification. *Foot & ankle international*. 1999 Dec 1;20(12):789-93.
16. Mintz DN, Tashjian GS, Connell DA, Deland JT, O'Malley M, Potter HG. Osteochondral lesions of the talus: a new magnetic resonance grading system with arthroscopic correlation. *Arthroscopy: The Journal of Arthroscopic & Related Surgery*. 2003 Apr 30;19(4):353-9.
17. Verhagen RA, Maas M, Dijkgraaf MG, Tol JL, Krips R, van Dijk CN. Prospective study on diagnostic strategies in osteochondral lesions of the talus. *Bone & Joint Journal*. 2005 Jan 1;87(1):41-6.
18. Reilingh ML, van Bergen CJ, Blankevoort L, Gerards RM, van Eekeren IC, Kerkhoffs GM, van Dijk CN. Computed tomography analysis of osteochondral defects of the talus after arthroscopic debridement and microfracture. *Knee Surgery, Sports Traumatology, Arthroscopy*. 2016 Apr 1;24(4):1286-92.
19. Tol JL, Struijs PA, Bossuyt PM, Verhagen RA, Van Dijk CN. Treatment strategies in osteochondral defects of the talar dome: a systematic review. *Foot & Ankle International*. 2000 Feb 1;21(2):119-26.
20. Ferkel RD, Zanotti RM, Komenda GA, Sgaglione NA, Cheng MS, Applegate GR, Dopirak RM. Arthroscopic treatment of chronic osteochondral lesions of the talus long-term results. *The American Journal of Sports Medicine*. 2008 Sep 1;36(9):1750-62.
21. Al-Shaikh RA, Chou LB, Mann JA, Dreeben SM, Prieskorn D. Autologous osteochondral grafting for talar cartilage defects. *Foot & ankle international*. 2002 May 1;23(5):381-9.
22. Ahmed TA, Hincke MT. Strategies for articular cartilage lesion repair and functional restoration. *Tissue Engineering Part B: Reviews*. 2010 Jan 27;16(3):305-29.
23. Hunziker EB, Lippuner K, Keel MJ, Shintani N. An educational review of cartilage repair: precepts & practice—myths & misconceptions—progress &

- prospects. Osteoarthritis and Cartilage. 2015 Mar 31;23(3):334-50.
24. Pridie KH, Gordon G. A method of resurfacing osteoarthritic knee joints. In *Journal of Bone and Joint Surgery-British Volume* 1959 Jan 1 (Vol. 41, No. 3, pp. 618-619). 22 BUCKINGHAM STREET, LONDON WC2N 6ET, ENGLAND: BRITISH EDITORIAL SOC BONE JOINT SURGERY.
 25. Steadman JR, Rodkey WG, Rodrigo JJ. Microfracture: surgical technique and rehabilitation to treat chondral defects. *Clinical orthopaedics and related research*. 2001 Oct 1;391:S362-9.
 26. Saxena A, Eakin C. Articular Talar Injuries in Athletes Results of Microfracture and Autogenous Bone Graft. *The American journal of sports medicine*. 2007 Oct 1;35(10):1680-7.
 27. Chuckpaiwong B, Berkson EM, Theodore GH. Microfracture for osteochondral lesions of the ankle: outcome analysis and outcome predictors of 105 cases. *Arthroscopy: The Journal of Arthroscopic & Related Surgery*. 2008 Jan 31;24(1):106-12.
 28. van Bergen CJ, de Leeuw PA, van Dijk CN. Treatment of osteochondral defects of the talus. *Revue de Chirurgie Orthopédique et Réparatrice de l'Appareil Moteur*. 2008 Dec 31;94(8):398-408.
 29. Polat G, Erşen A, Erdil ME, Kızılkurt T, Kılıçoğlu Ö, Aşık M. Long-term results of microfracture in the treatment of talus osteochondral lesions. *Knee Surgery, Sports Traumatology, Arthroscopy*. 2016 Apr 1;24(4):1299-303.