

Case Report

Metallic Ring Occlusion of Penis: Initial Fantasy, Later NightmareMayank Mishra¹, Neeraj Sharma², Vivekanand Rai³, Alok Tripathi¹, Vikas Trivedi¹, Anil Keshri¹, Pushpendra Singh²¹Assistant Professor Department of Surgery, Heritage IMS, Varanasi, India²Senior Resident, Department of Surgery, Heritage IMS, Varanasi, India³Associate Professor, Department of Surgery, Heritage IMS, Varanasi, India***Corresponding author**

Neeraj Sharma

Email: neeraj8005479284@gmail.com

Abstract: Penile incarceration has been reported in various age groups, with incarcerating object most frequently placed for erotic or auto-erotic purpose or psychiatric patients. The ring is inserted when penis is flaccid and it becomes irremovable after erection. We encountered one patient in Heritage IMS Emergency Department, who presented with three metallic rings, which were present at penile base. It was removed after tiresome and conscious cutting of ring. The management along with discussion of relevant literature is present here.

Keywords: penile, Incarceration, Metallic, ring.

INTRODUCTION

Penile incarceration due to various objects are lesser known entities both in literature and clinical practice due to social stigma attached with the practice, which causes delay in presentation and leads to more complicated course of management and further increases the complication rate. The ring is inserted when penis is flaccid and it becomes irremovable after erection [1]. Constricting devices placed on the penis present a daunting challenge to surgeons. Usually various types of metallic and non-metallic objects are placed on the penis to increase sexual performances or because of autoerotic intentions. We came across one such patient with very thick 3 metallic rings. Being an uncommon entity, it is being reported with review of the relevant literature.

CASE REPORT

A 47-year-old man presented to Emergency Department at 3 AM with complaints of severe penile discomfort, swelling, and retention of urine. Patient was married but having legal marital issues. He had inserted 3 metallic rings on his penis about 12 hours back. Therefore the penis had swollen, and he was unable to pass urine. He was in severe agony. On examination there was a thick metallic ring at the penile base. The penis was grossly swollen. And there was a palpable bladder lump. He was immediately shifted to operation theatre. A penile block was given, and the patient was sedated. Under antibiotic cover, we aspirated blood from corpora by 18 gauge needle. Besides, manual compression was done to drain penis from puncture site using lignocaine jelly lubrication but it failed. In the

meantime, about 500 ml of urine was aspirated through suprapubic area, to relieve the patient from acute urinary retention.

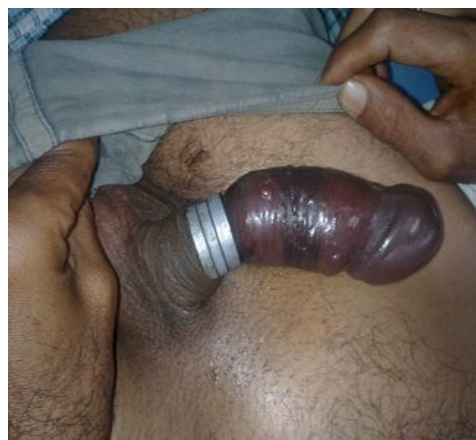

Fig-1: Three steel rings at the base of penis with Proximal penile edema and superficial skin gangrene

Following futile attempts of manual removal we planned for cutting of rings. No surgical instruments were of the match, then it was tried with day to day used saw but due to fear of penile injury it was abandoned. An orthopaedic jumbo cutter was used and rings were cut bit by bit in 3 hours. On examination superficial damage was limited to patchy penile skin necrosis. The patient was catheterised post-surgery. On third day, following a successful trial without catheter, he was discharged with oral medication. Patient had no problem in subsequent follow up.

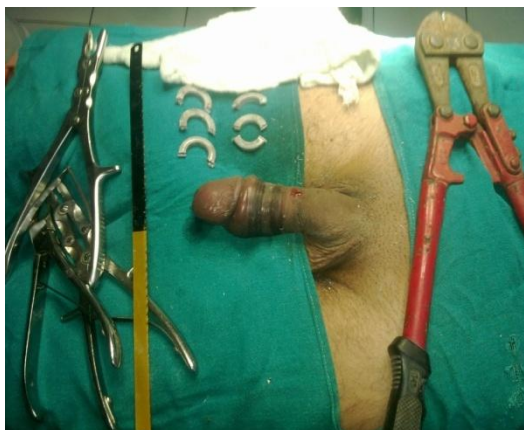


Fig 2: Rings removed after cutting

DISCUSSION

Penile incarceration or strangulation is a rare urological emergency with only 60 cases reported in the literature to date.

Increased oedema distal to occlusion restrict venous and lymphatic outflow. Ultimately, the constriction may obstruct arterial supply and may result in penile gangrene. Apart from vascular compromise, urethral compression will lead to acute urinary retention, which may aggravate the problem.

A wide variety of objects had been reported in literature. These comprise plastic and steel rings, ball-bearings, nuts, washers, wedding rings, bottles and rubber bands [2-4].

The patient presents with severe agony, which is due to vascular and urinary compromise. The treatment of this condition involves removal of the constricting rings. This may be easy in cases where cause can be easily removed such as plastic material. However, if the obstruction is due to metallic rings, it becomes a tedious situation. Usually a ring cutting instrument is advocated such as saw [5]. Besides these, orthopaedic drill [10], dental drill [6], and pliers [7] has been used. Even a pedal cutter used by the fire crew, has also been used. Postoperative observation period is important for fear of partial or total penile loss. Occurrence of urethral fistula has also been reported [8].

To conclude this unusual presentation is an acute emergency. It needs all out attention to the patients. Proper treatment, as the available resources, may provide satisfactory result. Proper postoperative care is important for the taking care of any complication, if it arises

REFERENCES

1. Sathesh-Kumar T, Hanna-Jumma S, De Joya N, Saleemi A. Genitalia strangulation-firemen to the rescue!. *Ann R CollSurg Engl.* 2009;91:W15-6.

2. Cassidy D, Mador D. Genital incarceration: an unusual case report. *Can Urol Assoc J.* 2010;4:E76-8.
3. Perabo F, Steiner G, Albers P, Muller S. Treatment of penile strangulation caused by a constricting devices. *Urology.* 2002;59:137.
4. Kadioglu A, Cayan S, Ozcan F, Tellaglu S. treatment of penile incarceration in an impotent patients. *IntUrolNephrol.* 1995; 27:639-41.
5. McLaughlin T, Coyner W. removal of a strangulating metal bearing from the penis. *J Urol.* 1989; 141:617.
6. Huang J, Holt D, Philp T. penile constriction by foreign bodies : the use of a dental drill. *Br J Urol.* 1997; 79:801.
7. Kore R, Blacklock A. ring the fire brigade. *Br J Urol* 1996;78:948.
8. Tash J, Eid J. urethrocutaneous fistula due to a retained ring of condom. *Urology.* 2000;56:508.
9. McLaughlin T, Coyner W. Removal of a strangulating metal bearing from the penis. *J Urol.* 1989;141(3):617.
10. Detweiler, M. Penile incarceration with metal objects a review of procedure choice based on penile trauma grade. *Scand J Urol Nephrol.* 2001; 35: 212-217.