

Paratesticular Liposarcoma Presenting As Inguinal Hernia

Kamal Moufid*, Najib Abbaka, Driss Touiti

Department of urology, Military Hospital Avicenne- Marrakech, Morocco

Case Report***Corresponding author**

Kamal Moufid

Article History

Received: 13.04.2018

Accepted: 23.04.2018

Published: 30.04.2018

DOI:

10.21276/sasjs.2018.4.4.2



Abstract: Primitive scrotal liposarcomas have been previously described, usually in the absence of an inguinal hernia but sometimes in the presence of a hernia. A 47-year-old man was referred to our hospital with the chief complaint of a painless right scrotal swelling and mass slowly growing since 2 months. A gross mass was palpable which was suspected of hernia, and under this mass there was right testis. On ultrasonography (US), the mass was capsulated, solid and heterogeneous with hypo-echoic nodule. Diagnosis of lipoma or liposarcoma was suggested and therefore, a right radical orchiectomy after high ligation of spermatic cord was performed followed by adjuvant wide excision of the hemiscrotum including inguinal soft tissues and nodes. Post-operative period was unremarkable. The patient is well and with no evidence of recurrence 2 years after the operation.

Keywords: Paratesticular, liposarcoma, sarcoma, inguinal.

INTRODUCTION

The paratesticular region is a complex anatomical area which includes the contents of the spermatic cord, testicular tunics, epididymis and vestigial remnants, e.g. the appendices epididymis and testis. Malignant tumours of the pretesticular region are uncommon. The spermatic cord is a rare site of origin, accounting for about 3-7% of all lip sarcomas [1, 2]. Spermatic cord sarcoma is often misdiagnosed by the urologists due to its rarity.

We report a rare case of paratesticular liposarcoma with the clinical symptomatology of an inguinal hernia. The treatment was surgical and included radical orchiectomy and wide excision of the tumor mass to the macroscopically healthy margins.

CASE REPORT

A 47-year-old man was referred to our hospital with the chief complaint of a painless right scrotal swelling and mass slowly growing since 2 months. A gross mass was palpable which was suspected of hernia, and under this mass there was right testis.

Clinical examination showed 10×8 cm right sided inguinoscrotal swelling that was firm in consistency, smooth surfaced, non-fluctuant, non-transilluminant, partially reducible and had a palpable impulse on coughing. On ultrasonography (US), the mass was capsulated, solid heterogeneous with hypoechoic nodules.

Based on the US findings, diagnosis of lipoma or liposarcoma was suggested and therefore, we performed a right radical orchiectomy after high ligation of spermatic cord (figure 1). Surgery revealed a bulky tumor with yellowish color arising from the spermatic cord with no involvement of the testis or epididymis. The weight of the mass was 302 g. Radical orchiectomy was completed at the same time by adjuvant wide excision of the hemiscrotum including inguinal soft tissues and nodes (figure 2).

Histopathological diagnosis was dedifferentiated liposarcoma of the spermatic cord with no malignant cells found in any of the surgical margins and no tumoral involvement of inguinal tissues and lymph nodes. A metastatic workup at this time included a computed tomographic scan of the abdomen and pelvis, a chest radiograph, and bone scan. No evidence of metastatic disease was found. Follow-up was unremarkable. The patient is well and with no evidence of recurrence 2 years after the operation.

LEGENDE OF FIGURES

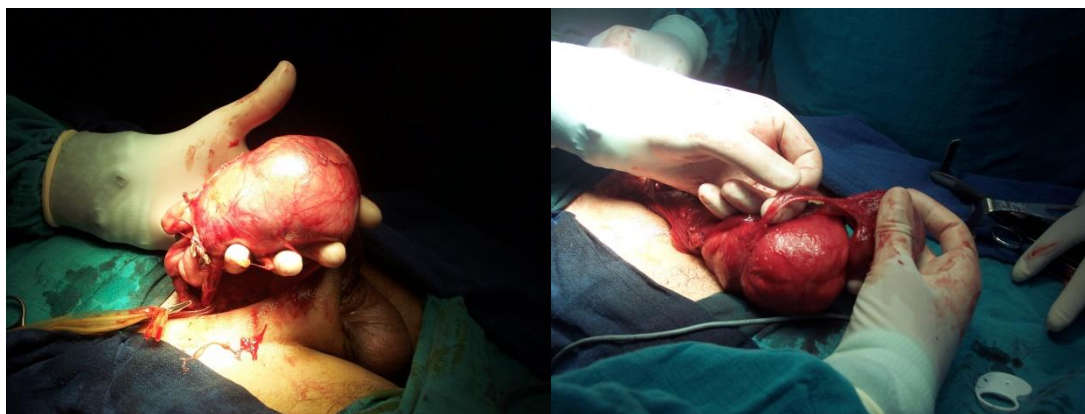


Fig-1, 2: Extirpation of a bulky tumor with yellowish color managed by right radical orchiectomy after high ligation of spermatic cord

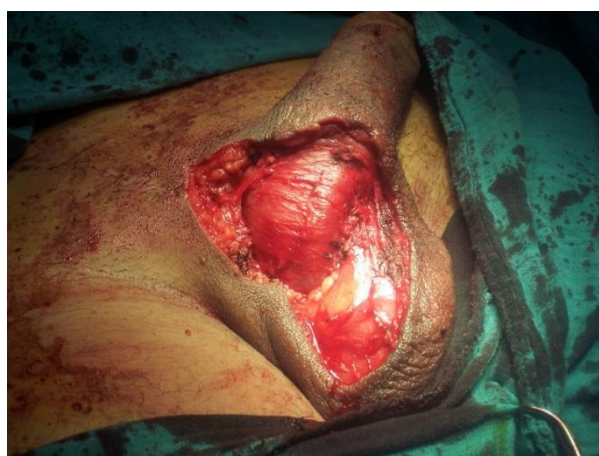

Fig-3: Right hemiscrototomy

DISCUSSION

The pretesticular region may be involved by any type of soft-tissue neoplasm. In reviewing the published series of sarcomas, leiomyosarcoma (32%) followed by rhabdomyosarcoma (24%) and liposarcoma (20%), are the commonest reported histological subtypes [1, 2]

These tumours may arise *de novo* from the adipose tissue around the spermatic cord or by malignant transformation of a pre-existing lipoma [3, 4]. Primitive scrotal liposarcomas have been previously described, usually in the absence of an inguinal hernia but sometimes in the presence of a hernia [4, 5].

The incidence of liposarcomas in patients with inguinal hernia is difficult to assess. Incidental liposarcomas were found in nearly 0.1% of the patients who had inguinal herniorrhaphies [4-6]. In the inguinal region of patients with inguinal hernias a lipoma is almost always present.

In long-standing hernias, it is possible that the mechanical rubbing of the hernial contents on the hernial sac and the pretesticular tissues can produce

chronic inflammation and, over years, can play a part in the formation of scrotal lip sarcoma cells [3-7].

Liposarcomas are usually low-grade, well-differentiated lesion that spread by local extension; however, high-grade tumors may spread by hematogenous and lymphatic routes.

Most pretesticular lip sarcomas are well differentiated. They typically present in older adults as a large fatty appearing mass, although the fatty nature may be less appreciable in tumours with a large fibrous component (sclerosing liposarcoma). Well-differentiated liposarcoma grow slowly, but tend to recur if incompletely excised. Patients most commonly present with firm, painless, slow-growing fluctuant masses. This tumour usually occurs after the fifth decade 2-5.

US appearance is non-specific and US demonstrates a predominantly hyperechoic area, although echogenicity may vary. CT and MR imaging aid in the staging of this neoplasm and help distinguish the fatty and soft-tissue components of the tumour [6, 7].

The treatment of choice remains hemicoectomy with wide excision of soft tissues and nodes. Retroperitoneal lymphadenectomy is not indicated owing to the low malignancy potential of the sarcomas. Radiotherapy may be indicated in some cases. Chemotherapy does not appear to be useful in this type of tumour [2, 4, 5].

The importance of long-term follow-up cannot be overemphasized, according to the propensity of rate of local recurrence.

CONCLUSION

The clinical aspect is frequently a complaint of scrotal or inguinal painless mass, mimicking to an inguinal hernia and the diagnosis of tumour is performed mainly during surgery. In the case of a firm not reducible painless inguinal mass without signs and symptoms of bowel obstruction, an abdominal tumour with inguinal or scrotal extension should be suspected and preoperatively excluded. The US and CT scan may be helpful to plan a correct therapeutic strategy before intervention.

A recommendation is made for preoperative evaluation of the retroperitoneal space prior to extirpation of supra-testicular spermatic cord masses.

REFERENCES

1. Fitzgerald S, Maclennan GT. Para testicular lip sarcoma. *J Urol.* 2009; 1:331-2.
2. Wang J, Du YP, Li SX, Hu JH, Wang CX. Recurrent pretesticular dedifferentiated lip sarcoma after contralateral radical orchiectomy. *Asian J Androl.* 2018 Apr 3.
3. Li Z, Zhou L, Zhao L, Chen P, Liu Y, Ding Y, Sun S, Yang S, Lai Y. Giant pretesticular lip sarcoma: A case report and review of the literature. *Mol Clin Oncol.* 2018 Apr;8(4):617-622.
4. Thomas KL, Gonzalez RJ, Henderson-Jackson E, Caracciolo JT. Para testicular Lip sarcoma Masquerading as an Inguinal Hernia. *Urology.* 2018 Mar; 113:e5-e6.
5. Andersen MFB, Fode M, Pilt AP, Azawi NHM. Liposarcoma in the spermatic cord presenting as an inguinal swelling. *Transl Androl Urol.* 2017 Oct;6(5):978-980.
6. Dotan ZA, TAL R, Golijanin D, Snyder ME, Antonescu C, Brennan MF, Russo P. Adult genitourinary sarcoma: the 25-year Memorial Sloan-Kettering experience. *J Urol* 2006 176: 2033-8.
7. Cariati A, Brignole E, Tonelli E, Marco F. Giant pretesticular undifferentiated lip sarcoma that developed in a long standing inguinal hernia. *Eur J Sur* 2002; 168:511-512.