

Therapeutic and Prognostic Aspects of Acute Generalized Peritonitis at the Referral Health Center (CSRéf) of Ouélessébougou

Dakouo E^{1*}, Malle S², Sangaré S⁵, Dicko A³, Sidibé A¹, Diarra T¹, Sylla O Y⁴, Konaté M⁶, Traoré A⁶, Dembélé B⁶, Togo P⁶, Kanté L⁶

¹Department of Surgery, CSRéf Ouélessébougou

²Department of Ophthalmology, CSRéf Ouélessébougou

³Gynecology-Obstetrics Department, CSRéf Ouélessébougou

⁴Anesthesia and Resuscitation Department, CSRéf Ouélessébougou

⁵Imaging Department, CSRéf Ouélessébougou

⁶General Surgery Department, CHU Gabriel Touré

DOI: <https://doi.org/10.36347/sasjs.2024.v10i10.007>

| Received: 25.07.2024 | Accepted: 02.09.2024 | Published: 14.10.2024

*Corresponding author: Dr. Emmanuel Dakouo

Surgeon at the Department of Surgery, Referral Health Center of Ouélessébougou, Mali

Abstract

Original Research Article

Our objectives were to determine the hospital frequency, describe the clinical, diagnostic, and therapeutic aspects, and assess the postoperative outcomes. **Methods:** The study took place in the surgery department of the CSRéf of Ouélessébougou. It was a descriptive, analytical, and retrospective study over a 26-month period, from June 2021 to October 2023, including all patients operated on for acute peritonitis with an exploitable medical record. **Results:** During the study period, 182 patients underwent emergency surgery, of which 43 cases were for acute peritonitis, a frequency of 0.44%. The average age was 28.58 ± 16.53 years, ranging from 7 to 70 years. The age group of 01 to 30 years was the most represented, accounting for 60.5%. The majority of patients were male (65%). All patients presented with abdominal pain, associated with vomiting as a functional symptom. The initial site of pain was in the right iliac fossa in 48.8% of patients. ASP (Abdomen without Preparation) was performed on 33 patients, revealing diffuse greyness in all these patients and an interhepatic-diaphragmatic gas crescent in 11 patients. Ultrasound was performed in 21 patients (49%), especially when the clinical diagnosis was unclear. General anesthesia was administered to all patients. Appendicular etiology was identified in 46.5% of cases. The majority of patients had a good prognosis according to the Mannheim Peritonitis Index (MPI) in 97.7% of cases. Postoperative outcomes were uncomplicated in 72.1% of patients, but 23.3% experienced parietal suppuration.

Keywords : Surgery, Generalized Acute Peritonitis, Prognosis.

Copyright © 2024 The Author(s): This is an open-access article distributed under the terms of the Creative Commons Attribution 4.0 International License (CC BY-NC 4.0) which permits unrestricted use, distribution, and reproduction in any medium for non-commercial use provided the original author and source are credited.

INTRODUCTION

Peritonitis is an acute inflammation of the peritoneum, most often secondary to the perforation of a digestive organ or the spread of an intra-abdominal septic focus [1]. It is considered generalized when it extends to the entire peritoneal cavity. This is a life-threatening emergency requiring rapid hospitalization and therapeutic intervention [2]. It ranks third among acute surgical abdomens after appendicitis and intestinal obstruction [3]. In France, its frequency is estimated at 3% [4] of all acute surgical emergencies. In Africa, peritonitis frequency in Niger is reported at 28.8% [6], and a 2022 study in Mali at CSRéf Bougouni showed a frequency of 39.8% [7]. In Sikasso, peritonitis frequency was estimated at 54.7% [8]. The treatment of this infectious acute pathology involves resuscitation measures, surgical eradication of intra-peritoneal

infectious foci, and prolonged, adapted antibiotic therapy [10]. The prognosis of secondary generalized peritonitis depends as much on the cause and patient condition as on the timeliness of treatment [2].

OBJECTIVES

Our objectives were to determine the hospital frequency, describe the clinical and therapeutic aspects, and evaluate the cost of treatment.

PATIENTS AND METHODS

This was a descriptive, analytical, and retrospective study over 26 months (June 2021 to October 2023), including all patients operated on for acute peritonitis with an exploitable medical record at CSRéf of Ouélessébougou. Patients operated on for other

Citation: Dakouo E, Malle S, Sangaré S, Dicko A, Sidibé A, Diarra T, Sylla O Y, Konaté M, Traoré A, Dembélé B, Togo P, Kanté L. Therapeutic and Prognostic Aspects of Acute Generalized Peritonitis at the Referral Health Center (CSRéf) of Ouélessébougou. SAS J Surg, 2024 Oct 10(10): 1130-1134.

emergencies were excluded. The diagnosis of peritonitis was clinical, and all patients were thoroughly examined. Paraclinical exams, such as abdominal X-rays and ultrasounds, were performed for certain patients. All patients underwent pre-, intra-, and postoperative resuscitation and general anesthesia. Appendicular etiology was present in 46.5% of patients. The surgical procedures performed were mainly appendectomy, lavage, and drainage. The Mannheim score was less than 26 in 97.7% of patients. Data was collected from operating room records, consultations, and hospitalization records, entered in Word 2016, and analyzed using SPSS 21 (French version). Significant differences were set at $p \leq 0.05$.

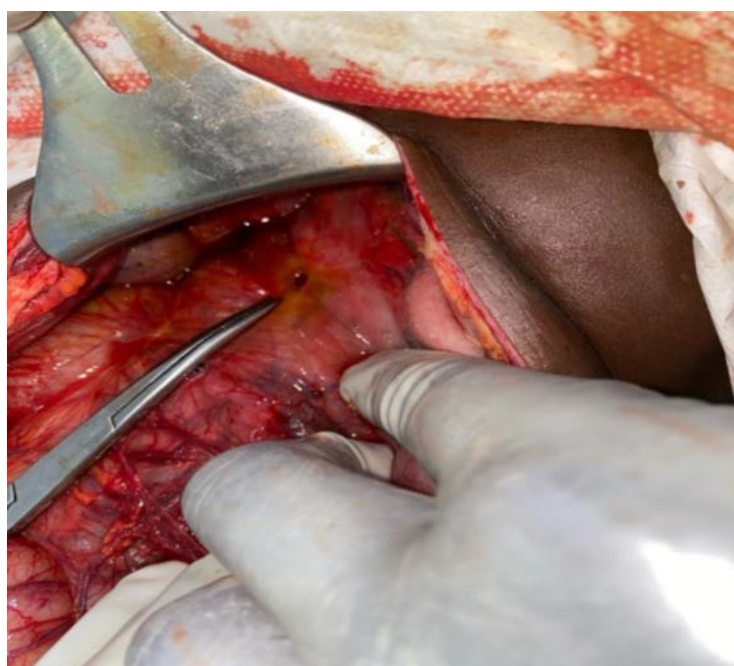
RESULTS

During the study period, 182 patients underwent emergency surgery, of which 43 cases were acute peritonitis (0.44%). The average age was

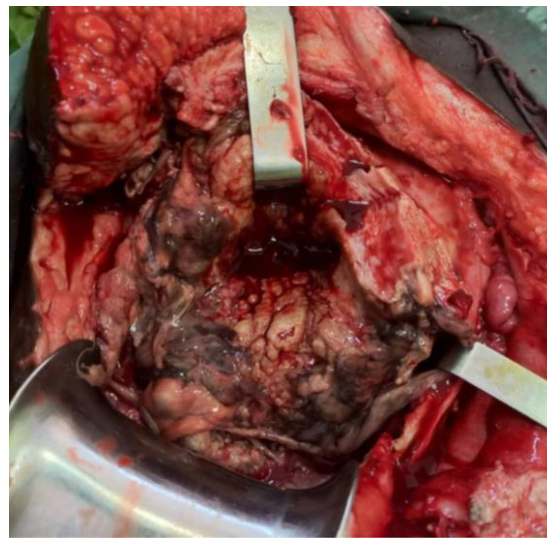
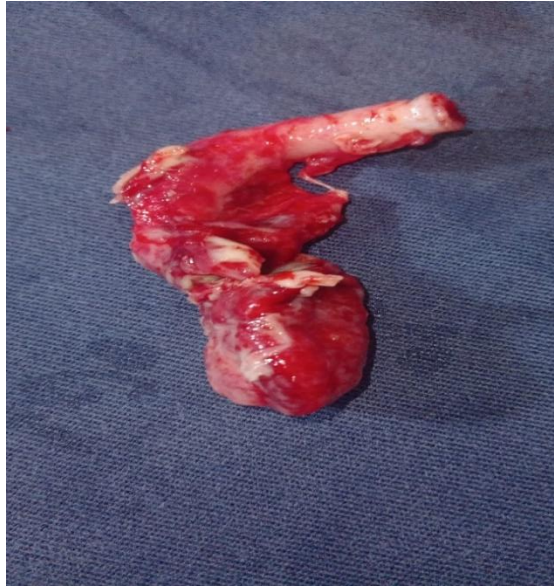28.58±16.53 years (ranging from 7 to 70 years). The most represented age group was 01 to 30 years (60.5%). The majority of patients were male (65%). All patients presented with abdominal pain, with 48.8% initially reporting pain in the right iliac fossa. Patients consulted on average 4.41 days after symptom onset. ASP was performed in 33 patients, showing diffuse greyness in all cases and an interhepatic-diaphragmatic gas crescent in 11 patients. Ultrasound was performed in 21 patients (49%). The diagnosis of generalized acute peritonitis was mainly clinical and confirmed during surgery. General anesthesia was administered to all patients. The most common etiology was appendicitis (46.5%), followed by duodenal perforation (14%). Most patients had a good prognosis according to the Mannheim score (97.7%), with an average hospital stay of 5.36 days. Postoperative outcomes were uncomplicated in 72.1% of cases, while 23.3% had parietal suppuration. One patient died (2.3%), and two patients developed hernias (2.3%).

Table: Distribution of patients according to the Hamburg classification

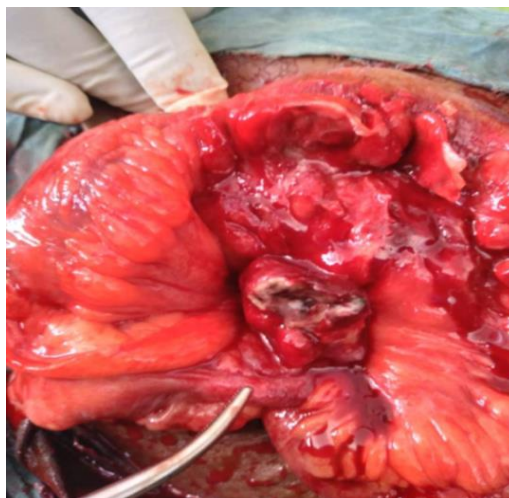
Hamburg Classification		Number of cases	Percentage
Primary peritonitis		-	-
Secondary peritonitis	Appendicular	20	46,5
	Duodenal perforation	6	14,0
	Ileal perforation	4	9,3
	Gynécological	3	7,0
	Liver abcess	3	7,0
	Gastric perforation	2	4,6
	Colonic perforation	1	2,3
	Jejunal perforation	1	2,3
Tertiary peritonitis	Post cesarean	3	7,0
Total		43	100



- Peritonitis due to gastric perforation in a 36-year-old patient.



- Peritonitis due to uterine necrosis following a cesarean section in a 27-year-old patient.
- Appendectomy specimen



- Peritonitis due to appendicular perforation in a 34-year-old patient.

DISCUSSION

During the study period, we observed an incidence of 6.70% of acute peritonitis among all surgical interventions. This frequency does not statistically differ from that reported by Lorand I *et al.*, [24], with $p > 0.05$. However, it shows a significant difference compared to the studies by Cissé *et al.*, [23] and Sidibé *et al.*, [7] in Mali, with $p < 0.05$. This discrepancy could be attributed to differences in sample sizes. The mean age of patients in our study was 28.58 years, consistent with most African series [7, 25, 38]. In contrast, developed countries report older patients, as seen in Gougard's study [38]. This difference might be due to the younger demographic profile in Africa. Age does not appear to be a factor in the incidence of peritonitis. We observed a male predominance (65%) with a sex ratio of 1.85 (2 men for every 1 woman), which is not statistically different from the series by Doumbia *et al.*, [26] and Berthé A *et al.*, [27], with $p > 0.05$. Patients consulted after an average delay of 4.41 days, which does not differ significantly from the findings of Mariage M *et al.*, [29], Bakhou A *et al.*, [30], and Camara B *et al.*, [31] with $p > 0.05$. Intense, continuous abdominal pain with a sudden onset was the most consistent symptom. Pain characteristics such as location, radiation, and type are crucial for diagnosis [38]. Abdominal pain was present in all patients, as reported by Sidibé *et al.*, [7], L. Traoré *et al.*, [32], and Maiga B *et al.*, [34]. Vomiting, whether alimentary, bilious, or fecaloid, was observed in 34.9% of patients, in line with L. Traoré *et al.*, [34]. The incidence of stool and gas cessation in 9.3% of patients did not significantly differ from L. Traoré *et al.*, (11.9%) [34] and Kunin (14.3%) [37] in France. Several factors contribute to delayed consultation in our context, including socioeconomic challenges and reliance on traditional treatments. The average progression time was 2.5 days, consistent with other African studies [10, 16], but differing from the literature [22, 23]. Pain was primarily localized in the right iliac fossa (84.4%), aligning with reports in the literature [13, 17]. Appendiceal causes were identified in 20 of our patients, with an internal latero-caecal position in 98.2% during surgery, reflecting findings from French and Nigerien series [17, 18] without significant differences. The average length of hospital stay was 5.36 days, slightly longer than in Asian, American, and Israeli studies [21, 22, 23]. This difference can be attributed to delays in management and the fact that most patients reside in rural areas with limited access to quality care, unlike Europe, where care is typically covered by social security.

CONCLUSION

Acute generalized peritonitis is a common surgical emergency with severe morbidity and mortality. The appendicular origin remains the most common etiology. Postoperative mortality is associated with the degree of peritoneal contamination, consultation delay, and therapeutic management. The improvement of

surgical outcomes is related to early diagnosis and the speed of management.

REFERENCES

1. Diakite, L. Therapeutic and Prognostic Aspects of Generalized Acute Peritonitis at the Kayes Hospital 2014-103p. N°167.
2. Jean, Y. M., & Jean, L. C. (2001). Acute Peritonitis Rev Prat (Paris), 51, 2141-2145.
3. Golash, V., & Wilson, P. D. (2005). Early laparoscopy as a routine procedure in the management of acute abdominal pain: A review of 1320 patients. *Surg Endosc*, 19(7), 8825.
4. Thoreau, N., Fain, O., Babinet, P., Lortholary, O., Robineau, M., Valeyre, D., ... & Thomas, M. (2002). Peritoneal tuberculosis: 27 cases in the suburbs of northeastern Paris. *The International Journal of Tuberculosis and Lung Disease: the Official Journal of the International Union Against Tuberculosis and Lung Disease*, 6(3), 253-258.
5. Chow, K. M., Chow, V. C. Y., & Szeto, C. C. (2003). Indication for peritoneal biopsy in tuberculous peritonitis. *The American Journal of Surgery*, 185(6), 567-573.
6. Ouloguem, M. Non-traumatic surgical emergencies at Sikasso Hospital: A report of 380 cases. Thesis Med. Bamako 2007; P89; N°12.
7. Sidibe, Y. S. *et al*. Therapeutic and Prognostic Aspects of Generalized Acute Peritonitis at the Bougouni Referral Health Center [Internet] [Thesis]. USTTB; 2022 [cited 24 July 2023].
8. Coulibaly, I. S. *et al*. Digestive perforations at the Regional Hospital of Sikasso. Thesis Med, Bamako 2005; N°215; P22.
9. Shittu, O. B., Gana, J. Y., Alawale, E. O., & Ogundiran, T. O. (2001). Pattern of mechanical intestinal obstruction in Ibadan: a ten year review. *A J Med*, 30(12), 17-21.
10. Sissoko, F., Ongoiba, N., Berete, S. *et al*. Peritonitis due to ileal perforation in Surgery B at Point G Hospital. Mali Med 2013; (3):1-5.
11. Cady, J. K. Human anatomy. 2nd edition Paris IV: Maloine, 1982:12-14.
12. Rouviere, H. Descriptive, topographical, and functional anatomy: The trunk. Masson 1998; Vol. 2, p728.
13. Kamina, P. Atlas Dictionary of Anatomy, P-Z. Maloine S.A. Publisher 1983:1742-44.
14. Kamina, P. Atlas Dictionary of Anatomy, A-F. Maloine S.A. Publisher 1983: P74-86.
15. Faniez, P. L., Serpeau, & Thomson, C. Acute Peritonitis Encycl. Med Chir Stomach-Intestine 1982; 9045 A10, 6.
16. Chevalier, J. M. Anatomy: The Trunk. Flammarion Med-Sciences (Paris) 1998.
17. Kamina, P. Clinical Anatomy. 2nd edition Paris: Maloine, 2007:213-230.
18. Konate, H. Acute Surgical Abdomen in the Department of General and Pediatric Surgery at the

- Gabriel Touré University Hospital. Thesis Med, Bamako 2001; P89; N°67.
19. Traore, M. L. S. Study of Acute Peritonitis at the CHU of Kati. Thesis Med (FMOS) 2014;(14M112): 80p.
 20. Seto, S. Contribution to the study of complications of acute appendicitis in adults: A report of 1251 cases at the visceral surgery department of C.H.U. Cotonou. Thesis Med, Cotonou 1994; P97; N°615.
 21. Boukhaka, S. Abdominal emergencies in Congo. Thesis Med, Brazzaville 1982; P86; N°34.
 22. Dictionary of Medicine. Flammarion. Med-Sciences. France. 2005.
 23. Cisse, A. H. *et al*. Acute Peritonitis at CS Ref of Commune I: Epidemiological, Clinical, and Therapeutic Aspects [Internet] [Thesis]. USTTB; 2019 [cited 24 July 2023].
 24. Lorand, I., Malinier, N., & Sales, J. P. (1999). Results of laparoscopic treatment of perforated ulcers. *J Chir (Paris, 1908)*, 124, 149-53.
 25. Dissa, B. A. Acute Peritonitis: Clinical, Diagnostic, and Therapeutic Aspects at Fousseyni Daou Hospital of Kayes. Thesis Med, Bamako 2012; P88; N°53.
 26. Doumbia, D. *et al*. Management of Appendicular Peritonitis at Bougouni Health Center [Internet] [Thesis]. Université des Sciences, des Techniques et des Technologies de Bamako; 2020 [cited 24 July 2023].
 27. Berthe, A., Postairea, M., Cheikhlarb, A., Zaharc, J.-R., & Bourgeta, P. (2012). Antibiotherapy in appendicular peritonitis in children: Is oral therapy followed? *Elsevier Masson 2012 Archives de Pédiatrie*, 19, 1303-1307.
 28. Kambire, J. L., Zare, C., Sanou, B. G., & Kamba, T. (2017). Etiologies and prognosis of secondary peritonitis at the University Hospital Center of Bobo-Dioulasso (Burkina Faso). *J Afr Hépatol Gastroenterol*, 11.
 29. Mariage, M. *et al*. Appendicular stercoral peritonitis: A rare and severe form of acute appendicitis. Thesis Med, Amiens 2016; N°174 P59.
 30. Bakhou, A. *et al*. Appendicular peritonitis in children: Experience of the pediatric surgery department at CHU Marrakech [Thesis Med]. Marrakech 2012; N°2.
 31. Camara, B. *et al*. Appendicular perforation peritonitis in the general and pediatric surgery department of Gabriel Touré Hospital. Thesis Med Bamako 2008 13M148 P89.
 32. Maïga, B. *et al*. Contribution to the study of appendicitis: Clinical, anatomical, and etiological aspects at CSREF of Commune I in 2015, 15M59, pages 90.
 33. Traore, L. *et al*. Study of Peritonitis at CHU Kati. Thesis Med 2013-2014; P80; N°112.
 34. Coulibaly, C. O. S. *et al*. Generalized Acute Peritonitis at Sikasso Hospital. Thesis Med, Bamako 2010; N°10M408.
 35. Mallick, S., & Klein, J. F. (2001). Management of bowel perforations of typhoid origin: A series observed in Western Guyana. *Med Trop*, 61, 491-494.
 36. Kunin, N., & Letoquard, J. P. (1991). Prognostic factors of peritonitis in elderly patients: Multivariate statistical analysis of 216 cases. *J Chir (Paris)*, 128(11), 481-486.
 37. Flamant, Y. *et al*. (1994). Complications of acute appendicitis. *Rev Prat (Paris)*, 44, 2231-2235.
 38. Jean, Y. M., & Jean, L. C. (2001). Acute Peritonitis. *Rev Prat (Paris)*, 51, 2141-2145.