

# Analyzing Outcome of Laparoscopic Cholecystectomy in Pregnant Women

Dr. Mohammad Faroque Eastiak<sup>1\*</sup>, Dr. Md. Shahidul Islam<sup>2</sup>, Dr. Md. Faysal Kamal<sup>3</sup>, Dr. Mahamud Mannan<sup>4</sup>, Dr. Mushtab Shira Mousumi<sup>5</sup>, Dr. Moyeen Ahmed Ferdous<sup>6</sup>

<sup>1</sup>Assistant Professor, Department of General Surgery, Bangabandhu Sheikh Mujib Medical University (BSMMU), Dhaka, Bangladesh

<sup>2</sup>Assistant Professor, Department of Colorectal Surgery, Bangabandhu Sheikh Mujib Medical University (BSMMU), Dhaka, Bangladesh

<sup>3</sup>Medical Officer, Department of General Surgery, Bangabandhu Sheikh Mujib Medical University (BSMMU), Dhaka, Bangladesh

<sup>4</sup>Assistant Professor, Department of Orthopaedic Surgery, Bangabandhu Sheikh Mujib Medical University (BSMMU), Dhaka, Bangladesh

<sup>5</sup>Junior Consultant (Paediatrics), Nawabganj Upazilla Health Complex, Dhaka, Bangladesh

<sup>6</sup>Assistant Professor, Department of Orthopaedic Surgery, Bangabandhu Sheikh Mujib Medical University (BSMMU), Dhaka, Bangladesh

DOI: <https://doi.org/10.36347/sajs.2024.v10i10.013>

| Received: 30.08.2024 | Accepted: 05.10.2024 | Published: 16.10.2024

\*Corresponding author: Dr. Mohammad Faroque Eastiak

Assistant Professor, Department of General Surgery, Bangabandhu Sheikh Mujib Medical University (BSMMU), Dhaka, Bangladesh

E-mail: [eastiak55@gmail.com](mailto:eastiak55@gmail.com)

## Abstract

## Original Research Article

**Background:** Laparoscopic cholecystectomy is a frequently performed surgery for gallbladder diseases, including during pregnancy when conservative treatments are ineffective. Although typically safe, surgery during pregnancy poses risks like preterm labor and fetal distress. Ensuring meticulous perioperative management is essential to reduce maternal and fetal complications. This study aimed at analyzing the outcomes and complications of laparoscopic cholecystectomy in pregnant women. **Methods:** This prospective observational study was conducted in the Department of General Surgery, Bangabandhu Sheikh Mujib Medical University (BSMMU), Dhaka, Bangladesh from 26 March 2021 to 21 July 2022. A total of 87 pregnant women who underwent laparoscopic cholecystectomy were enrolled in this study purposively. The variables included patient age, gestational age, clinical diagnosis, surgical procedure performed, postoperative complications, and maternal and perinatal morbidity and mortality. Data were processed, analyzed, and presented using MS Office tools. **Results:** The mean age of participants was  $33.6 \pm 7.4$  years, with a mean gestational age of  $28.3 \pm 4.9$  weeks. Most of the participants (51.7%) were multiparous. All of them presented with right subcostal pain, and 98.8% had tenderness in the same region. Ultrasonography showed gallbladder wall thickness  $>4$ mm in all cases. Post-operative infections occurred in 8% of patients, with no mortality recorded. The majority (64.4%) had a hospital stay of just one day after laparoscopic cholecystectomy. **Conclusion:** Right subcostal pain and tenderness are the commonest clinical features in pregnant women requiring laparoscopic cholecystectomy. Laparoscopic cholecystectomy during pregnancy is also a safe and effective treatment procedure for managing gallstone disease.

**Keywords:** Complications, Gallbladder diseases, Laparoscopic cholecystectomy, Outcomes, Pregnant women.

Copyright © 2024 The Author(s): This is an open-access article distributed under the terms of the Creative Commons Attribution 4.0 International License (CC BY-NC 4.0) which permits unrestricted use, distribution, and reproduction in any medium for non-commercial use provided the original author and source are credited.

## INTRODUCTION

Biliary pathology is a frequent condition during pregnancy, and its complications may jeopardize the pregnancy [1]. In recent years, various non-invasive techniques have been introduced for the treatment of cholelithiasis [2]. Despite the effectiveness of various techniques in eliminating or removing gallstones, none of them are conclusive due to the persistent presence of a diseased gallbladder [3]. In 1987, French surgeon Phillippe Mouret performed the first gallbladder removal using laparoscopic techniques [2]. Since then, interest in this procedure has surged, with thousands of medical professionals receiving hands-on training and numerous

reports published affirming its safety in large patient series [4]. Laparoscopic cholecystectomy has become an outstanding surgical approach for patients with symptomatic cholelithiasis, particularly due to its lower complication rates. Furthermore, its application in pregnant patients with acute biliary tract infections has gained widespread clinical acceptance [5]. Furthermore, data has shown that laparoscopic procedures have also been effectively utilized during pregnancy for treating other intra-abdominal conditions. However, concerns regarding potential fetal distress and miscarriage remain [6]. The rates of significant complications and mortality from such surgeries are relatively low, establishing

**Citation:** Mohammad Faroque Eastiak, Md. Shahidul Islam, Md. Faysal Kamal, Mahamud Mannan, Mushtab Shira Mousumi, Moyeen Ahmed Ferdous. Analysing Outcome of Laparoscopic Cholecystectomy in Pregnant Women. SAS J Surg, 2024 Oct 10(10): 1154-1157.

cholecystectomy as the gold standard for patients with cholelithiasis [7]. In the United States, approximately 20 million people, or 15% of the population, are affected by gallstones. Studies using ultrasound in Europe have shown a prevalence of 9% to 21%, with an incidence rate of 0.63 per 100 individuals per year [8]. Despite advancements in surgical expertise, current literature continues to indicate a considerable range of conversions from laparoscopic cholecystectomy to open cholecystectomy [2]. Laparoscopic cholecystectomy remains a valuable option, particularly in high-risk cases, due to its safety profile [9]. All pre-operative risk factors should be carefully assessed to optimize the post-operative outcome. The objective of this current study was to analyze the outcomes and complications of laparoscopic cholecystectomy in pregnant women.

## METHODOLOGY

This was a prospective cross-sectional study that was conducted in the Department of General Surgery, Bangabandhu Sheikh Mujib Medical University (BSMMU), Dhaka, Bangladesh from 26 March 2021 to 21 July 2022. A total of 87 pregnant women who underwent laparoscopic cholecystectomy were purposively enrolled in this study. Informed consent was obtained in black and white from all participants before the collection of data. As per the inclusion criteria of this study, pregnant patients who underwent laparoscopic cholecystectomy during any of the three trimesters and did not experience severe complications related to pancreatic-biliary diseases, such as cholangitis, pancreatic ascites, pseudocysts, or pancreatic necrosis, were included in the study. Patients requiring cholecystectomy as the primary treatment for these conditions were excluded, as were those whose records did not contain complete data for this study. The

indications for performing laparoscopic cholecystectomy in our patients included acute cholecystitis, biliary pancreatitis following previous endoscopic retrograde cholangiopancreatography, bile duct obstruction, or risk of choledocholithiasis. Additionally, cholelithiasis without complication data was indicated when recurrent biliary colic occurred more than three times or when it was diagnosed during the second trimester of pregnancy. The variables included age of the patient, gestational age, clinical diagnosis, surgical procedure performed, postoperative complications, and maternal and perinatal morbidity and mortality. Data were processed, analyzed, and presented using MS Office tools.

## RESULT

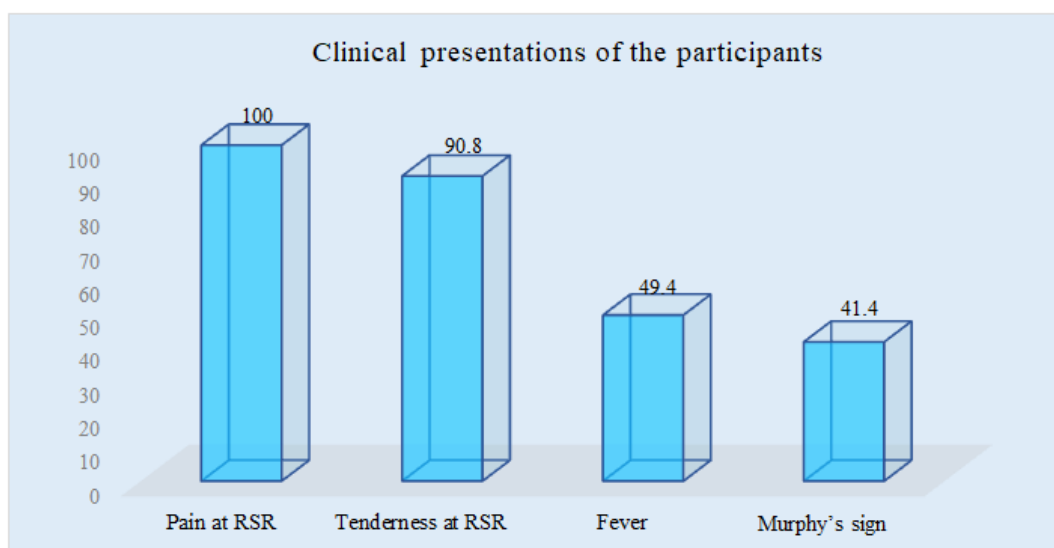
In this study, the demographic characteristics of the participants included a mean age of 33.6 years ( $\pm 17.4$ ), a mean gestational age of 28.3 weeks ( $\pm 4.9$ ), and a mean duration of surgery of 61.1 minutes ( $\pm 14.8$ ). Among the participants, 17 (19.5%) were primiparous, 45 (51.7%) were multiparous, and 25 (28.7%) were grand multiparous. Analysis of clinical presentations revealed that 100% of participants experienced pain in the right subcostal region, while 90.8% had tenderness in the same area. Additionally, fever was noted in 49.4% of cases, and Murphy's sign was observed in 41.4% of participants. In ultrasonographic evaluation, gallbladder wall thickness  $>4$ mm was observed in all (100%) of participants. Multiple stones were found in 54% and single stone was found in 40.2% of the cases. The outcomes of laparoscopic cholecystectomy revealed that 7 patients (8.0%) experienced post-operative infections, while no mortality was recorded. The majority of patients (64.4%) had a hospital stay of 1 day, 20.7% stayed for 2 days, 9.2% for 3 days, and 5.7% for 4 days.

**Table 1: Demographic characteristics (N=87)**

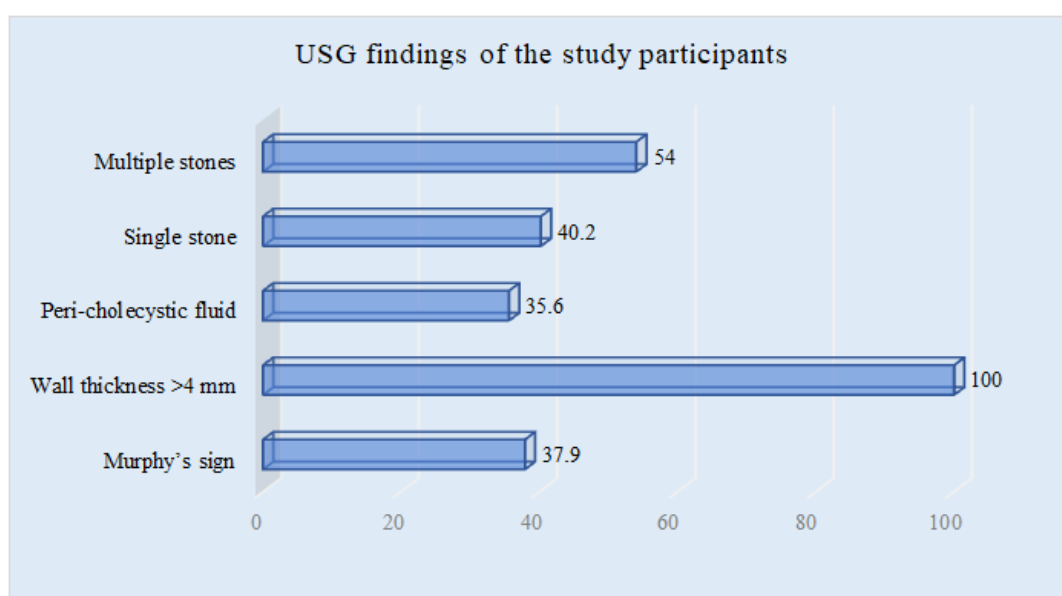
Variables	Unit/type	Findings	
		Mean +SD/n (%)	
Age	Year	33.6 +7.4	
GA	Week	28.3 +4.9	
DS	Minute	61.1+14.8	
Parity	Primiparous	17	19.5%
	Multiparous	45	51.7%
	Gr. multiparous	25	28.7%

**Table 2: Outcomes of laparoscopic cholecystectomy (N=87)**

Variables	n	%
Post-operative infection	7	8.0%
Mortality	0	0.0%
<b>Hospital stays</b>		
1 day	56	64.4%
2 days	18	20.7%
3 days	8	9.2%
4 days	5	5.7%



**Figure 1: Column chart showed participants according to clinical presentations (N=87)**



**Figure 1: Column chart showed USG findings among participants (N=87)**

## DISCUSSION

In this cross-sectional study, the demographic characteristics of the participants revealed a mean age of 33.6 years, a mean gestational age of 28.3 weeks, and an average duration of surgery 61.1 minutes. The participants comprised 19.5% primiparous, 51.7% multiparous, and 28.7% grand multiparous women. A comparable demographic distribution was reported in a recent study [10]. The analysis of clinical presentations showed that all participants experienced right subcostal pain, with 90.8% also exhibiting tenderness in this region. Additionally, fever was present in nearly half of the cases, and Murphy's sign was positive in 41.4% of participants. Similar type of clinical features was observed in another recent study [11]. In ultrasonographic evaluation, gallbladder wall thickness >4mm was observed in all of the participants. Multiple

stones were found in most of the cases. The outcomes of laparoscopic cholecystectomy revealed that 7 patients (8.0%) experienced post-operative infections, while no mortality was recorded. The majority of patients had a hospital stay of 1 day. K Das *et al*. also found nearly similar results [10]. Based on previous literature and reports demonstrating the safety of laparoscopy, it was decided to employ the laparoscopic approach for all pregnant patients requiring emergency or urgent cholecystectomy [12]. However, another study previously concluded that laparoscopic cholecystectomy may be contraindicated in pregnant patients due to the risk of fetal mortality [13]. When comparing our 87 patients with previously published series, the fetal mortality rate was lower (n=0) than those associated with open procedures. Around the 20th week of gestation, the pregnant uterus reaches the level of the umbilicus, causing significant displacement of abdominal viscera.

This displacement reduces the available space for both laparoscopic manipulations and trocar placements [14]. When a 5 mm trocar is first introduced into the upper abdominal quadrant, rest of the trocars can be safely inserted and properly positioned under direct visualization. There is limited intra-abdominal space available for cholecystectomy and the procedure generally involves four trocars [15]. Based on various literature and their outcomes, laparoscopic cholecystectomy is recommended as the preferred technique for pregnant patients under similar conditions [16].

#### LIMITATION OF THE STUDY

This study was conducted at a single center with a small sample size and over a relatively short duration. Consequently, the findings may not fully represent the broader national context.

#### CONCLUSION & RECOMMENDATION

Right subcostal pain and tenderness are the most common clinical features observed in pregnant women requiring laparoscopic cholecystectomy. This surgical procedure is deemed safe and effective for managing gallstone disease during pregnancy. The minimally invasive nature of laparoscopic cholecystectomy minimizes potential complications and promotes faster recovery for both the mother and fetus. By addressing gallstone-related issues promptly, healthcare providers can ensure better health outcomes for pregnant women, alleviating pain and preventing further complications associated with gallstone disease. Overall, laparoscopic cholecystectomy remains a reliable treatment option in this unique patient population.

#### REFERENCES

- Marcos-Ramírez, E. R., Guerra-Leza, K., Téllez-Aguilera, A., Benavides-Zavala, T. E., Fernández-Treviño, J. R., & Muñoz Maldonado, G. E. (2022). Laparoscopic cholecystectomy during pregnancy. *Cirugía y cirujanos*, 90(1), 29-33.
- Das, K., Yousfani, Z. A., Atta, J., Rind, G., Sushel, C., & Zoya, M. (2020). Surgical Outcome in Laparoscopic Cholecystectomy in Pregnant Patients. *Journal of The Society of Obstetricians and Gynaecologists of Pakistan*, 10(3), 201-204.
- Shigemi, D., Aso, S., Matsui, H., Fushimi, K., & Yasunaga, H. (2019). Safety of laparoscopic surgery for benign diseases during pregnancy: a nationwide retrospective cohort study. *Journal of minimally invasive gynecology*, 26(3), 501-506.
- Kolbeinsson, H. M., Hardardottir, H., Birgisson, G., & Moller, P. H. (2016). Gallstone disease during pregnancy at Landspítali University Hospital 1990-2010. *Laeknabladid*, 102(12), 538-542.
- Hameroff, A., & Pauli, J. M. (2019). Cholecystectomy of the Pregnant Patient. In: *Clinical Algorithms in General Surgery*. Springer; 373-375.
- Dizon, A. M., & Carey, E. T. (2018). Minimally invasive gynecologic surgery in the pregnant patient: considerations, techniques, and postoperative management per trimester. *Current Opinion in Obstetrics and Gynecology*, 30(4), 267-271.
- Skubic, J. J., & Salim, A. (2017). Emergency general surgery in pregnancy. *Trauma surgery & acute care open*, 2(1), e000125.
- Heesen, M., & Klimek, M. (2016). Nonobstetric anesthesia during pregnancy. *Current Opinion in Anesthesiology*, 29(3), 297-303.
- Luthra, A. K., Patel, K. P., Li, F., Groce, J. R., Lara, L. F., Strobel, S., ... & Krishna, S. G. (2019). Endoscopic intervention and cholecystectomy in pregnant women with acute biliary pancreatitis decrease early readmissions. *Gastrointestinal endoscopy*, 89(6), 1169-1177.
- Das, K., Yousfani, Z. A., Atta, J., Rind, G., Sushel, C., & Zoya, M. (2020). Surgical Outcome in Laparoscopic Cholecystectomy in Pregnant Patients. *Journal of The Society of Obstetricians and Gynaecologists of Pakistan*, 10(3), 201-204.
- Rather, Z. M., Majid, N. A., Islam, M. N., & Mohd, R. W. (2020). Outcome of early laparoscopic cholecystectomy versus delayed laparoscopic cholecystectomy for patients with acute cholecystitis. *International Surgery Journal*, 7(4), 1212-1217.
- Sedaghat, N., Cao, A. M., Eslick, G. D., & Cox, M. R. (2017). Laparoscopic versus open cholecystectomy in pregnancy: a systematic review and meta-analysis. *Surgical endoscopy*, 31, 673-679.
- Hedström, J., Nilsson, J., Ekelund, M., Andersson, R., & Andersson, B. (2020). Cholecystectomy after previous bariatric surgery with special focus on pregnant patients—results from two large nationwide registries. *Obesity Surgery*, 30, 1874-1880.
- Chamberlain, S. L., & Croagh, D. (2020). Managing choledocholithiasis in pregnancy: a novel approach. *BMJ Case Reports CP*, 13(3), e232955.
- Qiu, S. Y., Ng, K. K., Cheung, T. T., Liu, C. H., Zhu, H. T., Xu, B. R., ... & Lo, C. M. (2019). A successful combined laparoscopic cholecystectomy and laparoscopic exploration of common bile duct for acute gangrenous cholecystitis and choledocholithiasis during pregnancy: a case report. *International journal of surgery case reports*, 58, 14-17.
- Nasioudis, D., Tsilimigras, D., & Economopoulos, K. P. (2016). Laparoscopic cholecystectomy during pregnancy: a systematic review of 590 patients. *International Journal of Surgery*, 27, 165-175.