

Talus Fracture in Children: Case Report

Meryem Fettah^{1*}, Mohammed Mimouni¹, Mohamed Tazi Charki¹, Hicham Abdellaoui¹, Karima Atarraf¹, Moulay Abderahmane Afifi¹

¹Department of Pediatric Traumatology-Orthopaedics, CHU Hassan II Fez, Morocco. Faculty of Medicine and Pharmacy, University Sidi Mohamed Ben Abdellah Fez, Morocco

DOI: <https://doi.org/10.36347/sajs.2024.v10i11.001>

| Received: 27.09.2024 | Accepted: 31.10.2024 | Published: 04.11.2024

*Corresponding author: Meryem Fettah

Department of Pediatric Traumatology-Orthopaedics, CHU Hassan II Fez, Morocco. Faculty of Medicine and Pharmacy, University Sidi Mohamed Ben Abdellah Fez, Morocco

Abstract

Case Report

Fracture of the talus is uncommon in childhood, it represents serious injuries of the foot skeleton. The most significant complications include osteonecrosis and posttraumatic malalignment with subsequent arthritis. We report a case of talar neck fracture that occurred in a 12-year-old boy. We present the clinical outcome, radiological results and orthopaedic follow-up.

Keywords: Talus, Fractures, Blood Supply, Talar Neck Fractures, Complications.

Copyright © 2024 The Author(s): This is an open-access article distributed under the terms of the Creative Commons Attribution 4.0 International License (CC BY-NC 4.0) which permits unrestricted use, distribution, and reproduction in any medium for non-commercial use provided the original author and source are credited.

INTRODUCTION

fractures of the talus in paediatric age group are relatively rare, accounting for around 0.08% of injuries [1], its is estimated to be five times rarer than for adult trauma [2]. Out of these, a vast majority (about 50%-80%) of these fractures involve the talar neck, followed by the talar body [2-4]. A high level of clinical suspicion is needed to avoid missing this type of fracture, especially when it has a minimal displacement. Paediatric bone is more elastic than adult bone [2], so fewer fractures occur in early life.

Complications like posttraumatic arthrosis, avascular necrosis and less often Nonunion of talus fracture has been described in literature. They may plague the course of treatment, especially in displaced fractures [3-5].

CASE PRESENTATION

A 12-year-old boy presented to the emergency department with right foot pain after falling from a height of over 2 metres with the point of impact directly on the heel.

Physical examination found swelling, ecchymosis and tenderness on the dorsal side of the mid-foot. Foot and ankle mobilisation was painful. the standard X-ray (figures 1) showed a minimally displaced fracture of the talus (Hawkins type 1 talus fracture

without subtalar dislocation). CT SCAN revealed a complex talar fracture (figures 2).

The lesion was treated with a short-leg cast for 6 weeks, analgesia with paracetamol and ibuprofen was given according to his weight.

The evolution was good with a 12-month follow-up, without any morphological or functional complications.

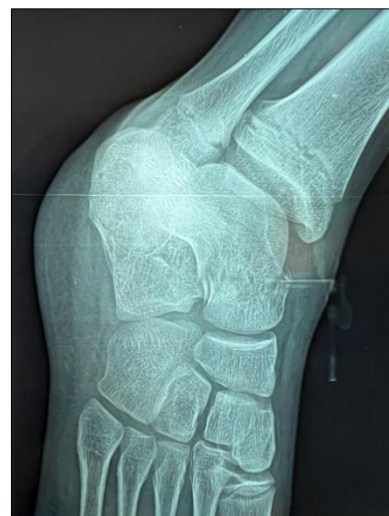

Figure 1: Standard ankle X-ray showing talus fracture

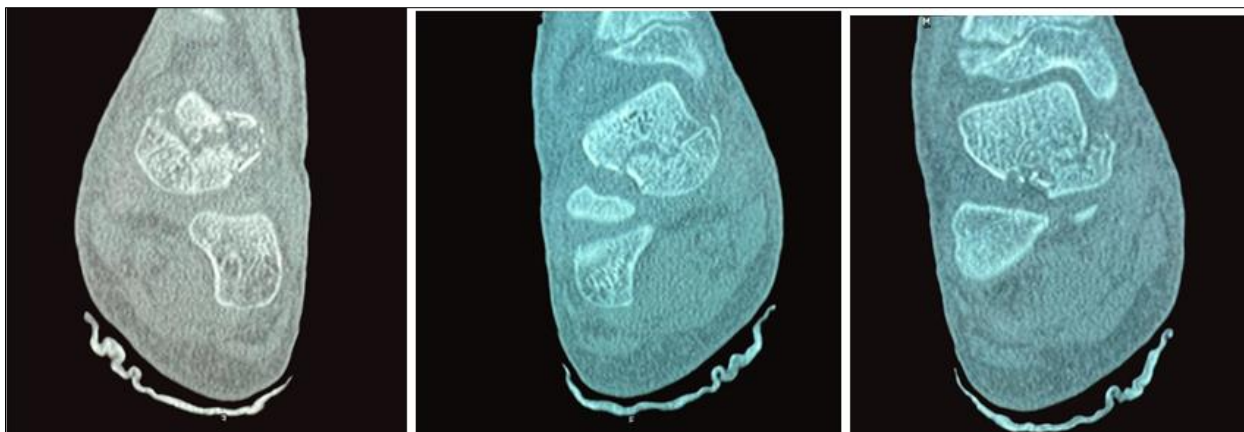


Figure 2: Different CT scans of the ankle showing comminuted fracture of the talus

DISCUSSION

Talar fractures in children are a rare injury, probably owing to the elasticity of pediatric bone and cartilage, which is resistant to higher forces and less likely to fracture than adult tissue [5]. It has been estimated that talar fractures account for 0.08% to 0.008% of all fractures in children compared with 0.3% of all fractures in adults [5, 6]. A fracture of the talus results almost exclusively from a high velocity axial load. Suspicious mechanisms of injury include all high-energy traumas in which the foot is forcibly dorsiflexed and the neck of the talus impinges against the anterior lip of the distal tibia. This could result from, for example, a fall from a height or a go-kart or car crashing frontally into a wall, in which case the force will be directed under the foot.

In our case, the trauma was caused by a fall from a great height, and this is consistent with the mechanisms described in the literature.

Due to the high energy required to fracture the talus, these fractures may be part of a multi-trauma presentation. There may be significant deformity necessitating immediate reduction to prevent skin necrosis [7].

The injury tends to cause pain and swelling to the ankle with the inability to bear weight. Examination will usually reveal tenderness in the ankle region with a reduced range of movement. The talar head and neck may be palpated anterior and inferior to the ankle joint. The body may be palpated distal to the malleoli and anterior to the Achilles tendon if the fracture is displaced. As with all orthopaedic examinations assessing the neurovascular status is essential and any deficit will require urgent intervention [8].

Imaging is initially undertaken with plain radiography. The views required are anterior-posterior, lateral and mortise. Plain radiographs may detect talar neck fractures but there is a high false negative rate. A study of 132 talar fractures found that 93% had

additional fracture information on Computerised Tomography (CT) scanning that was not found on initial plain radiography [9].

A study by Rodop *et al.*, found that 39% of ankle and midfoot fractures may be missed at this initial stage. In their study, they found eight cases that were missed initially on plain radiography. These patients were at first treated conservatively. They were eventually diagnosed through Magnetic Resonance Imaging (MRI) and CT scanning [10]. They concluded that if there remains suspicion about a talar fracture then further imaging is recommended to reduce the risk of complications. These imaging modalities may also be beneficial for operative planning [11].

Smith *et al.*, [3], described 29 cases of major talar fractures in children (mean age 13.5, range 1.2 to 17.8 years). Complications included avascular necrosis, arthritis, non- or delayed union, and neuropraxia [3]. Nondisplaced talar fractures can usually be treated successfully with closed reduction [5–14]. However, cases of avascular necrosis have been described in minimally displaced talar fractures [15, 16].

In our case we treated the fracture with a simple short-leg cast, since it was not displaced.

Complications are most likely due to disruption of the vascular ring surrounding the talar neck as the bone fractures and/or is displaced. This will cause the artery of the tarsal sinus and the artery of the tarsal canal to occlude or thrombose, cutting off the blood supply to the talar neck and potential fracture site. In cases of displaced talar fractures, reduction, followed by internal screw fixation, is advised. However, osteonecrosis is rare in children $n < 12$ years old, and the outcome might be independent of the method of treatment [12]. In the case of a child who remains symptomatic after the initial treatment of a talar fracture, other rarer complications should be considered, for example, nonunion of the fracture [6], or a loose osteochondral body [17], or bone fragments [18], in the ankle. The former can be treated

by delayed osteosynthesis and the latter by removal of the fragment using anterior ankle arthroscopy.

CONCLUSION

Talar fractures are serious injuries with the potential to develop complications and long-term morbidity. In cases of high-energy trauma with a direct point of impact on the heel, a close examination is recommended, followed by a standard X-ray and a CT scan to ensure that the diagnosis is not missed and to avoid any subsequent complications.

BIBLIOTHEQUE

- We, L., & Me, H. [Fractures of the child's foot]. *Orthopade* [Internet]. juin 1986 [cité 15 oct 2024], 15(3). Disponible sur: <https://pubmed.ncbi.nlm.nih.gov/2874539/>
- Meier, R., Krettek, C., Griensven, M., Chawda, M., & Thermann, H. (2005). Fractures of the talus in the pediatric patient. *Foot and ankle surgery*, 11(1), 5-10.
- Smith, J. T., Curtis, T. A., Spencer, S., Kasser, J. R., & Mahan, S. T. (2010). Complications of talus fractures in children. *Journal of Pediatric Orthopaedics*, 30(8), 779-784.
- Jensen, L., Wester, J. U., Rasmussen, F., Lindequist, S., & Schantz, K. (1994). Prognosis of fracture of the talus in children: 21 (7-34)-year follow-up of 14 cases. *Acta orthopaedica Scandinavica*, 65(4), 398-400.
- Nipun, J., Parmanand, G., & Sandeep, J. (2014). Nonunion of paediatric talar neck fracture. *Chinese Journal of Traumatology*, 17(01), 48-49.
- Am, B. M. S. (2012). Paediatric talus fracture. *BMJ Case Rep* [Internet]. 5 août 2012 [cité 15 oct 2024]. Disponible sur: <https://pubmed.ncbi.nlm.nih.gov/22605852/>
- Fortin, P. T., & Balazsy, J. E. (2001). Talus fractures: evaluation and treatment. *JAAOS-Journal of the American Academy of Orthopaedic Surgeons*, 9(2), 114-127.
- Koehler, S. (2013). Talus fractures: Wolters Kluwer; 2013 [cited 2015] Available from: <http://www.uptodate.com/contents/talus-fractures>.
- Dale, J. D., Ha, A. S., & Chew, F. S. (2013). Update on talar fracture patterns: a large level I trauma center study. *American Journal of Roentgenology*, 201(5), 1087-1092.
- Rodop, O., Mahiroğulları, M., Akyüz, M., Sönmez, G., Turgut, H., & Kuşkucu, M. (2010). Missed talar neck fractures in ankle distortions. *Acta Orthop Traumatol Turc*, 44(5), 392-6.
- Fournier, A., Barba, N., Steiger, V., Lourdais, A., Frin, J. M., Williams, T., ... & Hutten, D. (2012). Total talar fracture—long-term results of internal fixation of talar fractures. A multicentric study of 114 cases. *Orthopaedics & Traumatology: Surgery & Research*, 98(4), S48-S55.
- Eberl, R., Singer, G., Schalamon, J., Hausbrandt, P., & Hoellwarth, M. E. (2010). Fractures of the talus—differences between children and adolescents. *Journal of Trauma and Acute Care Surgery*, 68(1), 126-130.
- Cartwright-Terry, M., & Pullen, H. (2008). Non-operative management of a talar body fracture in a skeletally immature patient. *Acta orthopaedica Belgica*, 74(1), 137.
- Kay, R. M., & Tang, C. W. (2001). Pediatric foot fractures: evaluation and treatment. *JAAOS-Journal of the American Academy of Orthopaedic Surgeons*, 9(5), 308-319.
- Talkhani, I. S., Reidy, D., Fogarty, E. E., Dowling, F. E., & Moore, D. P. (2000). Avascular necrosis of the talus after a minimally displaced neck of talus fracture in a 6 year old child. *Injury*, 31(1), 63-65.
- Inal, S., & Inal, C. (2014). A pediatric comminuted talar fracture treated by minimal K-wire fixation without using a tourniquet. *The Iowa Orthopaedic Journal*, 34, 175.
- Patel, V., Bloch, B., Johnson, N., & Mangwani, J. (2014). Delayed presentation of a loose body in undisplaced paediatric talar neck fracture. *World journal of orthopedics*, 5(3), 398.
- Funasaki, H., Kato, S., Hayashi, H., & Marumo, K. (2014). Arthroscopic excision of bone fragments in a neglected fracture of the lateral process of the talus in a junior soccer player. *Arthroscopy Techniques*, 3(3), e331-e334. <https://pubmed.ncbi.nlm.nih.gov/25126497/>