

A Rare Case Report of an Isolated Avulsion Fracture of Gerdy's Tubercle

Elkasseh M^{1*}, Bouras Y¹, Nassiri M¹, Achkoun A¹, El Haoury H¹, Madhar M¹, Chafik R¹

¹Orthopedic-Traumatology Department of CHU MED VI, Marrakech

DOI: [10.36347/sajs.2024.v10i02.014](https://doi.org/10.36347/sajs.2024.v10i02.014)

| Received: 03.01.2024 | Accepted: 10.02.2024 | Published: 14.02.2024

*Corresponding author: Elkasseh M

Orthopedic-Traumatology Department of CHU MED VI, Marrakech

Abstract

Case Report

We report a case of en bloc avulsion fracture of tibial tuberosity and Gerdy's tubercle. A 40-year-old male suffered from an acute pain in his left knee after a motorcycle accident. Simple radiographs showed an avulsion of the tibial tuberosity. Confirmed by CT scans. MRI evaluation revealed no intra-articular associated pathology. Open reduction and internal fixation with 1 screws were performed under antero-lateral approach to expose the Gerdy's tubercle with ITB. At 2 months postoperative, he could walk and complained of no difficulty in activities on daily living with full range-of-motion of the knee. We believe that the injury was caused by violent contraction of the tensor fascia lata or gluteus maximus. Preoperative planning including the determination of the extent of fracture and recognition of concomitant injury is a prerequisite for appropriate treatment.

Keywords: tibial tuberosity, violent contraction, gluteus maximus.

Copyright © 2024 The Author(s): This is an open-access article distributed under the terms of the Creative Commons Attribution **4.0 International License (CC BY-NC 4.0)** which permits unrestricted use, distribution, and reproduction in any medium for non-commercial use provided the original author and source are credited.

INTRODUCTION

The knee is a complex joint the knee is a complex joint with multiple tendons, ligaments and meniscal attachments, making it vulnerable to complex post-traumatic injuries. Anterolateral stability is essentially provided by the iliotibial tractus and capsule.

There are many avulsion fractures of the knee, More rarely we find an isolated avulsion of Gerdy's tubercle without damage the soft tissues most importantly ACL.

Clinical History

A 40-year-old patient was admitted following a motorbike accident causing indirect trauma to the right knee with a cracking sensation, when trying to brake by placing his foot on the ground. He was able to stand up and walk with a limp after the injury, but perceived pain when trying to move the knee.

Physical Exam

- Patient was able to stand and walk.
- We note Slight bruising of the antero-external aspect of the knee.
- With Significant pain on palpation over Gerdy's tubercle.
- Lachman's test negative.

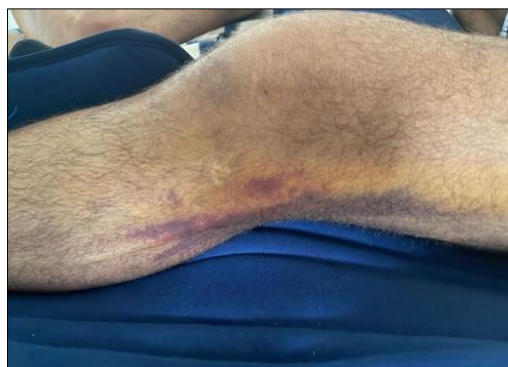

Figure 1: Pre op picture showing bruising of the antero-external aspect of the knee

In view of this clinical findings, a radiological assessment was carried out, consisting of a knee X-ray and a CT scan with 3D reconstruction.

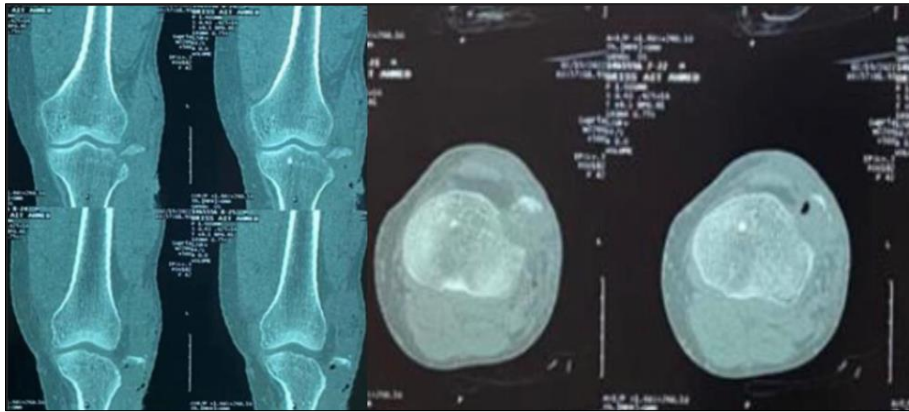


Figure 2: 2d CT coronal and sagittal cut of a 40 years old male showing ITB avulsion

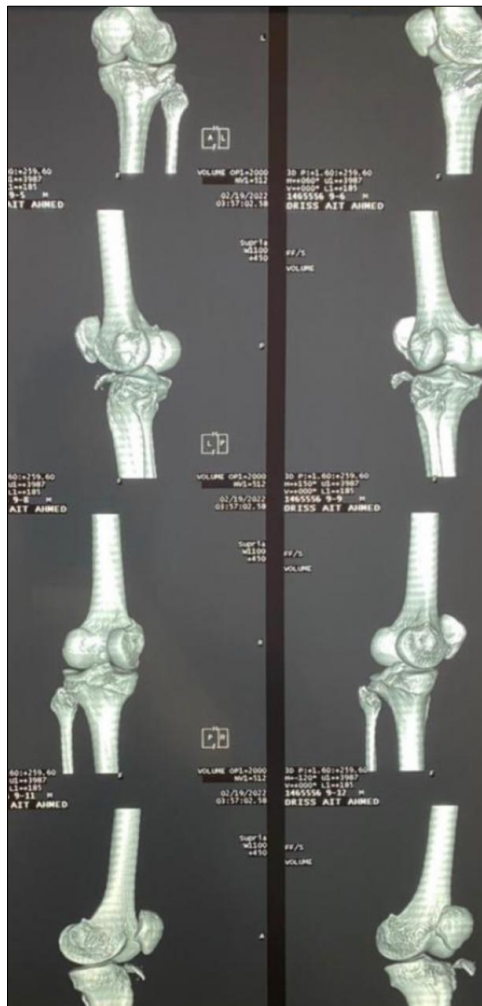


Figure 3: 3D CT showing ITB avulsion of 40 years old male

An MRI was also added to rule out soft tissue damage, notably ligament tears.

SURGERY

- Patient in supine position, a small Antero lateral approach over the gerdy’s tubercule.

- Identifying the detached fragment and preparing the fracture site.
- Reduction of the bone fragment and fixating using a 6,5 screw with a washer.

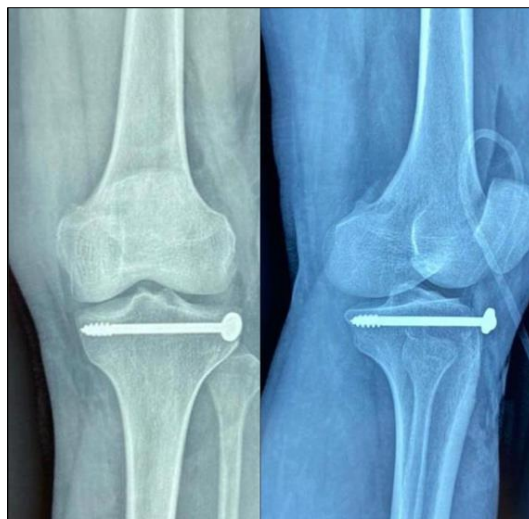

Figure 4: post op X-rays AP and lateral showing fixation with screw and washer

Post Op Rehabilitation

- Non-weight-bearing and limited mobilization was permitted in a rigid knee brace for 3 weeks.
- 3rd week: full rom was permitted with partial weight bearing.
- 6th week: full rom with total weight bearing.

DISCUSSION

The anterolateral complex of the knee is formed by three distinct layers. The outer layer is formed by the superficial layer of the ITB. The superficial ITB or the Kaplan fibers have a distinct attachment to the distal femoral metaphysis and femoral condyle. The deep layer originates from the Kaplan fibers proximally and forms the 2nd layer. The two layers blend together distal to the lateral femoral epicondyle and are reinforced by the capsulo-osseous layer. This band then continues with the fascia of lateral gastrocnemius and biceps femoris. Layer 3 consists of the anterolateral capsule with mid-third capsular or the anterolateral ligament [1].

The ITB is a longitudinal fibrous sheath running along the lateral aspect of the thigh. Proximally, it originates at the anterolateral iliac tubercle portion of the external lip of the iliac crest. It receives fascial contributions from the deep fascia of the thigh, gluteus maximus, and tensor fascia lata. Distally, it spans the lateral aspect of the knee and inserts into Gerdy's tubercle on the proximal tibia. It has a major contribution in providing anterolateral stability to the knee [2].

Functionally, ITB participates in abduction of hip through contraction of the gluteus maximus and TFL. In the knee it has a function depending on knee position, in 0–30 degrees of flexion it acts as active extensor of the knee joint while in 30–90 degrees, it acts as an active knee flexor muscle [3].

Proposed Mechanism of Injury

Based on the history, the injury seems to result from an indirect forces. There may have been a violent contraction of the tensor fascia lata or gluteus maximus which pulled ITB and led to Gerdy's tubercle avulsion. Upon examination the pain was limited to the gerdy tubercle area, with no signes knee instability, proven by MRI showing no ligament damage.

Isolated ITB avulsion is a rarity and there is only a 2 cases report published in literature till date, to the best of our knowledge.

- 1) In 2015, Fay *et al.*, published a case report of ITB avulsion fracture in the American Society of Emergency Radiology. They described the findings in a 49-year-old female who presented with the left knee injury following a motor pedestrian accident. On radiographs, they had found a large ossific fragment along the later aspect of the knee with an apparent donor site from the anterolateral tibia. There was associated liphemarthrosis and widening of lateral compartment. Their differentials included a Segond fracture, an arcuate complex avulsion fracture, and an IT band avulsion fracture.

The ITB avulsion fracture was favored because of the anterolateral tibial donor site. On MRI, there had been other ligamentous injuries that included a complete rupture of the ACL [4].

- 2) In 2021, ketan *et al.*, published the case of a 50 year old patient admitted for a detachment of an isolated tubercle of gerdy without ligament damage, diagnosed following persistent pain and instability of the knee, 3 weeks prior to a direct trauma to the knee [5].

In our case, an initial radiological assessment using standard knee X-rays revealed the gerdy's tubercle avulsion, complemented by a CT scan to

confirm the diagnosis, after that an MRI was performed to rule out a ligament lesions.

Our case is more similar the the 2nd publication where we find a ITB avulsion without ligament damage. Revealed by knee pain, discomfort and instability.

The following differential diagnoses were ruled out through imaging.

- 1) Segond fracture – This is the most commonly encountered avulsion fracture. It involves

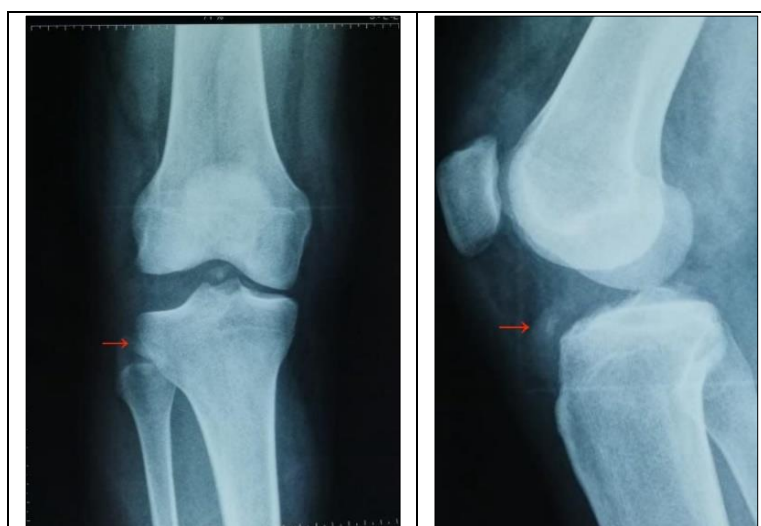


Figure 6: X-ray AP and lateral showing segond fracture

- 2) Arcuate complex avulsion fracture – Arcuate avulsion fracture involves an avulsion of the insertion of popliteofibular, arcuate, and fabellofibular ligaments from the fibular styloid process. On a conventional anteroposterior knee radiograph, it is described as the “arcuate sign” because the avulsed bone fragment has a characteristic elliptic appearance with its long axis oriented horizontally. Such fractures occur when a varus force is applied to the externally rotated tibia or push on the anteromedial aspect of tibia in an extended knee or sudden hyperextension of the knee.
- 3) Biceps femoris tendon avulsion fracture – The two heads of biceps femoris along with lateral collateral ligament form a conjoined tendon at their insertion which is attached to the lateral margin of the fibular head. An avulsion fracture of biceps femoris involves disruption of its tendon from the fibular head along with an irregular bone piece. On a conventional anteroposterior knee radiograph [7].

Imaging studies play an important role in diagnosing the type of injury and help in identifying the exact cause. While plain X rays are the standard first-line investigation, MRI help in pinpointing the exact etiology if there is any confusion due to the close proximity of structures responsible for lateral avulsion fractures.

avulsion of the tibial insertion of the middle third of the lateral capsular ligament. Patients usually present with rotational instability in the anterolateral plane and lateral joint pain. This injury is seen due to an abnormal varus stress and internal rotation of the knee [6].

On X-ray, an elliptical bone fragment is seen in the lateral, distal aspect of tibia (lateral capsular sign). On MR imaging, its association with ACL disruption and meniscal tear is extensively documented [6].

CONCLUSION

The knee is a complex joint with numerous tendon, ligament and meniscus insertions, making it particularly prone to complex post-traumatic injuries. Several types of avulsion fracture can be observed, although ITB avulsion is rare entity and it may appear simple on standard radiographs, it can affect knee stability, the challenge is to identify it, recognize possible underlying lesions and restore knee stability

REFERENCES

1. Herbst, E., Albers, M., Burnham, J. M., Fu, F. H., & Musahl, V. (2017). The anterolateral complex of the knee. *Orthopaedic Journal of Sports Medicine*, 5(10), 2325967117730805.
2. Orchard, J. W., Fricker, P. A., Abud, A. T., & Mason, B. R. (1996). Biomechanics of iliotibial band friction syndrome in runners. *The American journal of sports medicine*, 24(3), 375-379.
3. Hyland, S., & Varacallo M. (2020). Anatomy, bony pelvis and lower limb, iliotibial band (tract) In: Stat Pearls. Treasure Island, FL: Stat Pearls Publishing; 2020.
4. Fay, K., Mannem, R., Baynes, K., Sarin, D., & DuBois, M. (2016). Iliotibial band avulsion fracture: a case report with differential diagnosis. *Emergency radiology*, 23, 93-96.

5. Vatsal, K., Bhushan, S., Sajeer, U., & Anant, J. (2020). An unusual case of an isolated ilio-tibial band avulsion fracture. *Journal of Arthroscopic Surgery*.
6. Campos, J. C., Chung, C. B., Lektrakul, N., Pedowitz, R., Trudell, D., Yu, J., & Resnick, D. (2001). Pathogenesis of the Segond fracture: anatomic and MR imaging evidence of an iliotibial tract or anterior oblique band avulsion. *Radiology*, 219(2), 381-386.
7. Gottsegen, C. J., Eyer, B. A., White, E. A., Learch, T. J., & Forrester, D. (2008). Avulsion fractures of the knee: imaging findings and clinical significance. *Radiographics*, 28(6), 1755-1770.