

Association of Cystic Dilatation of the Common Bile Duct and Intestinal Volvulus in Children

Ayoub Boutahar^{1*}, Abderrahim Kamli¹, Mohammed Mimouni¹, Othmane Alaoui¹, Abdelhalim Mahmoudi¹, Khalid Khattala¹, Youssef Bouabdallah¹

¹Department of Pediatric Surgery at the University Hospital Center Hassan II, Faculty of Medicine and Pharmacy, University of Mohamed Ben Abdellah Fez, Morocco

DOI: [10.36347/sasjs.2024.v10i03.018](https://doi.org/10.36347/sasjs.2024.v10i03.018)

| Received: 11.02.2024 | Accepted: 19.03.2024 | Published: 23.03.2024

*Corresponding author: Ayoub Boutahar

Department of Pediatric Surgery at the University Hospital Center Hassan II, Faculty of Medicine and Pharmacy, University of Mohamed Ben Abdellah Fez, Morocco

Abstract

Case Report

Cystic dilation of the common bile duct is a congenital condition defined by a communicative dilation of the extrahepatic bile duct, whether associated with or without dilation of the intrahepatic bile duct. Intestinal malrotation, on the other hand, refers to a failure of rotation and fixation of the primitive intestinal loop during embryonic life. The association of cystic dilation of the common bile duct with intestinal volvulus is a very rare occurrence, posing a significant diagnostic and therapeutic challenge. Here, we present a case of an 8-year-old girl admitted for the management of cystic dilation of the common bile duct associated with intestinal volvulus, which was surgically treated with a favorable outcome.

Keywords: Cystic Dilatation of the Common Bile Duct, Intestinal Volvulus, Malrotation, Children.

Copyright © 2024 The Author(s): This is an open-access article distributed under the terms of the Creative Commons Attribution **4.0 International License (CC BY-NC 4.0)** which permits unrestricted use, distribution, and reproduction in any medium for non-commercial use provided the original author and source are credited.

INTRODUCTION

Cystic dilation of the common bile duct is a congenital condition defined by a communicative dilation of the extrahepatic bile duct, whether associated with or without dilation of the intrahepatic bile duct. These dilations have been considered as a rare entity, and are typically diagnosed before the age of ten, predominantly observed among young individuals, with a significant prevalence among females. One out of four patients will remain asymptomatic for a long time, with a risk of degeneration after several years of evolution, highlighting the need for surgical intervention once the diagnosis is confirmed [1, 2]. Early recognition and treatment mean a better outcome and less mortality and morbidity [3].

Intestinal malrotation corresponds to a defect in the rotation and fixation of the primitive intestinal loop during embryonic life, resulting in a common mesentery for the entire intestinal loop and an extremely short mesenteric root. The diagnosis of intestinal volvulus can occur in various circumstances: urgently in the case of acute intestinal obstruction, or in the presence of repeated abdominal pain associated with varying degrees of transit disturbances.

In this paper, we present a case of an 8-year-old girl admitted for the management of cystic dilation of the common bile duct associated with intestinal volvulus, which was surgically treated with a favorable outcome.

CASE PRESENTATION

An 8-year-old girl was admitted for management of abdominal distension with chronic vomiting. Clinical examination revealed a firm mass in the right hypochondrium, tender to palpation and fixed in relation to the deep plane. Abdominal ultrasound and subsequent CT scan (Figure 01) suggested a voluminous intra-peritoneal cystic lesion at the hepatopancreatic junction causing dilation of the intrahepatic bile ducts. An anomalous positional finding of the superior mesenteric pedicle, forming a whirlpool-like image, raised suspicion of intestinal volvulus on an incomplete common mesentery.

Exploratory laparotomy revealed a massive cystic dilation of the common bile duct (Figure 02) adherent to the greater omentum and liver, along with intestinal volvulus with the first loop adjacent to the last loop and the third loop passing through the trans-mesenteric position (Figure 03). Dissection and resection of the mass were performed, followed by devolvulation

Citation: Ayoub Boutahar, Abderrahim Kamli, Mohammed Mimouni, Othmane Alaoui, Abdelhalim Mahmoudi, Khalid Khattala, Youssef Bouabdallah. Association of Cystic Dilatation of the Common Bile Duct and Intestinal Volvulus in Children. SAS J Surg, 2024 Mar 10(3): 370-374.

of the bowel and Bilio-digestive anastomosis using a mounted intestinal loop according to Roux-en-Y.

Post-operative course was marked by onset of abdominal pain, prompting a follow-up abdominal ultrasound revealing compartmentalized collections

beneath the liver and at the hepatopancreatic junction, which regressed after 10 days of antibiotic therapy. After 3 months of follow-up, the patient remained asymptomatic with no abdominal distension and effective bowel movement. A follow-up CT scan showed no intra-abdominal collections (Figure 04).

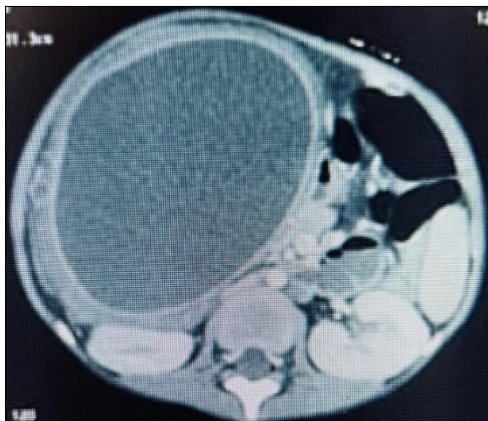


Figure 01: CT Scan: Voluminous intra-peritoneal cystic lesion at the hepatopancreatic junction

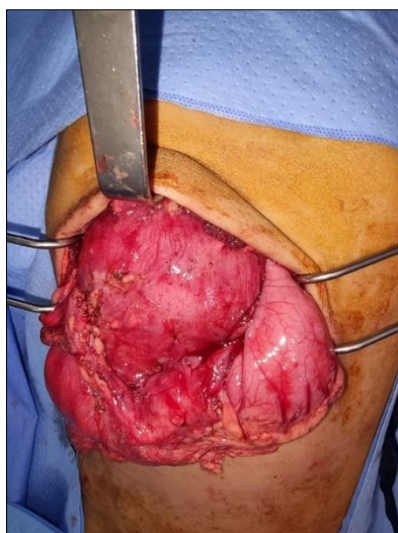


Figure 02: Exploratory laparotomy: Massive cystic dilation of the common bile duct

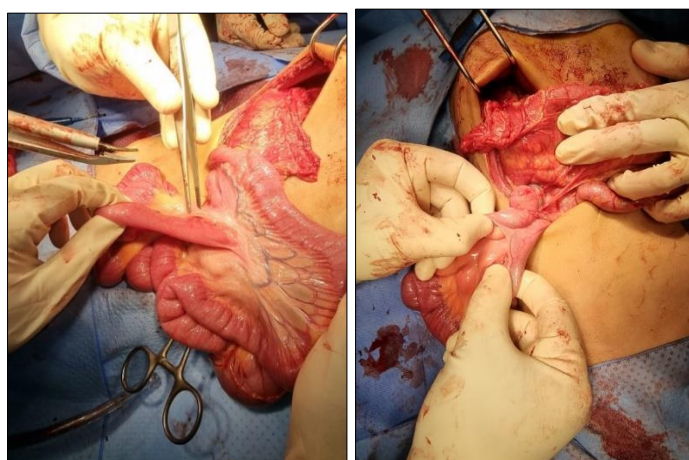


Figure 03: Exploratory laparotomy: Intestinal volvulus with the first loop adjacent to the last loop and the third loop passing through the trans-mesenteric position

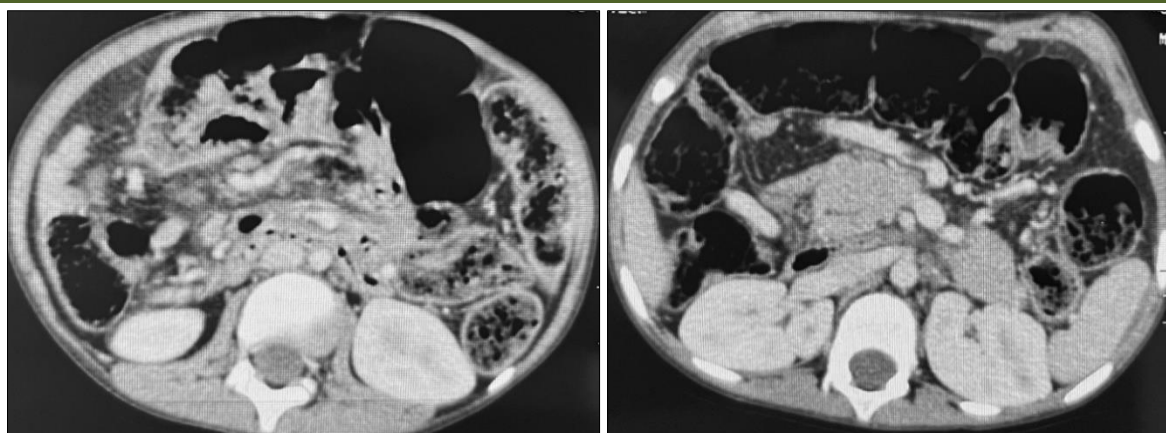


Figure 04: A follow-up CT Scan: No intra-abdominal collections.

DISCUSSION

Cystic dilatations of the main bile ducts are rare congenital malformations (1 in 13,000 births) [4]. This condition predominantly affects females [5], and can occur at any age, but it is more commonly observed in children, adolescents, and young adults. More than half of the cases are detected before the age of 15, with only 8% of cases occurring after the age of 40 [6].

Several theories have been proposed to explain the origin of the malformation. Yotsuyanagi [7], suggests that excessive proliferation of epithelial cells in the primitive bile duct during the embryonic phase, when the bile ducts have a solid structure, occurs. This proliferation, more active in the proximal segment of the bile duct rather than the distal segment, would be followed by hyper-vacuolization leading to abnormal dilation and proximal stenosis of the distal end of the bile ducts. Babbitt's theory [8], is based on an abnormality in the relationship between the main bile duct and the pancreatic duct. The anomaly involves the confluence of the two ducts upstream of the ampulla of Vater, promoting the reflux of pancreatic juice into the main bile duct. The third theory is that of achalasia of the lower segment of the common bile duct [9].

In contrast, for intestinal malrotations, the interruption of intestinal rotation at 180° results in a position where the ileocecal junction is fixed in the subhepatic region [10-15]. This adhesion, if located opposite the duodenum, can inconsistently cause extrinsic compression of the first or second part of the duodenum, leading to "Ladd's bands". The duodenojejunal angle is located to the right of the spine. Consequently, the first jejunal loop and the last ileal loop are in close proximity to the superior mesenteric axis and very close to each other. Sometimes, there may even be a congenital adhesion between the mesentery of these two intestinal loops ("Pellerin's mesenteric fusion" [16]. In this 180° position, the mesenteric root is extremely short, and the entire small intestine is "pedunculated" on its superior mesenteric vascular axis. This position, known as "incomplete common mesentery," carries a

high risk of total small bowel volvulus due to the shortness of the mesenteric root and its lack of adhesion.

The pathophysiology of these two conditions are indeed different, which is why the presence of both pathologies together is likely very uncommon and may not have been reported previously.

The diagnosis of intestinal malrotation usually is made in the neonatal period because bilious vomiting, which is the most frequent symptom of the disease in the first month of life, prompts closer examinations for duodenal obstruction [17]. In our rare case, however, congenital midgut malrotation may be asymptomatic during infancy and present with recurrent intestinal symptoms later. And the classic triad of abdominal pain, jaundice, and abdominal mass was not present. So, an abdominal ultrasound and subsequent CT scan was performed and suggested a voluminous intra-peritoneal cystic lesion at the hepatopancreatic junction causing dilation of the intrahepatic bile ducts. An anomalous positional finding of the superior mesenteric pedicle, forming a whirlpool-like image, raised suspicion of intestinal volvulus on an incomplete common mesentery. This prompted us to perform emergency surgical exploration.

A massive cystic dilation of the common bile duct was found, adherent to the greater omentum and liver, along with intestinal volvulus with the first loop adjacent to the last loop and the third loop passing through the trans-mesenteric position. Dissection and resection of the mass were performed, followed by devaluation of the bowel and Bilio-digestive anastomosis using a mounted intestinal loop according to Roux-en-Y. This is generally described in the management of these two pathologies.

In congenital cystic dilatation of the common bile duct, surgical treatment is essential, and the controversy between advocates of internal drainage and those of resection is currently settled in favor of the latter [18].

External drainage by choledochotomy and placement of a Kher drain is currently abandoned. However, it may be established in specific circumstances such as cases of cholangitis, perforation, fissure, or acute pancreatitis.

Internal drainage in the form of a cysto-duodenostomy or, preferably, a cysto-jejunostomy over an excluded loop, which more effectively prevents intrabiliary reflux, appears to be a simple solution but cannot be adopted for several reasons: recurrence of symptoms, frequency of re-interventions, and secondary malignancy. The work of Powell *et al.*, [19], has clearly demonstrated the frequency of complications, deaths, and re-interventions following cysto derivation, figures significantly higher than those observed after resection of the bile ducts.

Total excision of the cystic dilation, followed by a hepaticojejunostomy over an excluded loop, is the logical operation and should always be chosen when possible. From a technical standpoint, this resection should be as complete as possible and extend upward along the hepatic duct, even up to the confluence based on radiological and intraoperative findings [20]. Downward, care should be taken to avoid traumatizing the pancreatic parenchyma, and ligation of the distal common bile duct should be just upstream of the duodenum. Duodeno-pancreatectomy is an excessive gesture for a benign condition; however, degeneration of the intra-pancreatic bile duct and long common duct remains possible, although to date no such cases have been reported in the literature.

After division of the vascular arcade, the jejunum is sectioned at the level of the second or third loop, and the excluded loop is brought up transmesocolically in front of the second duodenum and closed at its end by mechanical stapling or suturing. The bilioenteric anastomosis is performed on the antimesenteric border of the elevated loop. Jejunal continuity is restored by an end-to-side anastomosis. To prevent reflux, the excluded loop should have a length of 70 cm.

Treatment of volvulus in intestinal malrotation is a surgical emergency. The Ladd procedure remains the standard of care, both in adults and children. It involves a midline laparotomy followed by reduction of the volvulus by detorsion, division of adhesions causing shortening of the mesenteric root, fixation of the intestine in complete mesenteric rotation to prevent recurrence, and appendectomy as a routine measure.

Early postoperative complications that may occur are mainly infectious and should be prevented by meticulous surgical technique and adherence to aseptic care. Prolonged ultrasound and laboratory monitoring are necessary to detect the occurrence of late complications.

CONCLUSION

The combination of a Dilatation of the common bile duct with a volvulus of the small bowel is an exceptional situation, characterized by an unusual clinical and radiological presentation, thus posing a real diagnostic and therapeutic challenge.

REFERENCES

1. Finech, B., Narjis, Y., El Mansouri, M. N., Diffaa, A., Samlani, Z., Krati, K., ... & Essaadouni, L. (2011). Dilatation kystique du cholédoque et maladie de von Recklinghausen. *J. Afr. Hépatol. Gastroentérol*, 5(2), 123-125.
2. Olbourne, N. A. (1975). Choledochal cysts. A review of the cystic anomalies of the biliary tree. *Annals of the Royal College of Surgeons of England*, 56(1), 26.
3. Alonso-Lej, F. (1959). Congenital choledochal cyst, with a report of 2, and an analysis of 94, cases. In *Int Abstr Surg* (Vol. 108, pp. 1-30).
4. Anglade, E., Aubé, C., Lebigot, J., Croquet, V., Loisel, D., Coupris, L., & Caron, C. (2000). Pretherapeutic assessment of congenital dilatation of the common bile duct by cholangiopancreatography-MRI. *Archives of Pediatrics*, 7 (1), 49-53.
5. Gigot, J. F., Nagorney, D. M., Farnell, M. B., Moir, C., & Ilstrup, D. (1996). Bile duct cysts: a changing spectrum of presentation. *Journal of Hepato-Biliary-Pancreatic Surgery*, 3, 405-411.
6. Faïk, M., Halhal, A., Oudanane, M., Housni, K., Ahalat, M., Baroudi, S., M'jahed, A., & Tounsi, A. (1999). Dilatation kystique du cholédoque compliquée d'angiocholite (à propos de 2 cas) *Médecine du Maghreb*, 76.
7. Yotuyanagi, S. (1936). Contribution to the etiology and pathogeny of idiopathic cystic dilatation of the common bile duct with report of three cases: a new etiological theory based on supposed unequal epithelial occlusion of the primitive choledochus. *Gann*, 30, 601-652.
8. Babbitt, D. P. (1969). Congenital choledochal cyst: new etiological concept based on anomalous relationship s of the common bile duct and pancreatic bubl. *Ann Radiol (Paris)*, 12, 231-40.
9. Singham, J., Yoshida, E. M., & Scudamore, C. H. (2009). Choledochal cysts: part 2 of 3: Diagnosis. *Canadian Journal of Surgery*, 52(6), 506.
10. Peycelon, M., & Kotobi, H. (2012). Complications des anomalies embryologiques de la rotation intestinale: prise en charge chez l'adulte. EMC - Techniques chirurgicales - *Appareil digestif*, 7(4), 1-12.
11. Plouard, C., Rivoal, E., Broussine, L., Blondin, G., & Trellu, X. (2000). Volvulus du grêle sur mésentère commun: intérêt de l'échographie doppler. À propos d'un cas. *Journal de radiologie (Paris)*, 81(2), 151-153.
12. Coulibaly, M., Boukatta, B., Derkaoui, A., Sbai, H., Ousadden, A., & Kanjaa, N. (2015). Volvulus of the

- small intestine on incomplete common mesentery, a fearsome rare complication in adults: about 1 case. *Pan African Medical Journal*, 20(1).
13. Gamblin, T. C., Stephens Jr, R. E., Johnson, R. K., & Rothwell, M. (2003). Adult malrotation: a case report and review of the literature. *Current surgery*, 60(5), 517-520.
 14. Jarry, J., Razafindratsira, T., Bodin, R., Lepront, D., & Durand-Dastes, F. (2008). À propos d'un cas de mésentère commun complet de l'adulte révélé par une complication occlusive. *La Presse médicale (1983)*, 37(11), 1689-1692.
 15. Yousefzadeh, D. K. (2009). The position of the duodenojejunal junction: the wrong horse to bet on in diagnosing or excluding malrotation. *Pediatric radiology*, 39, 172-177.
 16. Fukuya, T., Brown, B. P., & Lu, C. C. (1993). Midgut volvulus as a complication of intestinal malrotation in adults. *Digestive diseases and sciences*, 38, 438-444.
 17. Kume, Y., Fumino, S., Shimotake, T., & Iwai, N. (2004). Intestinal malrotation with midgut volvulus in a 10-year-old girl. *Journal of Pediatric Surgery*, 39(5), 783-784. doi: 10.1016/j.jpedsurg.2004.03.028.
 18. Baumann, R., Wittersheim, C., & Dron, K. (1997). Dilatations kystiques congénitales du cholédoque. *Hépatogastro & Oncologie Digestive*, 4(4), 281-6.
 19. POWELL, C. S., SAWYERS, J. L., & REYNOLDS, V. H. (1981). Management of adult choledochal cysts. *Annals of surgery*, 193(5), 666-676.
 20. Okada, A., Nakamura, T., Okumura, K., Oguchi, Y., & Kamata, S. (1987). Surgical treatment of congenital dilatation of bile duct (choledochal cyst) with technical considerations. *Surgery*, 101(2), 238-243.
 21. Peycelon, M., & Kotobi, H. (2012). Complications des anomalies embryologiques de la rotation intestinale: prise en charge chez l'adulte. *EMC - Techniques chirurgicales - Appareil digestif*, 7(4), 1-12.