

Hydatid Cyst in Leg Calves Simulating a Deep-Vein Thrombosis

El Mehdi Elalouani^{1*}, Moncef Boufettal¹, Bassir Reda Allah¹, Mohamed Saleh Berrada¹

¹Department of Traumatology and Orthopedics, Ibn Sina Hospital-Rabat, Morocco

DOI: [10.36347/sasjs.2024.v10i05.017](https://doi.org/10.36347/sasjs.2024.v10i05.017)

| Received: 11.04.2024 | Accepted: 16.05.2024 | Published: 21.05.2024

*Corresponding author: El Mehdi Elalouani

Department of Traumatology and Orthopedics, Ibn Sina Hospital-Rabat, Morocco

Abstract

Case Report

Introduction: The localization of hydatid cysts in muscles is rare, even in endemic countries [1, 2]. This disease remains a major cause of morbidity worldwide. We report a case of a rare hydatid cyst in the calves, simulating deep vein thrombosis [DVT], while discussing its clinical and radiological features and its therapeutic management. The diagnosis was initially based on imaging and immunological reactions, and was confirmed by histology. **Case Presentation:** we report the case of a 36-year-old woman of rural origin, with a history of contact with dogs, referred to the emergency department with suspected thrombophlebitis of the lower limb, 3 days old. Palpation revealed a small, poorly defined mass on the posteromedial aspect of the leg, ultrasound revealed a deep collection in the upper 1/3 of the left leg, with multiple inflammatory lymph nodes in the left inguinal region. MRI revealed a heterogeneous liquid lesion formation. The patient underwent surgery, finding a formation measuring 13×11×3cm, which was completely resected. **Conclusion:** Soft tissue hydatid cysts are a rare localization of *Echinococcus granulosus*, and the detection of hydatid cysts when DVT is suspected underlines the continuing public health challenge posed by *Echinococcus*.

Keywords: Hydatid cyst, Calf, Deep vein thrombosis.

Copyright © 2024 The Author(s): This is an open-access article distributed under the terms of the Creative Commons Attribution 4.0 International License (CC BY-NC 4.0) which permits unrestricted use, distribution, and reproduction in any medium for non-commercial use provided the original author and source are credited.

INTRODUCTION

Hydatid disease, also known as echinococcosis, is a zoonotic illness, that remains a major cause of morbidity worldwide. Man is a parasitic dead end (accidental host), contaminated by ingestion of embryonated eggs. The preferred sites for human echinococcosis are the liver and lungs, accounting for 85% of cases [3]. Involvement of the musculoskeletal system is uncommon, even in endemic countries [1, 2]. A hydatid cyst affecting the muscles may manifest as a mass of soft tissue in the affected muscle, which may be confused with a soft tissue tumor in appearance. Most cases are usually asymptomatic, and when symptoms are apparent due to compression of adjacent structures enlarging cysts. We report a case of hydatid cyst of the calf, simulating DVT. We describe its clinical and radiological aspects, and discuss its therapeutic management.

1. CASE PRESENTATION

1.1. Patient information

We present a 36-year-old lady, from a rural origin, she reports the notion of being in contact with dogs, with a pathological history of nephrectomy on pyonephrosis of the right kidney in 2015. Admitted to the emergency department for suspicion of thrombophlebitis of the lower limb due to oedema of the left lower limb, which had been evolving for 3 days, in a context of apyrexia with no change in general condition.

1.2. Clinical findings

During examination, both calves were found to be asymmetric with redness; palpation revealed a warm limb, with a small, poorly defined mass on the posteromedial aspect of the leg, adherent to the deep plane, tender to palpation and quivering, Homans positive (Fig 1) lower limb Venous Doppler revealed absence of signs of DVT.

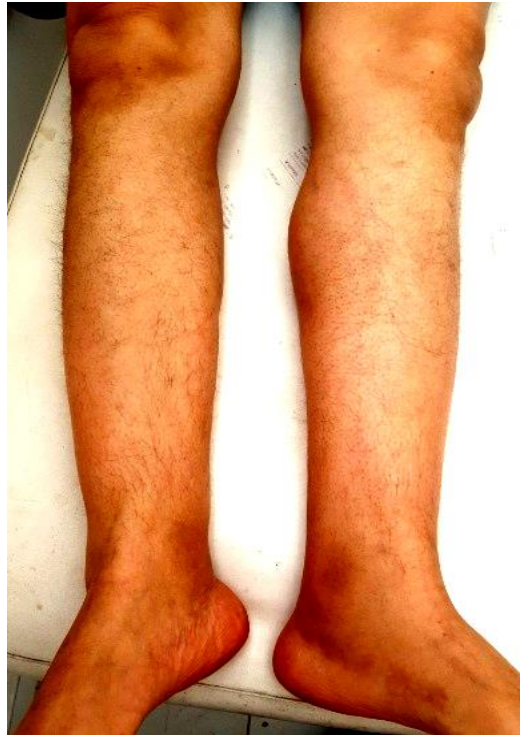

Figure 1: Asymmetry of both calves with redness

Ultrasound revealed a deep collection adjacent to the muscles of the posteromedial section of the upper 1/3 of the left leg, heterogeneous, well-limited and thick-walled, measuring 52×20mm [20mm from the skin],

associated with thickening of the skin [12mm] and infiltration of subcutaneous fat, probably related to an abscess of the posteromedial side of the leg (Fig 2).

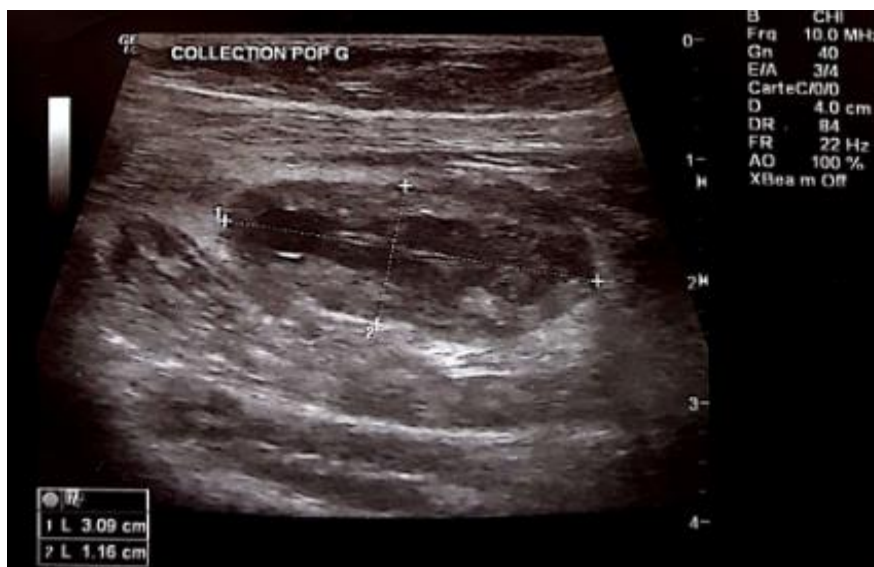

Figure 2: Deep collection in the muscles of the posteromedial section of the upper third of the leg, revealed by ultrasound

Multiple left inguinal inflammatory lymph nodes were noted, with no knee or ankle joint effusion.

MRI reveals a well-circumscribed, heterogeneous, liquid lesion formation in the posteromedial muscular compartment of the upper 1/3 of the left leg below the left popliteal fossa, involving the medial head of the gastrocnemius muscle and the soleus

muscle. The mass is oval-shaped with a long axis parallel to the cutaneous plane, in heterogeneous T1 hypersignal and intermediate T2 hypersignal, and displays multiple millimetric liquid vesicles in T1 hypersignal, frank T2 hypersignal, the largest of which measures 7 to 8 mm and is in DW1 hypersignal, with no diffusion restriction at the level of the intra-lesional vesicles, it enhances around

the periphery in relatively thin section, as well as at the level of its incomplete septates (Fig 3).

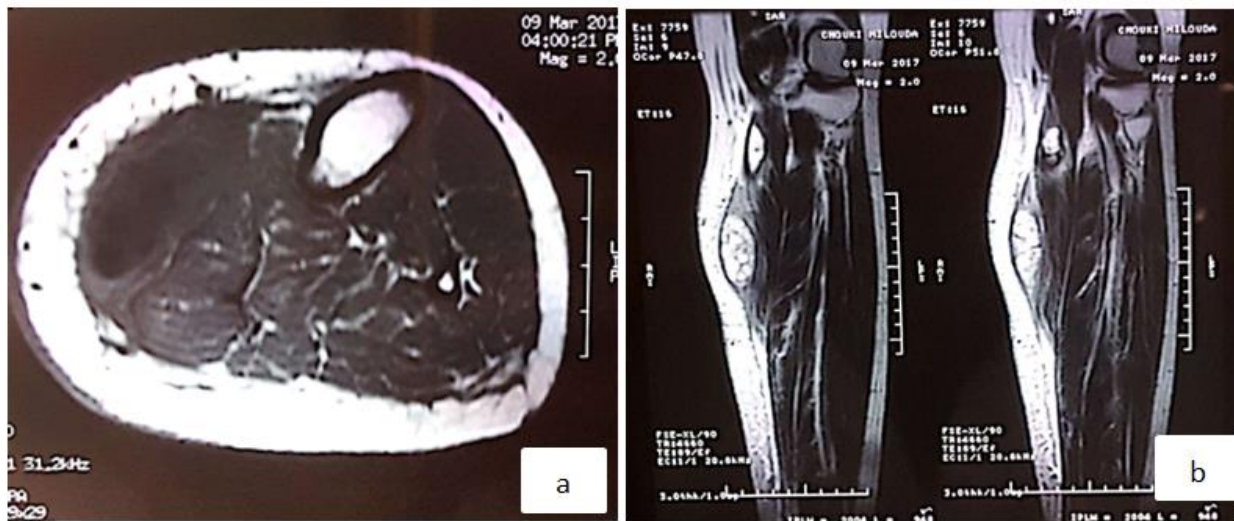

Figure 3(a) and (b): Leg MRI reveals a well-circumscribed heterogeneous liquid lesion formation in the posteromedial muscular compartment, with heterogeneous T1 hyposignal and intermediate T2 hypersignal, and multiple millimetric liquid vesicles in T1 hyposignal, frank T2 hypersignal

1.4. Therapeutic intervention

The patient underwent surgery on 21-03-2017 with a posteromedial approach to the leg, finding a formation weighing 123g and measuring 13×11×3cm resected completely (Fig 4).

Cross-section reveals a 9cm-wide polycystic necrotic focus with translucent membranous content, located 0.3cm from the deep border covered by a

7×4×0.3 muscle flap and 1.5cm from the nearest excisional border.

Pathological examination: adipose conjunctivo-muscular tissue housing a formation lined by an anhistoc cuticle with a laminated appearance. The cystic wall is fibrous, extensively reshaped by a polymorphous inflammatory infiltrate rich in eosinophil polynuclear cells and foamy histiocytes, with a foreign-body granulomatous reaction.

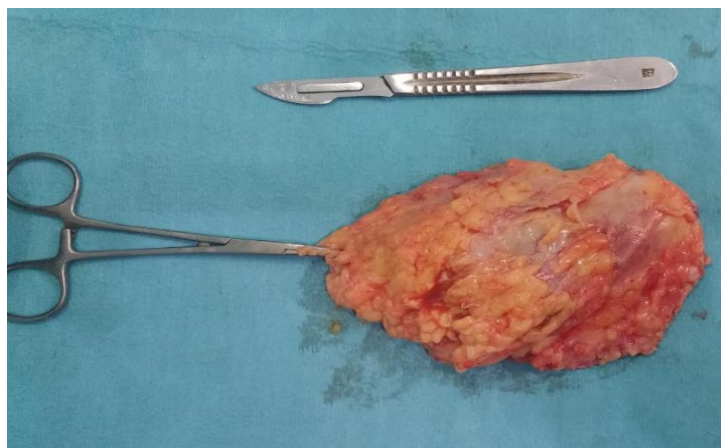


Figure 4: Anatomopathological examination of the surgical specimen: formation weighing 123g and measuring 13×11×3cm completely resected

2. DISCUSSION

Hydatid disease is prevalent in specific regions worldwide, including parts of the Middle East, India, South America, Australia, and New Zealand [1].

Hydatid cyst of the musculoskeletal system is very rare in humans, comprising about 0.5–4% [3-5].

The incidence of muscular hydatid disease is currently declining, despite the spread of high-performance imaging techniques.

Involvement predominates in neck, trunk and limb root muscles, which may be explained by the rich

vascularization of these territories [5]; localization in leg muscles remains rare.

Muscle poses challenges for the development of hydatid larvae due to both muscle contractility and the production of lactic acid [6], which create an inhospitable environment for their growth.

Hexacanth embryos typically encounter barriers in the liver and lungs upon entering the digestive tract, where these organs act as effective filters. Only a minimal number of embryos manage to enter the general circulation, from where they disseminate throughout the body.

Some authors attribute the involvement of less vascularized regions to direct contamination, which occurs secondary to either the bite of an infected animal or the contamination of a wound by the feces of infected animals [7, 8].

This situation likely applies to our patient who has a history of wounds on the same leg. Moreover, muscular hydatid disease is typically primary and isolated, occurring without association with other hydatid locations in 92% of cases [6].

Clinically, the symptoms of muscular hydatidosis lack specificity. Typically, it presents as a slowly evolving soft tissue tumor, resembling conditions such as a cold abscess, myositis, or a calcified hematoma [9].

Complications of muscular hydatidosis can include nerve compression, such as involvement of the sciatic nerve, or infection. In your case, the presence of unilateral cysts in the leg, accompanied by calf edema and pain, initially raised suspicion of deep venous thrombophlebitis. However, Doppler ultrasound ruled out DVT, while CT scans indicated the possibility of an abscess. MRI played a crucial role in confirming the diagnosis accurately, as well as in assessing the lesion's anatomical and vascular-nervous relationships, which was essential for preoperative planning.

The biological diagnosis of muscular hydatidosis poses challenges [10]. In our patient's case, hyper eosinophilia was observed. However, it's important to note that hyper eosinophilia is neither consistent nor specific, and immunological reactions often yield negative results when the cyst is not ruptured or altered [9].

Although challenging, biological tests complement clinical and imaging studies in diagnosing muscular hydatidosis and are particularly valuable in monitoring treatment [11]. The persistence of elevated antibody titers, or even their re-elevation observed 6 months to 1-year post-operation, suggests secondary echinococcosis [10].

Biologically, hyper eosinophilia was noted, but hydatid serologies were found to be negative. This is in line with the typical observation that hydatid serology tends to be positive only in cases of active infection or cyst rupture [7, 12].

L'excision des kystes hydatiques des tissus mous peut présenter des difficultés [13]. L'absence de plan de clivage distinct, en particulier en cas d'infection, peut compliquer la kystectomie [7, 13]. Dans notre cas, trois kystes ont été identifiés, deux communiquant au niveau des muscles gastrocnémiens et un non communicant et profond dans le muscle soléaire.

Despite efforts to protect the surgical field with H2O2-soaked compresses, surgical contamination can still occur, particularly in cases of cyst rupture or infection. This can contribute to a relatively high rate of local or distant recurrence [6, 13].

Le traitement médicamenteux à base d'albendazole est essentiel pour obtenir un traitement curatif complet et prévenir la réinfestation. La prophylaxie joue un rôle essentiel en tant que véritable traitement, agissant à tous les niveaux de la chaîne épidémiologique [14].

3. CONCLUSION

Soft-tissue hydatid cysts are uncommon, even in endemic regions, and their localization in the leg is even more rare. The detection of hydatid cysts during investigation for suspected DVT, supported by radiological, clinical, and pathological evidence, underscores the ongoing public health challenge posed by *Echinococcus*. This highlights the persistent need for efforts in both eradication and management.

Conflicts of Interest: The author has no conflicts of interest to declare.

REFERENCES

- Baldelli, F., & Papili, R. (1989). Le diagnostic biologique de récédive. Symposium international dur l'hydatidologie. *Méd. Chir. Dig*, 18, 301-312.
- Saimot, A. G. (1978). Les autres localisations de l'hydatidose. *Rev Prat*, 28(37), 2887-2894.
- Kourias, B. (1961). A propos de 2000 cas de kystes hydatiques opérés. *Presse Méd*, 69(4), 165-168.
- Chigot, J. P., Benhamida, M., & Mercadier, M. (1974). A propos d'un cas de kyste hydatique musculaire. *Gaz méd Fr*, 81, 5313-5317.
- Tissot, E., Putot, J. P., Descos, L., François, Y., & Bretagnolle, M. (1984). Kyste hydatique du psoas. diagnostic grâce au CT scanner. *Journal de chirurgie (Paris. 1908)*, 121(1), 7-9.
- Kehila, M., Allegue, M., Abdessalem, M., Letaief, R., Said, R., & Khalfallah, A. (1987). Le kyste hydatique du muscle psoas. A propos d'un cas. *Journal de radiologie (Paris)*, 68(4), 265-268.

7. Essadki, O., Elhajjam, M., & Kadiri, R. (1996). Kyste hydatique des parties molles. Aspects radiologiques. *Ann Radiol*, 39(3), 135-141.
8. Gignoux, M., & Caltran, M. À. (1969). propos d'un cas de kyste hydatique du creux poplité. *Lyon Chir*, 65, 905-907.
9. Bourée, P., Thulliez, P., & Millat, B. (1982). Hydatidose musculaire du mollet. A propos d'un cas. *Bulletin de la Societe Pathologie Exotique et de ses filiales*, 75(2), 201-204.
10. Ben Ayed, M., Kamoun, N., Makni, K., & Ben Romdhane, K. (1986). Kyste hydatique: 281 cas, dont 86 cas à localisation inhabituelle, observés au cours d'une période de dix ans (1972-1981). *Tunisie médicale*, 64(4), 389-395.
11. Bonitacino, A., Carino, R., & Caratozzolo, M. (1989). L'échographie dans l'hydatidose. Symposium international sur l'hydatidologie. *Méd. Chir. Dig*, 18, 301-312.
12. El Moussaoui, A., Rabii, R., Rais, H., Aboutaieb, R., Meziane, F., El Mrini, M., & Benjelloun, S. (1997, January). Hydatid cyst of the psoas muscle. Apropos of a case. In *Annales D'urologie*, 31(6-7), 357-360.
13. Hammami, T., Noomane, F., Ketata, M., Ganneme, Y., Nasr, M., & Zouari, K. (2002). Kyste hydatique musculaire de la cuisse. À propos de trois observations. *Revue de chirurgie orthopédique et réparatrice de l'appareil moteur*, 88(2), 193-196.
14. Agoumi, A. (2003). Précis de parasitologie médicale. Collection MEDIKA édition Horizons internationales, 131-14.