

## Giant Endocervical Polyp with Malignant Characteristics in an Adolescent

Elizabeth Veliz-B.<sup>1\*</sup>, José Reyes-C.<sup>1</sup>, Kevin Albuja-D.<sup>2</sup>, Denisse Salazar-D.<sup>3</sup>, Erick Jara-L.<sup>2</sup>, Aarón Lascano-C.<sup>4</sup>, Santiago Zamora-L.<sup>5</sup>, Roberto Meléndez-C.<sup>6</sup>, Martín Erazo-S.<sup>7</sup>

<sup>1</sup>Surgical Oncologist, Sociedad de Lucha Contra el Cáncer (SOLCA) Hospital, Guayaquil - Ecuador

<sup>2</sup>General Surgery PG-Y4 Resident Sociedad de Lucha Contra el Cáncer (SOLCA) Hospital, Guayaquil - Ecuador

<sup>3</sup>Medical Doctor, "Manantial de Guangalá" Health Center, Santa Elena – Ecuador

<sup>4</sup>Medical Doctor, Doctor Enrique Ortega Moreira General Hospital, Durán – Ecuador

<sup>5</sup>Medical Doctor, International University of Ecuador (UIDE), Quito – Ecuador

<sup>6</sup>Medical Doctor, "Chitán de Navarrete" Health Center, Carchi – Ecuador

<sup>7</sup>Medical Doctor, Alfredo Paulson's Specialty Hospital, Guayaquil – Ecuador

DOI: [10.36347/sasjs.2024.v10i07.001](https://doi.org/10.36347/sasjs.2024.v10i07.001)

| Received: 22.05.2024 | Accepted: 27.06.2024 | Published: 02.07.2024

\*Corresponding author: Elizabeth Veliz-B.

Surgical Oncologist, Sociedad de Lucha Contra el Cáncer (SOLCA) Hospital, Guayaquil - Ecuador

### Abstract

### Case Report

**Introduction:** A cervical polyp is a flexible, friable, pedunculated neoplasm, mostly originating from the endocervical area. It is considered giant when it is >4 cm. Most are benign but they must be removed and subjected to histopathologic examination because they may present malignancy. **Clinical Case:** A 13-year-old female patient, with no personal pathological personal or familiar history, was referred from another health center due to a 1-year history of a vaginal tumor with apparently no underlying cause. Physical examination showed a red, multilobulated, vaginal tumor of approximately 10 cm long, with mucus around it, foul-smelling, easy bleeding, painful on palpation, protruding from vaginal introitus with a deep pedicle. The patient underwent surgery where the excision of the vaginal tumor extending to the exocervix was performed. **Conclusion:** In this case, due to the initial clinical characteristics, a malignant pathology (such as rhabdomyosarcoma) may be suspected, thus, complementary imaging and laboratory studies need to be performed, to rule out this diagnosis and offer an adequate and well oriented surgical treatment; a subsequent definitive histopathological study needs to be conducted to confirm that the lesion is compatible with an endocervical polyp, determining the patients prognosis and follow-up requirements.

**Keywords:** cervix uteri, polyps, surgical specialties, gynecologic surgical procedures.

Copyright © 2024 The Author(s): This is an open-access article distributed under the terms of the Creative Commons Attribution 4.0 International License (CC BY-NC 4.0) which permits unrestricted use, distribution, and reproduction in any medium for non-commercial use provided the original author and source are credited.

## INTRODUCTION

A cervical polyp is a flexible, friable, pedunculated neoplasm, mostly originating from the endocervical area, but some are located exocervically. It is common in adult women [1, 2]; and its etiology is unknown. Most are benign, however they must be removed and subjected to histopathologic examination because they may present malignant changes. Usually, the size of the polyp is less than 2 cm, but it is considered giant when it is greater than 4 cm [2]. The most common symptom of cervical polyp is bleeding [3]. Polyps are easy to diagnose by general inspection, but ulcerated and atypical-looking growths must be distinguished from other pedunculated fibroids that arise in the lower part of the uterus [4, 5]. The treatment is basically the removal of the polyp [2, 6].

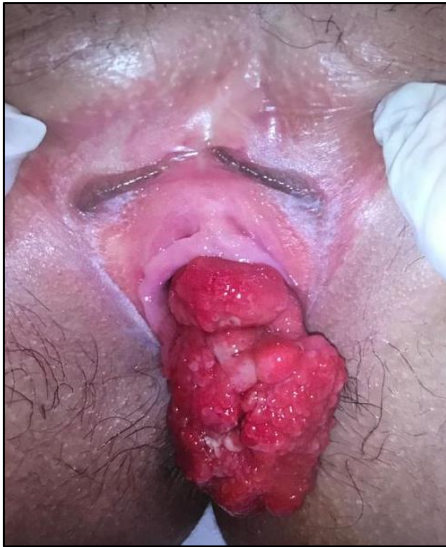## CLINICAL CASE

A 13-year-old female patient, with no personal pathological personal or familiar history, was referred from another health center due to a 1-year history of a vaginal tumor with apparently no underlying cause, with a biopsy histopathological report of eroded polypoid submucosal mesenchymal neoplasia with reactive stromal atypia suggestive of rhabdomyosarcoma, the immunohistochemistry examination showed negative CD-45 and CD-138; vimentin, actin, estrogen receptor and progesterone receptor were positive for neoplastic cells, myogenin was not performed due to the lack of the reagent; and complementary images were not available in this health center.

At the Gynecological - Oncological Surgery service the physical examination showed a red, multilobulated, vaginal tumor of approximately 10 cm long, with mucus around it, foul-smelling, easy bleeding,

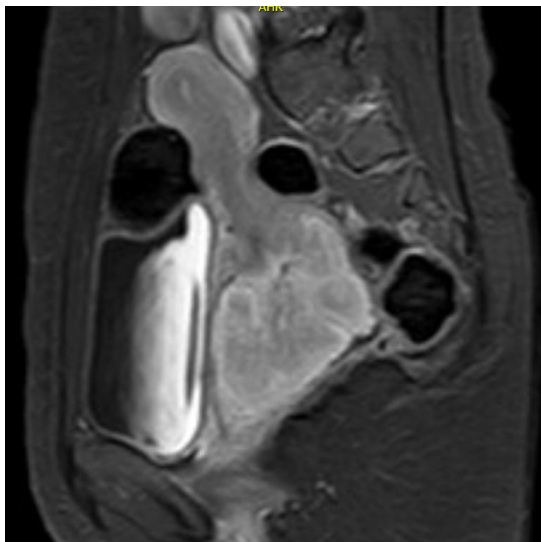
**Citation:** Elizabeth Veliz-B., José Reyes-C., Kevin Albuja-D., Denisse Salazar-D., Erick Jara-L., Aarón Lascano-C., Santiago Zamora-L., Roberto Meléndez-C., Martín Erazo-S. Giant Endocervical Polyp with Malignant Characteristics in an Adolescent. SAS J Surg, 2024 Jul 10(7): 743-746.

painful on palpation, protruding from vaginal introitus with a deep pedicle (Image 1).



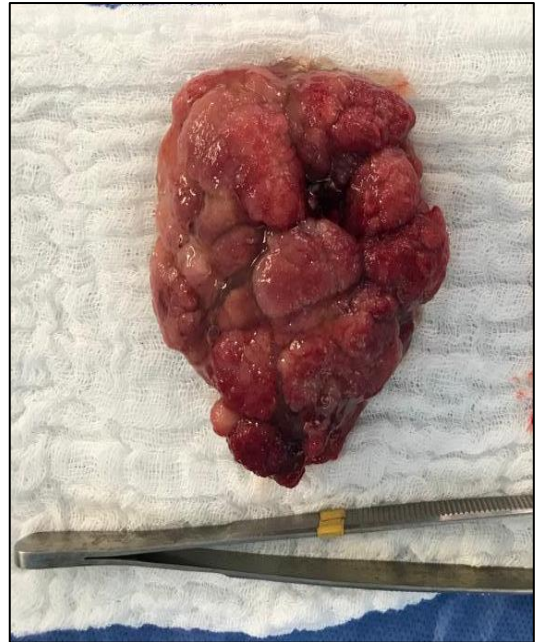**Image 1. Pedunculated lesion that protrudes through the vaginal canal**

Laboratory complementary tests did not show signs of infection or anemia. Pelvic ultrasound reported an image of an oval tumor with defined hypoechoogenic margins and poor central and peripheral vascularization. Color Doppler measured 9.3 x 4.3 x 7.3 cm, volume of 156 cc, location in the pelvic cavity, thickened endometrium of 1.2 cm, and no endometrial collections are observed. Magnetic resonance of the abdomen and pelvis showed a retro-vesical mass arising from the vagina that captured contrast and splenic changes (Image 2).



**Image 2. Pelvic MRI showing a neo-expansile pedunculated lesion dependent on the exocervix**

The patient underwent surgery where the excision of the vaginal tumor extending to the exocervix was performed (Image 3).



**Image 3. Surgical piece**

The post-surgical histopathologic study reported: a tumor weighing 101 grams, measuring 6.7 x 6.2 x 3.7 cm, with a papillary nodular shape, irregular pinkish-brown color, covered with mucous substance translucent to the whitish section. It was defined as a polypoid lesion with the presence of endocervical mucosecretory epithelium of superficial and glandular lining without atypia, the neoplastic cells were ovoid with hyperchromatic nuclei, located in a higher sub-epithelial density, and stroma with discrete edema and myxoid foci.

For the immunohistochemistry, the following results were reported as positive: Ki67, desmin, vimentin, progesterone receptors, estrogen receptor; and the following as negative: miogenin, msa, cd34, myoglobin, s-100, broad spectrum keratin.

Patient survived the surgery and was discharged home without further complications, at the time she remains in follow-up by the Gynecological - Oncological Surgery service.

## DISCUSSION

A cervical polyp can be denominated as a focal hyperplasia of the cervical epithelium, made up of cylindrical epithelium [4], it is characterized by a reddish color that varies from cherry red to darker, they are flexible, soft, friable, fleshy in appearance, sometimes pedunculated, usually long; and thin or short with a wide base [7,8], which bleed easily on palpation [6, 3]. They can be classified in endocervical when it is located inside the cervical cavity and exocervical, outside the uterine cavity [3].

In Latin America, specifically in Honduras, 21 cases have been reported, including 11 cases of

ectocervix, 7 endocervix, and 3 that have no record [6]. In Ecuador, at the Institute of the Society to Fight Cancer, the statistics from the last report from 2015 do not show polyps of the female reproductive system (international disease classification: CIE10 N84.0 – N84.9) [9].

The etiology of the cervical polyp is undefined [10], but it is associated with chronic inflammation of the cervical canal, and other factors such as hormonal factors, foreign bodies, and multiparity [4, 6, 1]. Generally, most giant cervical polyps occur in nulliparous women [10].

A cervical polyp is a common pathology in adult women [1, 2], affecting around 10%, commonly in multiparous women between 40 and 50 years [11], with a size less than 2 cm [2]. In adolescents it is very rare [1]; currently, in the PubMed database there are no clinical cases reported in adolescents. It is referred to as a benign lesion; some cases are associated with malignancy or premalignant lesions [12].

From another perspective, the giant cervical polyp is rare [13], with a size greater than 4 cm [2, 5, 11, 14] and up to 30 cm [15], these polyps don't represent a greater risk of malignancy [12]. Its presentation is usually single, but multiple polyps have also been reported [15].

Cervical polyps are commonly asymptomatic [4, 7], but they can be symptomatic when the tumor protrudes into the vaginal canal with abnormal intermenstrual, postcoital and postmenopause vaginal bleeding, with a foul-smelling discharge [3, 2, 10, 15]. In the case of the patient, due to the clinical characteristics of the mass that protruded in the vagina, the initial diagnosis was complex and led to suspicion of malignant pathology.

The diagnosis of a giant cervical polyp is discovered incidentally during a routine genital physical examination. These polyps protrude and hang in the vagina, they also ulcerate due to the protrusion and the mechanical trauma that persists, resulting in bleeding, acquiring an appearance suspicious of malignancy; at the tip of the polyp squamous metaplasia may be evident [4, 5].

Imaging diagnosis can be made by hysterosalpingography, ultrasound hysteography or magnetic resonance imaging.

To complement the finding, the histopathological study needs to be conducted [15], where a loose edematous stroma with dilated vascular structures is usually evident and may be covered with columnar, squamous or squamocolumnar epithelium [8, 3]. In the case of the patient, the diagnosis was made hystopathologically and was confirmed with immunohistochemistry, with the following receptors

being positive: KI 67:7%, desmin, vimentin, MSA, estrogen receptors, progesterone receptors, which confirmed that it was a benign lesion, thus ruling out malignant pathology.

Pathologies for differential diagnosis include submucosal fibroids, endometrial polyps, endocervical carcinoma, carcinosarcoma, rhabdomyosarcoma, prolapsed leiomyoma, leiomyoblastoma, cervical lymphoma, and cervical cancer, etc [6, 8, 15].

Rhabdomyosarcoma, considered a malignant pathology, was the initial diagnosis that was suspected because it commonly occurs in childhood [16] and rarely in adulthood. It appears in children under fifteen years mainly in the vagina [17], a characteristic that the patient presented. It is derived from progenitor cells of striated muscle myocytes in various degrees of differentiation. In Immunohistochemistry it is related to the MyoD antibody, as an indicator of this pathology [18]. Several studies have defined that it presents as a benign endocervical polyp, which delays the diagnosis [19].

The treatment of cervical polyp is surgical through a polypectomy [2, 5]. It involves removing and performing a histopathological study of the tissue obtained. In the case of the patient, this procedure was performed; if a complete excision is not performed, the risk of recurrence is 12-15% and this occurs 6-12 months after the excision [6].

## CONCLUSION

This clinical case of giant endocervical polyp, demonstrates that due to the initial clinical characteristics, a malignant pathology (such as rhabdomyosarcoma) may be suspected, thus, complementary imaging and laboratory studies need to be performed, to rule out this diagnosis and offer an adequate and well oriented surgical treatment; a subsequent definitive histopathological study needs to be conducted to confirm that the lesion is compatible with an endocervical polyp, determining the patients prognosis and follow-up requirements.

## REFERENCES

1. Estevinho, C., Pinto, A. R., & Oliveira, C. (2021). A giant cervical polyp in a young woman Pólipo cervical gigante na mulher jovem. *Acta Obstet Ginecol Port*, 15(3), 296-297.
2. Ota, K., Sato, Y., & Shiraishi, S. (2017). Giant polyp of uterine cervix: a case report and brief literature review. *Gynecol Obstet Case Rep*, 3(2), 49-52.
3. Ayala-Peralta, F. D., Luna-Figueroa, A., Carranza-Asmat, C., Guevara-Ríos, E., Castilla-Galvan, J. E., De la-Cruz-Leiva, Y., ... & Apcho-Cruzado, A. (2019). Manejo del pólipo endocervical en la posmenopausia. *Revista Peruana de Investigación Materno Perinatal*, 8(3), 45-48.

4. Tanos, V., Berry, K. E., Seikkula, J., Abi Raad, E., Stavroulis, A., Sleiman, Z., ... & Gordts, S. (2017). The management of polyps in female reproductive organs. *International Journal of Surgery*, 43, 7-16.
5. Giant endocervical polyp: A mimic of mullerian adenosarcoma. A case report with follow-up | Lector mejorado de Elsevier [Internet]. [citado 5 de marzo de 2023]. Disponible en: <https://reader.elsevier.com/reader/sd/pii/S2214330016300426?token=174F9222D878B89EBAEAFB58BCC0B85E3632D8E9E806A43455961B48C7DCB0A930EBE46A59051B8AE4F2DCE2BBC08AC5&originRegion=us-east-1&originCreation=20230306004507>
6. Pereira, L. P., Ramírez, L. C., Rodríguez, J. E., Madrid, J. E., Vallejo, J. S., & Osorio, H. U. (2015). Pólipo cervical gigante de larga evolución. Reporte de un caso. *Archivos de medicina*, 11(4), 5.
7. Antonio, S. H. J., David, C. F., Guillermo, M. Z., & Antonio, R. T. J. (2019). Incidencia de pólipos cervicovaginales en pacientes con vida sexual activa. *Contenido/Contents*, 66(3), 139-142.
8. Benign cervical lesions and congenital anomalies of the cervix - UpToDate [Internet]. [citado 12 de marzo de 2023]. Disponible en: [https://www.uptodate.com/contents/benign-cervical-lesions-and-congenital-anomalies-of-the-cervix?search=polipo%20cervical&source=search\\_result&selectedTitle=1~31&usage\\_type=default&display\\_rank=1](https://www.uptodate.com/contents/benign-cervical-lesions-and-congenital-anomalies-of-the-cervix?search=polipo%20cervical&source=search_result&selectedTitle=1~31&usage_type=default&display_rank=1)
9. casos [Internet]. Tableau Software. [citado 8 de marzo de 2023]. Disponible en: [https://public.tableau.com/views/casos/NumeroCasosGrupo?:embed=y&:showVizHome=no&:host\\_url=http%3A%2F%2Fpublic.tableausoftware.com%2F&:tabs=no&:toolbar=yes&:animate\\_transition=yes&:display\\_static\\_image=no&:display\\_spinner=no&:display\\_overlay=yes&:display\\_count=yes&:showVizHome=no&:loadOrderID=0](https://public.tableau.com/views/casos/NumeroCasosGrupo?:embed=y&:showVizHome=no&:host_url=http%3A%2F%2Fpublic.tableausoftware.com%2F&:tabs=no&:toolbar=yes&:animate_transition=yes&:display_static_image=no&:display_spinner=no&:display_overlay=yes&:display_count=yes&:showVizHome=no&:loadOrderID=0)
10. Mini-hysteroscopy for a married virgin with a tubular ectocervical giant polyp combined with psychosexual dysfunction: a case report - Jing Zhang, Qijun Chen, Yana Liu, Lin Qiao, 2019 [Internet]. [citado 5 de marzo de 2023]. Disponible en: <https://journals.sagepub.com/doi/10.1177/0300060519888369>
11. LAISHRAM, C., TRIVENI, G., AGGARWAL, K., & GUPTA, A. (2022). Giant Cervical Polyp in Primigravida: A Rare Case Report. *Journal of Clinical & Diagnostic Research*, 16(7).
12. Rupke, S., & Zuber, T. J. (1998). Evaluation and management of cervical polyps. *Hospital Practice*, 33(6), 81-82.
13. Aboda, A., Wu, A., Sleeman, K., & McCully, B. (2022). A Case Report on a Rare Cervical Polyp. *Juniper Online Journal of Case Studies*, 13(2), 2-5.
14. Jaroudi, D.A., Hijazi, A. & Lary, S. (2017). Hysteroscopic Resection of a Giant Cervical Polyp with Preservation of Hymen. *J Genit Syst Disord* [Internet]. 2017 [citado 5 de marzo de 2023];06(04). Disponible en: [https://www.scitechnol.com/peer-review/hysteroscopic-resection-of-a-giant-cervical-polyp-with-preservation-of-hymen-62Ga.php?article\\_id=6776](https://www.scitechnol.com/peer-review/hysteroscopic-resection-of-a-giant-cervical-polyp-with-preservation-of-hymen-62Ga.php?article_id=6776)
15. Bahriye, A. (2021). Giant Polyp of the Cervix - A Case Report. *WJGWH*. 18 de octubre de 2021;5(3):1-4.
16. Tapia, O. (2011). Rbdomiosarcoma Embrionario Uterino: Aspectos Morfológicos e Inmunohistoquímicos. *International Journal of Morphology*, 29(4), 1126-1129.
17. CASO CLINICO DEE RABDOMIOSARCOMA EMBRIONARIO CERVICAL. 2017 NOVIEMBRE.pdf.
18. Ahmed, A. A., Habeebu, S., Farooqi, M. S., Gamis, A. S., Gonzalez, E., Flatt, T., ... & Tsokos, M. G. (2021). MYOD1 as a prognostic indicator in rhabdomyosarcoma. *Pediatric blood & cancer*, 68(9), e29085.
19. Rubio, P., Lanzón, A., Vicente, S., & Ruiz, M. Á. (2012). Rbdomiosarcoma embrionario de cérvix uterino en mujer adulta. *Revista chilena de obstetricia y ginecología*, 77(5), 383-387.