

Management of Gynecological and Obstetrical Peritonitis in the General Surgery Department of the Hospital National Ignace Deen Conakry University Hospital (Guinea)

Oulare I, Bah IB^{1*}, Loua M¹, Diallo MH¹, Diallo BP¹, Kaba M¹, Soumaoro LT¹, Fofana H¹, Toure A¹

¹Department of General Surgery, Ignace Deen National Hospital, Conakry Teaching Hospital (Guinea)

DOI: <https://doi.org/10.36347/sasjs.2024.v10i09.018>

| Received: 15.08.2024 | Accepted: 19.09.2024 | Published: 30.09.2024

*Corresponding author: Bah Ib

Department of General Surgery, Ignace Deen National Hospital, Conakry Teaching Hospital (Guinea)

Abstract

Original Research Article

Aim: Was to highlight the methods of management of gynecological and obstetric peritonitis. **Patients and Methods:** This was a retrospective and descriptive study analyzing the records of patients operated on for peritonitis of gynecological or obstetric origin in the general surgery department of the Ignace Deen National Hospital, CHU of Conakry during the period from January 2020 to December 2022. The parameters studied were epidemiological, sociodemographic, clinical and therapeutic. **Results:** Gynaecological and obstetric peritonitis accounted for 15.6% (n=58) of all peritonitis. The mean age of the patients was 27.9 years, with extremes of 17 and 46 years. The majority of patients were married, with multiple gestations, and the average consultation time was 13.4 days. The etiology most frequently encountered was uterine perforation (34%), and the surgical procedure most frequently performed was drainage (all patients) and uterine suture (63.4%). We recorded 3 cases of death (5.2%). **Conclusion:** Gynecological and obstetric peritonitis are both medical and surgical emergencies, mainly affecting sexually active young women, with considerable mortality.

Keywords: Peritonitis, Gynecological, Obstetric, Treatment, Ignace Deen.

Copyright © 2024 The Author(s): This is an open-access article distributed under the terms of the Creative Commons Attribution 4.0 International License (CC BY-NC 4.0) which permits unrestricted use, distribution, and reproduction in any medium for non-commercial use provided the original author and source are credited.

INTRODUCTION

Acute peritonitis of gynecological and obstetrical origin represents a vital emergency requiring hospitalization and rapid therapeutic management. Peritonitis is most often confined to the pelvis, giving rise to pelviperitonitis [1], with uterine perforation being the most common etiology [2]. The low socio-economic level and poor quality of emergency surgical care in our context, which do not allow rapid and adequate management of patients, compromise not only the obstetrical future but also the vital prognosis [3].

The aim of this study was to analyse patients' files in order to highlight the methods of management of gynaecological and obstetric peritonitis.

PATIENTS AND METHODS

This was a retrospective descriptive and analytical cross-sectional study of the records of patients hospitalized and operated on for gynecological and obstetric peritonitis in the general surgery department of the Ignace Deen national hospital, CHU de Conakry.

The study covered the period from January 2000 to December 2022 (3 years).

Patient records were included, including civil status, medical observation, operative report and postoperative follow-up. Frequency, socio-demographic profile, clinical and therapeutic data were analyzed.

RESULTS

We collected 58 cases of gynecological and obstetric peritonitis, representing 15.6% of acute peritonitis cases (n=372).

Table I: Physiognomy of the different etiologies of gynecological and obstetric peritonitis;

Etiologies	Number (N= 58) (%)	Percentage
Caesarean section	24	41,4
Abortion	18	31
Pyo ovary	11	19
Pyo salpinx	05	8,6

The average age of the patients was 27.9 years, with extremes of 17 and 46 years. The 20-30 age group was the most affected (43.1%), and the patients were predominantly married with multiple gestations.

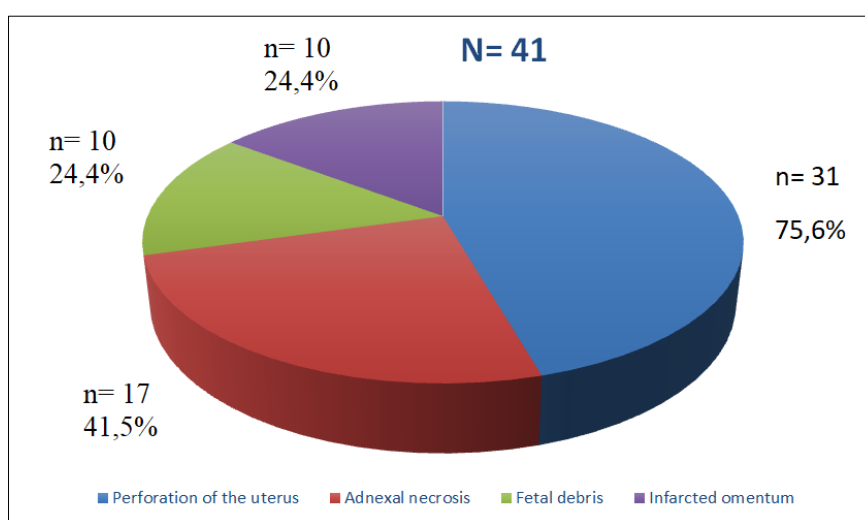
Housewives were the socio-professional group most affected, with 25 cases (43.1%).

The average consultation time was 13.4 days after the onset of the first symptoms of the disease (extremes: 2 and 60 days). In the series, 27.6% of cases were referred from health centers and private clinics.

Peritonitis was diagnosed clinically in all cases, and an unprepared abdominal X-ray was performed in 96.5% of cases (n=56). Biologically, an infectious syndrome was observed in the majority of patients, with hyperleukocytosis ranging from 11,000 to 27,000 G/l.

Caesarean section was the most frequent etiology, accounting for 41.4% of cases.

Laparotomy in all cases revealed the lesions shown in figure 1.

**Figure 1: Physiognomy of lesions found intraoperatively**

The lesions were treated and the abdominal cavity cleaned and drained.

The outcome was favorable in 84.5% of cases, but we recorded 6 cases (10.3%) of surgical site infection and 6 deaths (5.2%).

The average hospital stay was 15.8 days, with extremes of 5 and 30 days.

DISCUSSION

In this retrospective study covering a 3-year period, gynaecological and obstetric peritonitis accounted for 15.6% of all acute peritonitis. This rate is lower than that of Adisso S *et al.*, [3], in Benin in 2006, who reported a frequency of 93.2%. This may be explained by the fact that our study was carried out in a general surgery department and not in a gynecology department.

In this study, gynecological and obstetrical peritonitis mainly affected young women, uneducated, married, housewives in full genital activity, and it remains above all a pathology of the young subject [1]. Most of the patients were multiparous. Our results differ from those of Fenomanana MS *et al.*, [4], in 2009 in Madagascar, who reported that 326 patients had no children.

In our series, the delay in consultation was long. In Senegal, Cissé C.T *et al.*, [5], in 1999 reported an average of 7 days. Clinically, abdominal pain was the most constant functional sign (98.3%), and the majority of patients presented with a general fever. This study is similar to that of Massamba MD *et al.*, [6].

In 2019 in Congo Brazzaville, who reported that, on admission, all patients presented with abdominal pain, fever and altered general condition (44.4%). Like all peritonitis, peritonitis of gynaecological and obstetrical origin is clinically manifested by a peritoneal

syndrome found in all patients presenting with abdominal pain that can have repercussions on general condition.

With regard to physical signs, distension, abdominal defensiveness and a bulging, painful Douglas were frequently observed in most patients. Foumane P *et al.*, [7], in 2013 in Cameroon reported a Douglas cry (19.2%), adnexal mass (19.9%), leucorrhoea (82.4%), contracture (10.2%) and abdominal defence (71.3%). The diagnosis of peritonitis is essentially clinical, with abdominal contracture or defense being the pathognomonic sign.

A blood count and an unprepared abdominal X-ray are almost systematically requested in the event of acute peritonitis in our daily practice, due to their ease of execution and low cost. PSA revealed a diffuse, hydroaeric level of graying. This result is similar to those of Diop B *et al.*, [8], in 2017 in Senegal, who reported an infectious syndrome in all their patients, with hyperleukocytosis, accelerated ESR and pelvic hydroaeresis in 38 cases. However, morphological radiological examinations are rarely carried out due to lack of emergency availability, despite their paramount importance in any acute abdominal pain syndrome [9].

The most common etiology in our study was Caesarean section. This result differs from that of Engband J P *et al.*, [10], in 2021 in Cameroon, who found that ruptured ectopic pregnancy (27.5%) and postabortion uterine perforation (25%) were the major etiologies. This could be explained by the increasing use of unlicensed gynaecological practices, which can lead to post-Caesarean complications.

During the course of the study, most patients underwent surgical treatment. Our result differs from that of Foumane P *et al.*, [7], in 2013 in Cameroon, who reported 81.5% of patients receiving medical treatment and only 18.5% receiving surgical management. This may be explained by the advanced stage of peritonitis in which the patients were received.

The medical treatment differs from that of Harioly Nirima MOJ *et al.*, [11], in 2009 in Madagascar, who reported the frequent use of triple therapy based on imidazole, betalactamine and aminoglycoside. The French consensus conference [12], in 2001 recommended first-line treatment with either a combination of amoxicillin/clavulanic acid and gentamycin, or a combination of ticarcillin + clavulanic acid and gentamycin, or cefoxitin, cefotaxime or ceftriaxone and imidazole.

Surgical procedures were performed according to etiology, and uterine perforation was the most common lesion. Our results differ from those of Adenuga A T *et al.*, [13], in Nigeria in 2020, who reported a high frequency of ileal lesions (43%). Our result can be

explained by Caesarean section, the most frequent etiology in our study.

Postoperative management was straightforward in the majority of cases. Our result is similar to that of Akila B *et al.*, [14], in 2018 in Togo, who reported 85.4% of cured patients. Correct management would explain our result. The average hospital stay was 15 days in our study. This result is similar to that of Ka I *et al.*, [15], in Senegal in 2016, who allowed their patient to return home after 15 days.

CONCLUSION

Gynecological and obstetric peritonitis are both medical and surgical emergencies, mainly affecting sexually active young women, with considerable mortality.

Conflicts of Interest: The authors declare that there were no conflicts of interest in the scientific writing of this work.

Informed Consent Statement: All authors appearing in this article share equally and agree to the publication of this article in your journal.

REFERENCES

1. Adamou, H., Adakal, O., Magagi, I. A., Doutchi, M., Garba, S. O., Halidou, M., ... & Sani, R. (2020). Péritonites Aiguës d'Origine Gynécologique à l'Hôpital National de Zinder, Niger. *European Scientific Journal*, 16, 275-280.
2. Toure, A., Soumaoro, L. T., & Sy, T. (2008). Les pelvipéritonites : à propos de 122 cas observés à l'hôpital national Ignace Deen de Conakry, *Annales de la SOGGO*, 3(10), 128-130.
3. Adisso, S., Takpara, I., & HOUNGBE, F. (2006). Facteurs étiologiques des péritonites en milieu gynéco-obstétrical au CNHU de Cotonou: *Fondation Genevoise pour la Formation et la Recherche Médicales*, 1(2), 3-6.
4. Fenomanana, M. S., & Rakoto, A. T. (2009). Profil épidémiologique et thérapeutique des pelvipéritonites post abortives à la maternité du CHU d'Antananarivo Madagascar, *Revue d'Anesthésie-Réanimation et de Médecine d'Urgence*, 1(2), 17- 20.
5. Cisse, C. T., Faye, E. O., Cisse, M. L., Kouedou, D., & Diadhiou, F. (1999). Perforation utérine après avortement provoqué. *Médecine tropicale*, 59(4), 371-374.
6. Massamba, M. D., Mbongo, J. A., & Note, M. M. (2019). Péritonite génitale aigue à Brazzaville, Congo. *Science chirurgicale*, 10(1), 368- 376
7. Foumane, P., Mboudou, E. T., Djiadeu, B., Moifo, B., Dohbit, J. S., & Minkande, J. Z. (2013). Facteurs prédisposant au traitement chirurgical dans la prise en charge de la pelvipéritonite à Yaoundé,

Cameroun. *HEALTH SCIENCES AND DISEASE*, 14(2).

8. Diop, B., Konaté, I., Ba, P. A., Dieng, M., Wane, Y., & Sarré, S. M. (2017). Prise en charge de la pelvipéritonite en milieu chirurgical à Dakar: à propos de 62 observations. *Health sci. dis*, 78-91.
9. CUENOD, CA, Wind, P., Siauve, N., Clément, O., Bénichou, J., & Frija, G. (1999). Diagnosis of acute abdominal emergencies of digestive origin in adults: Contribution of imaging. *Clinical and biological gastroenterology*, 23 (11), 1170-1186.
10. Engbang, J. P., Essola, B., & Koando, R. M. (2021). Diagnostic et traitement de la péritonite aiguë à Douala (Cameroun), *Journal de chirurgie et de recherche*, 4(2), 287-95.
11. Harioly, N. M. O. J., Rosolonjatovo, T. Y., & Rakotoarivony, S. T. (2009). Pelvipéritonites post abortives: Aspect thérapeutique et devenir des patients, *Révue d'anesthésie- réanimation et de médecine d'urgence*, 1(3), 1-3
12. Léone, M., Fabre, G., & Mokthari, M. (1999). Les infections polymicrobiennes, In SFAR ed. Conférences d'actualisation. 41^{ème} Congrès national d'anesthésie et de réanimation. Elsevier, Paris, 6(4), 55-58
13. Adenuga, A. T., & Akande, O. W. (2020). Péritonite suite à un avortement a risque. Etude rétrospective dans un établissement de santé tertiaire du centre-nord du Nigeria *Revue médicale panafricaine*, 37(354), 10-11
14. Akila, B., Ayoko, k., Dede, A., & Baguilane, D. (2018). Péritonite et pelvipéritonite clandestin reçu à l'hôpital Sylvanus Olympio Teaching de Lomé, *Les Annales internationales de médecine*, 2(10), 643- 646.
15. Ka, I., Diop, P. S., Niang, A. B., Faye, A., Ndoye, J. M., & Fall, B. (2016). Péritonite aigue généralisée par perforation utérine post abortum à propos d'une observation. *The Pan African Medical Journal*, 24.