

Strangulated Mechanical Colonic Occlusion in Adults, Revealing a Diaphragmatic Hernia: A Case Report

Oumaima Cherif Zaitouni¹, Ali Benamara^{1*}, Houria Tabakh¹, Abdellatif Siwane¹, Najwa Touil¹, Omar Kacimi¹

¹Emergency Radiology Department, University Hospital Center Ibn Rochd, Casablanca, Morocco, Faculty of Medicine and Pharmacy, Hassan II University, Casablanca, Morocco

DOI: <https://doi.org/10.36347/sajs.2025.v11i01.012>

| Received: 17.06.2024 | Accepted: 22.07.2024 | Published: 20.01.2025

*Corresponding author: Ali Benamara

Emergency Radiology Department, University Hospital Center Ibn Rochd, Casablanca, Morocco, Faculty of Medicine and Pharmacy, Hassan II University, Casablanca, Morocco

Abstract

Case Report

Diaphragmatic hernia is a rare cause of intestinal obstruction in children and very rarely in adults. We report the case of a 45-year-old patient, with no medical or surgical history, who presented to our structure with an occlusive syndrome involving cessation of bowel movements and gas for 7 days. An unprepared abdomen revealed colonic and bowel hydroseric levels, as well as an aeriform image in the left basithoracic region. Diaphragmatic hernia remains a rare cause of mechanical occlusion. Computed tomography remains the examination of choice, for positive diagnosis and to search for eventual complications. Although rare, diaphragmatic hernia occlusion remains an entity to be aware of and investigated on imaging.

Keywords: Occlusion, Strangulated, Hernia.

Copyright © 2025 The Author(s): This is an open-access article distributed under the terms of the Creative Commons Attribution 4.0 International License (CC BY-NC 4.0) which permits unrestricted use, distribution, and reproduction in any medium for non-commercial use provided the original author and source are credited.

INTRODUCTION

Congenital diaphragmatic hernias in adults are most often discovered by chance during a chest X-ray, or during respiratory or digestive complications, such as intestinal obstruction. Congenital diaphragmatic defects can be of several types: right anterior (Morgani), left anterior (Larrey), or posterolateral (Bochdalek), the latter representing the most frequent of these entities [1]. We report the case of an adult with a left anterior diaphragmatic hernia revealed very late by the development of an occlusive syndrome.

CASE REPORT

A 45-year-old patient with no particular medical or surgical history presented with an occlusive syndrome consisting of cessation of feces and gas and vomiting for 7 days, with no associated externalized digestive hemorrhage and evolving in a context of apyrexia. Clinical examination revealed a distended abdomen and diffuse tympany. The paraclinical examination,

consisting of a frontal upright unprepared abdomen and an abdomino-pelvic CT scan, revealed diffuse colonic and small bowel hydroaeric levels with a left basithoracic hydroaeric image (figure 1), confirmed on chest X-ray (figure 2). An abdomino-pelvic CT scan, after injection of contrast medium, was carried out in the emergency setting (figures 3, 4 and 5), in sagittal, coronal and axial sections, and revealed a left anterior diaphragmatic defect (Larrey's hernia) with colonic and epiploic content, responsible for upstream colonic distension with parietal pneumatosis indicating intestinal distress, without intra-peritoneal effusion. Surgical exploration (fig. 6 and 7) revealed a large diaphragmatic defect, 3 cm long, with colonic content (transverse colon), and a strangulated epiploic defect, responsible for 9 cm of upstream colonic distension, at the caecal level, with no signs of distress or pre-perforation lesion, and 3 cm of caecal involvement. The surgical procedure consisted of colectomy with suture of the diaphragmatic defect and Valsalva maneuver. The patient died 4 days after the surgery.

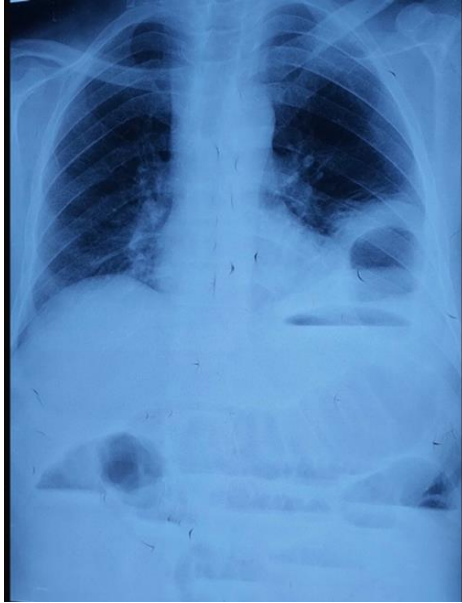


Figure 1

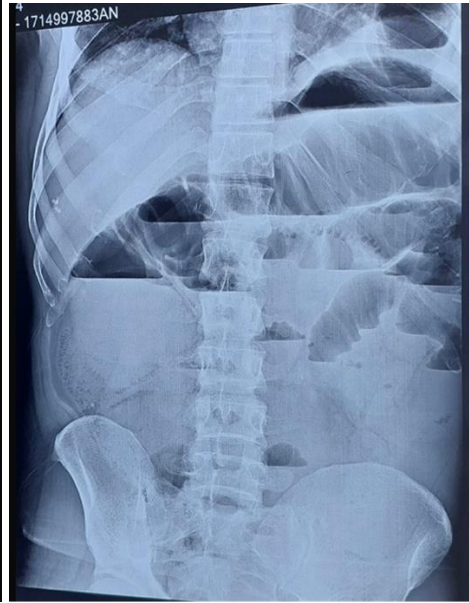

Figure 2

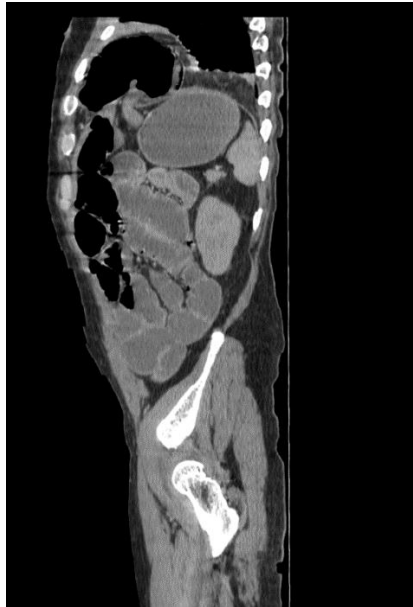

Figure 3

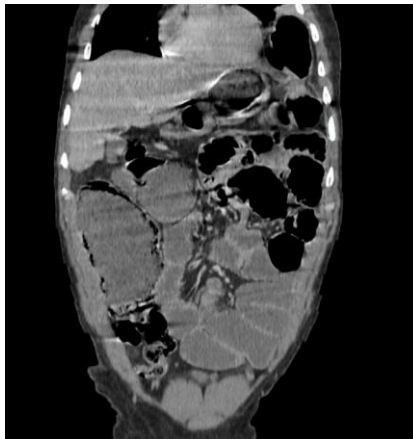

Figure 4

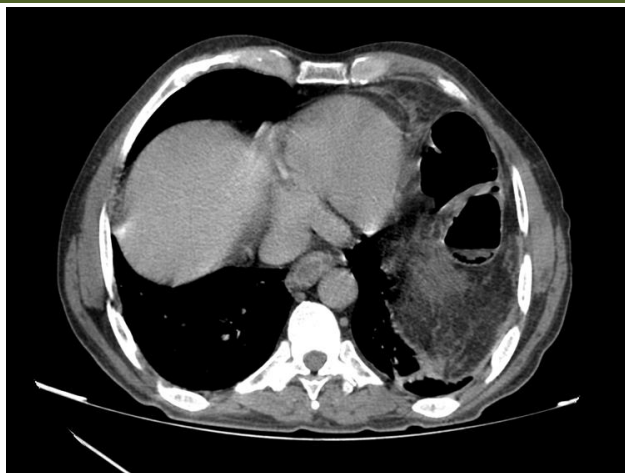


Figure 5

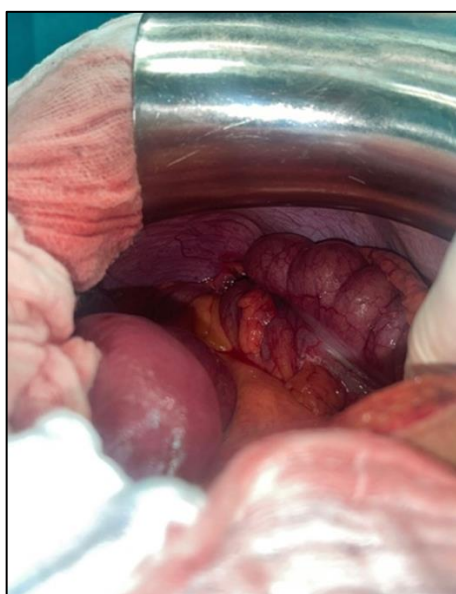


Figure 6

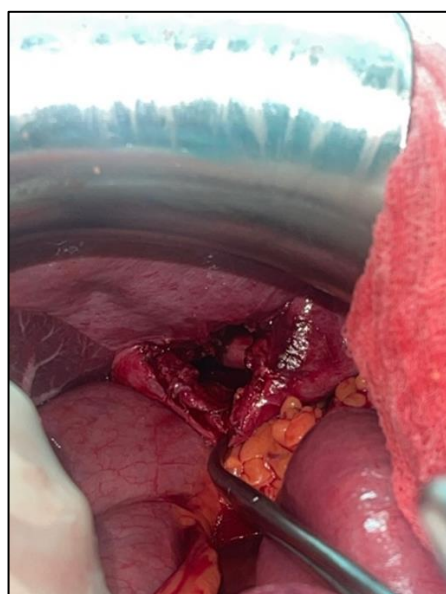

Figure 7

DISCUSSION

Congenital diaphragmatic hernia may present late in 10-30% of cases, posing a diagnostic problem [2]. In adults, diaphragmatic hernia may remain asymptomatic for a long time before causing mixed symptoms, both respiratory due to pulmonary compression and digestive due to visceral strangulation, as in our observation. Given the rarity of this condition in adults and the non-specificity of clinical symptoms, imaging, particularly CT scanning, remains the essential means of establishing an accurate diagnosis. On a chest X-ray, a diaphragmatic hernia may present as a heterogeneous image with opacities and clearness in the paracardiac or basithoracic region. The presence of an intra-thoracic gastric air sac in the case of gastric hernia, or the presence of basithoracic digestive tracts [3]. However, standard radiography has its limitations, particularly in view of the spontaneous reduction of the hernia, and large hernias may mimic a diaphragmatic ventration, leading to false negatives. Hydroaeric basithoracic images can simulate a variety of

pathologies, such as a lung, pleural or diaphragmatic tumour on a frontal X-ray, or a mediastinal tumour on a lateral X-ray.

In case of doubt, an oesogastroduodenal transit and a barium enema can help localize the herniated viscera and the hernia neck. In this context, computed tomography (CT) remains the most reliable examination for the detection and characterization of diaphragmatic hernias, allowing the precision of the hernial neck as well as its contents, which may be digestive and/or epiploic [4]. However, if not specifically sought, diaphragmatic hernia may escape detection on CT. Even during surgical exploration by laparotomy or laparoscopy, Larrey's hernia may go undetected if the surgeon is not alerted. The polymorphous and non-specific clinical symptoms, together with the limitations of chest radiography, explain why the diagnosis of a diaphragmatic hernia is often made in adults during acute complications, whether respiratory or digestive.

The most common digestive complications include strangulation of the stomach, small intestine or colon, manifesting as occlusive syndrome, as in our patient's case. More rarely, intestinal strangulation may result in hemorrhagic ulceration or ischemic or diastatic perforation.

Intestinal perforation can result in pyopneumothorax and septic shock, sometimes with sudden death. Exceptional cases have been observed, such as splenic infarction or rupture due to strangulation of the splenic pedicle. Because of the seriousness of these complications, diaphragmatic hernia should always be treated surgically, even when discovered incidentally in an asymptomatic patient. In cases of strangulated Larrey's hernia, treatment consists of reduction followed by closure of the diaphragmatic defect, and resection of non-viable segments in the event of ischemic complications. In the absence of digestive or pulmonary complications, video-thoracoscopy or laparoscopy may be considered. Thoracotomy, on the other hand, seems more appropriate in the event of respiratory complications or pyothorax, enabling reduction of the hernial contents, lavage of the pleural cavity and closure of the diaphragmatic breach [5].

CONCLUSION

Diaphragmatic hernia is a rare occurrence of intestinal obstruction in adults. It is crucial to suspect this

diagnosis in the presence of unexplained respiratory or digestive symptoms. Standard X-rays are not reliable enough to confirm the presence of the hernia or its strangulation. Consequently, the thoracoabdominal CT scan plays a crucial role, potentially revealing intestinal complications requiring emergency intervention.

REFERENCES

1. Najah, H., Bouriez, D., Bian, A. Z. Le., & Trésallet, C. (2024). Hernies abdominales. *Colloids Surfaces A Physicochem Eng Asp* [Internet]. 23(4), 1–8. Available from: [https://doi.org/10.1016/S1634-6939\(20\)90082-0](https://doi.org/10.1016/S1634-6939(20)90082-0)
2. Sakarya, M. T. (2001). Late Presentation of Bochdalek Hernia: Clinical and Radiological Aspects, 310, 306–10.
3. Iken, M., Mai, A., Choukrad, F., Haloua, M., Youssef, M. A. L., ... & Boubbou, M. (2019). Hernie de Bochdalek étranglée: cause rare d'occlusion intestinale chez l'adulte. *Pan Afr Med J*, 8688, 1–5.
4. Mph, E. A. G. (2024). Imaging of the Diaphragm A Primer MRI Computed tomography scan Fluoroscopy Ultrasound Diaphragm. *Thorac Surg Clin NA* [Internet]. 34(2), 119–25. Available from: <https://doi.org/10.1016/j.thorsurg.2024.02.002>
5. Facy, O., Cheynel, N., Deballon, P. O., & Rat, P. (2024). Traitement chirurgical des hernies diaphragmatiques rares (hors orifice hiatal). 1–6.