

Component Separation with Sublay (Retro Muscular) Polypropylene Mesh Implantation: Evaluation of Surgical Outcome of 30 Patients in a Tertiary Care Hospital

Dr. Masuda Joya^{1*}, Dr. Farhana Iftekhar², Prof. Dr. Sharmistha Roy³, Prof. Dr. Samiron Kumar Mondal⁴

¹Registrar, Department of Surgery, BIRDEM General Hospital & Ibrahim Medical College, Dhaka, Bangladesh

²Registrar, Department of Surgery, BIRDEM General Hospital & Ibrahim Medical College, Dhaka, Bangladesh

³Professor, Department of Surgery, BIRDE General Hospital & Ibrahim Medical College, Dhaka, Bangladesh

⁴Professor & Head, Department of Surgery, BIRDEM General Hospital & Ibrahim Medical College, Dhaka, Bangladesh

DOI: <https://doi.org/10.36347/sasjs.2025.v11i02.007>

| Received: 21.12.2024 | Accepted: 24.01.2025 | Published: 13.02.2025

*Corresponding author: Dr. Masuda Joya

Registrar, Department of Surgery, BIRDEM General Hospital & Ibrahim Medical College, Dhaka, Bangladesh

E-mail: dr.masudajoya@gmail.com

Abstract

Original Research Article

Background: Incisional hernia after laparotomy is a well-known complication and the repair has always been a challenge to the surgeons. Various operative techniques for the repair of incisional hernia are in practice among which the retro muscular mesh placement or the sublay technique popularized by Rives and Stoppa, has been reported to be quite effective, with low recurrence rates (0-23%) and minimal complications. The aim of this study was to report our experience about retro muscular repair with polypropylene mesh implantation for the treatment of midline incisional hernias. **Objective:** This study aimed to analyse the pros and cons of the sublay (retro muscular) mesh repair for midline incisional hernias and to evaluate the significance of this technique as a treatment modality. **Methods:** The study was conducted at the department of surgery BIRDEM general hospital over a period of four years (from December 2019 - November 2023). It was a prospective observational study using 30 cases. Early postoperative complications, postoperative pain (NPRS), drain removal time, postoperative hospital stay and the recurrence rate were the main areas of investigation. All the patients were followed up postoperatively up to 6 weeks for early complications and up to 2 years for recurrence. **Results:** In most of the cases the duration of operation was ≤ 120 minutes. Regarding postoperative findings, only 02 patients (6.66%) experienced severe pain after 96 hours where as 56.66% (17 patients) complained mild pain as per NPRS. Subcutaneous seroma was found only 6.66% cases. In most cases drain removal time was ≤ 4 days (76.66%) and postoperative hospital stay was also ≤ 4 days in 70% patients. None of our patients developed wound infection, mesh reaction or paralytic ileus as an early postoperative complication and none had developed recurrence up to 24 months follow up. The mean age, sex, BMI of the sample population, clinical presentations and per operative findings were comparable with other studies. **Conclusion:** In this study sublay mesh repair showed excellent short-term results, with minimal morbidity and 0% recurrence. So, it is a good alternative that may be applicable to all forms of incisional hernia.

Keywords: Component separation, sublay mesh repair technique, retro muscular mesh placement, mesh reaction.

Copyright © 2025 The Author(s): This is an open-access article distributed under the terms of the Creative Commons Attribution 4.0 International License (CC BY-NC 4.0) which permits unrestricted use, distribution, and reproduction in any medium for non-commercial use provided the original author and source are credited.

INTRODUCTION

Incisional hernia (IH) is a common late complication of laparotomy, with an estimated occurrence rate of 12.8% after approximately 2 years. Mesh repair seems to be more effective than suture repair in the treatment of IHs because the former leads to a lower recurrence rate [1]. The anterior abdominal wall anatomy is composed of skin and subcutaneous fat, followed by Scarpa's and Camper's fascia, while deep fascia is absent from that complex of tissues. Deeper layers include abdominal wall muscles, fascia

transversalis, preperitoneal fat, and peritoneum. Above the arcuate line (midpoint between the umbilicus and symphysis pubis), the internal oblique aponeurosis envelops the rectus muscle. The external oblique aponeurosis always sits anterior, while the transversus abdominis lies posteriorly. Below the arcuate line, all muscles become anterior to the rectus abdominis. The two-sided rectus sheath fuses at the midline to form the linea alba and laterally to form the linea semilunaris [2]. This clear anatomical knowledge is very essential for hernia surgery. Long-standing increased intraabdominal pressure (e.g., strain, constipation, chronic cough)

Citation: Masuda Joya, Farhana Iftekhar, Sharmistha Roy, Samiron Kumar Mondal. Component Separation with Sublay (Retro Muscular) Polypropylene Mesh Implantation: Evaluation of Surgical Outcome of 30 Patients in a Tertiary Care H. SAS J Surg, 2025 Feb 11(2): 145-152.

weakens the local tissues and leads to microscopic tears, predisposing to hernia formation. Post abdominal surgeries, the tissue strength can only regain 80% of its maximum tensile power. This 80% predicted tensile strength is under perfect conditions, assuming no evidence of malnutrition or infectious complications. Thus, each abdominal surgery is a predisposing factor for incisional hernia [2]. As a result of high recurrence rate in the repair of incisional hernia, various types of repairs have been used, both anatomical and prosthetic. But the results have been disappointing with a high incidence of recurrence of about 30-50% after anatomical repair and 1.5-10% following prosthetic mesh repair [3]. So, comparing both methods, implantation of prosthetic mesh remains the most efficient method of dealing with incisional hernia. The prosthetic mesh can be placed between the subcutaneous tissues of the abdominal wall and the anterior rectus sheath (onlay mesh repair) as well as in the preperitoneal plane created between the rectus muscle and posterior rectus sheath (sublay mesh repair) [3]. The later technique has several advantages. First, this place is highly vascular, hence, it prevents infection. And if any infection occurs in the subcutaneous plane it will not affect the mesh, as the mesh is in a deeper plane. Second, the prosthesis in this plane cannot be dislodged. Third, the prosthesis adheres early to the posterior rectus sheath and renders it inextensible, permitting no further herniation. Finally, the retro muscular space is an already existing anatomical plane, requiring no dissection, and the bare posterior surface of the rectus muscles is rich in lymphatic capable to absorb any collecting seroma [4]. So, this technique is considered by many surgeons to be the gold standard for the open repair of the abdominal hernias [5]. This prospective observational single centre study aimed to evaluate the outcome of the sublay mesh repair for incisional hernias. The study analyzed the operative time, early postoperative complication (seroma formation, wound infection, mesh reaction, paralytic ileus), post-operative pain (NPRS), drain removal time, postoperative hospital stays and, finally, the recurrence rate.

MATERIALS AND METHOD

This study was carried out among 30 patients of midline incisional hernia (upper midline, lower midline and Pfannenstiel incisions) in BIRDEM General Hospital for a period of four years from December 2019 to November 2023. Sampling technique was Purposive sampling. Permission was taken from Director General BIRDEM hospital and Head of the Department of

surgery regarding collecting Data. All the patients were selected according to the inclusion criteria. Soft polypropylene mesh was used in all patients (mesh size depended upon the size of the defect). Patients were followed up postoperatively for 6 (six) weeks to assess early complications and up to 2 years for recurrence.

Inclusion criteria:

Patients of both genders having the following criteria are included in the study -

- All type of midline incisional hernias (upper midline, lower midline and pfannenstiel incisions) where defects measuring 3 -15 cm at maximum diameter.

Exclusion criteria:

- Incisional hernia - size \leq 2 cm.

Following groups of patients were excluded from the study as different degrees of their comorbidities may cause complications to the procedure -

- Patients with abdominal malignancy, Cirrhosis of liver.
- Patients presented as emergency like strangulated hernia with signs of obstruction (abdominal distention, vomiting and absolute constipation).
- Pre-existing skin infection at the site of hernia with local signs of inflammation.

Evaluations of the patients

All 30 patients were admitted from surgical OPD as an elective basis. Patients were subjected to preoperative assessment and postoperative follow-up. Outpatient clinical notes, previous discharge summary, operative notes, and laboratory data were reviewed. The patients were evaluated preoperatively with history, clinical examination, baseline investigation and radiological evaluation. History of patients included nature of comorbidity, nature of index surgery, wound events at index surgery and symptomatology. Clinical examination would determine the site, size of defect & contents. Each patient underwent the following evaluations: (1) Complete blood count, (2) Liver function tests, (3) Fasting and postprandial blood glucose, (4) Kidney function, (5) Radiological evaluation of the abdomen by - (a) Abdominal ultrasound (b) CT Scan of abdomen (in most of the cases to characterise the defect, classify and determine loss of domain and (6) ECG and (7) Echocardiogram (where necessary).

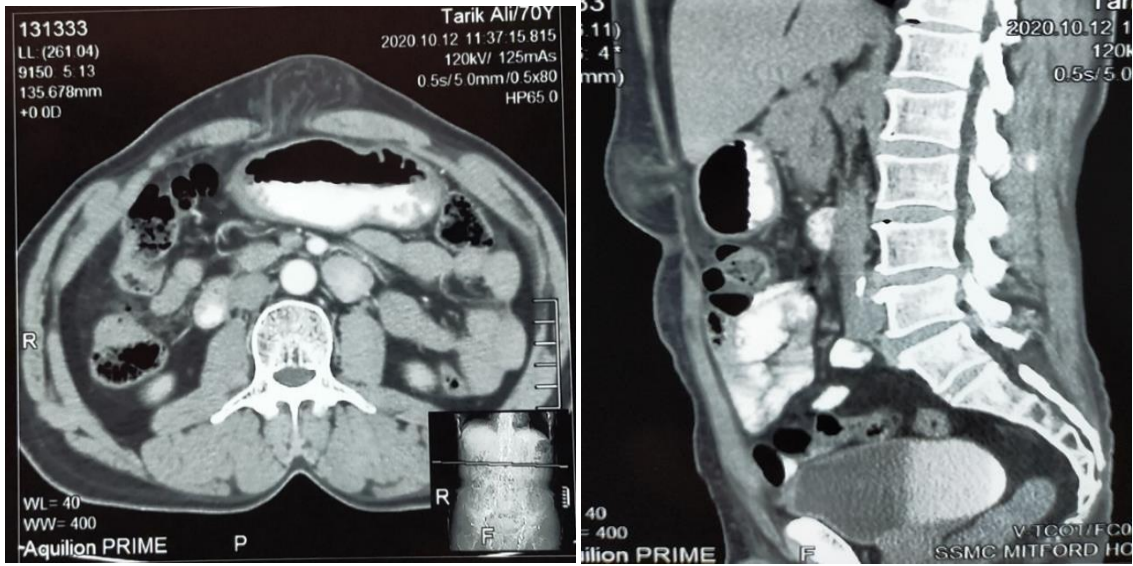


Figure 1A: CT scan showing hernia through upper midline incision containing omentum

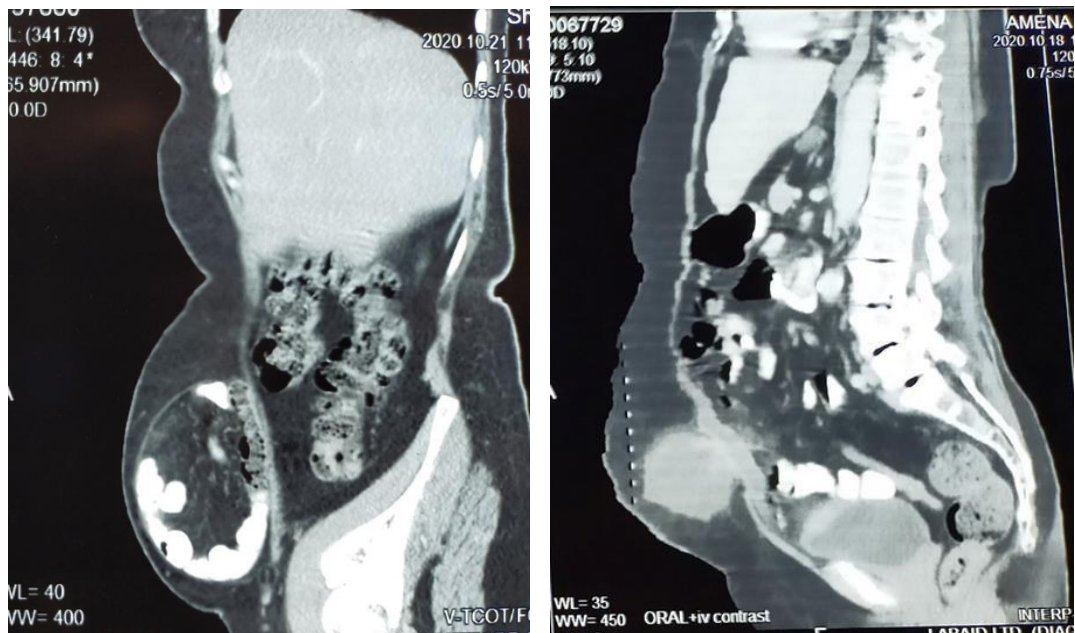


Figure 1B: CT scan showing hernia through lower midline incision containing omentum and intestine

Nutritional embarrassments and attempts were made to rectify the same preoperatively like blood transfusion, serum albumin, BMI. Cessation of smoking for at least 4 weeks before surgery and weight reduction before surgery was ensured. On the day of surgery, preoperatively the patients were prepared with local part preparation, single shot of tetanus toxoid and 3rd generation cephalosporin.

Operative methods

The operations were performed under general anaesthesia and by a single surgeon. In all cases the old scar was excised, and the hernia sac and defect were exposed adequately. The sac was opened and the content

was reduced after lysis of the adhesions. The excess sac was excised. In sublay repair, the preperitoneal, retro muscular space was dissected about 5–6 cm beyond the edge of the defect where the mesh was positioned and fixed by 2/0 polypropylene sutures after closer of the defect by delayed absorbable suture material. Suction drains were laid on the mesh and brought out through a separate stab. The muscular aponeurotic structures were repaired with prolene no. 1, followed by skin closure. In all patients a soft polypropylene mesh was used. Suction drain was removed when drainage was less than 20 cm with no infection. No major per operative bleeding occurred in any patient and there was no incidence of perioperative mortality.

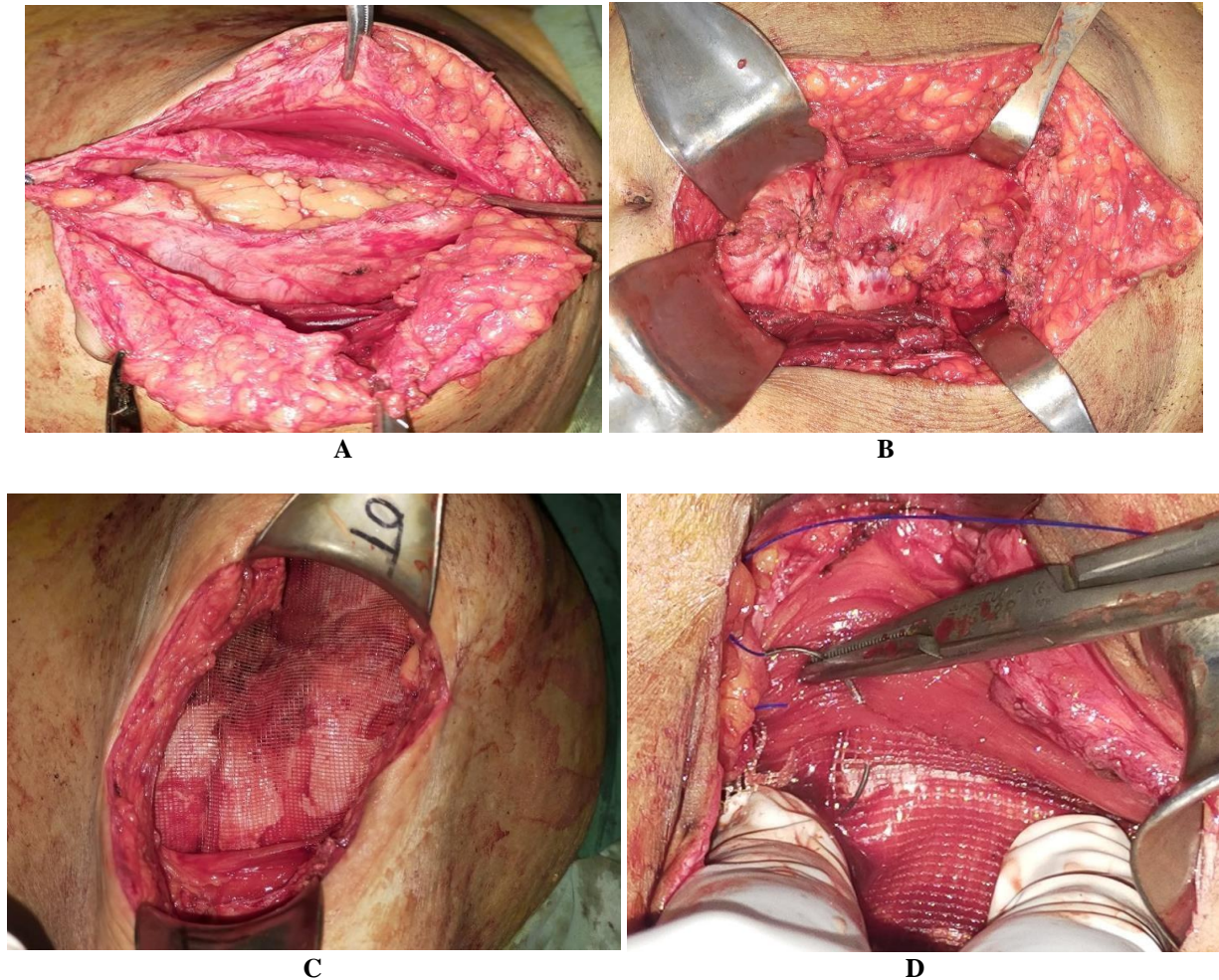


Figure 2: (a) Separated layers of anterior abdominal wall. (b) Repair of posterior rectus sheath. (c) Placement of mesh beneath the posterior rectus sheath and rectus abdominis muscle. (d) fixation of the mesh with posterior rectus sheath

Post-operative management

All patients received inj. Pethidine as an analgesic up to first postoperative day and inj. Ketorolac 30 mg on second and tab. Ketorolac on subsequent postoperative days. Antibiotics were given up to the tenth day. Deep breathing exercises and limbs movements in bed were advised once the patient had recovered from anaesthesia. The patients were encouraged for early gradual ambulation. Skin sutures were removed usually on the 10th day and in a few cases after the 10th day. At the time of discharge, patients were advised to avoid carrying heavy weights and to wear an abdominal belt.

Post-operative outcome assessment

Each patient was assessed before discharge for early postoperative complications such as postoperative fever, pain, subcutaneous seroma, wound infection, ileus, and urinary retention. Thereafter, all patients were followed up at 2 weeks and 6 weeks. Six monthly follow up was continued up to 2 years to assess any recurrence. The results were tabulated and analysed.

RESULTS

Table I: Distribution of the patients according to demographic findings (N=30)

Demographic variable	Frequency (n)	Percentage (%)
Age		
≤60 years	24	80
>60 years	06	20
Sex		
Male	09	30
Female	21	70
BMI		

Demographic variable	Frequency (n)	Percentage (%)
Normal	07	23.3
Overweight	19	63.3
Obese	04	13.3
Physical activity status		
Sedentary worker	09	30
Moderately heavy worker	18	60
Heavy worker	03	10
Smoking habit	03	33.3
Parity (Females only)		
≤ 2	03	14
>2	18	86

Table I shows, in our study most of the patients (80%) were below 60 years with a female to male ratio of 2.3:1.63.3% patients were overweight and 60% were

moderately heavy worker. Smoking habit was evident in 33.3% patients (mostly male). About 86% females had more than 2 children.

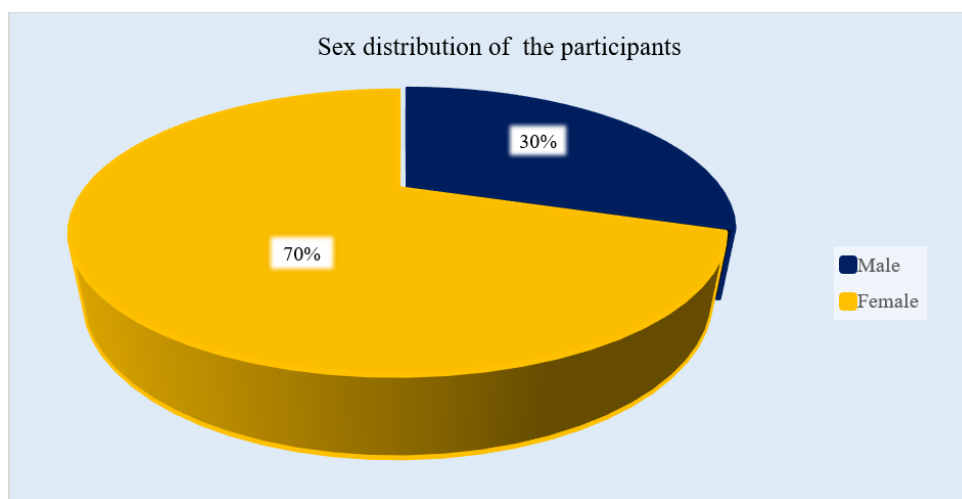


Figure 3: Pie chart showed gender wise patients distribution (N=30)

Table II: Distribution of the patients according to history & examination findings (N=30)

Variable	Frequency (n)	Percentage (%)
Duration of swelling (in months)		
≤24	17	57
>24	13	43
Complication after index surgery		
Wound infection	06	20
Cough	01	03
Constipation	13	43
Urinary symptom	03	10
Defect size (maximum diameter in cm)		
≤10	19	63
>10	11	33
Site of incisional hernia		
Upper midline	08	27
Lower midline	15	50
Pfannenstiel	07	23

In table II regarding history and examination findings, 57% patients had the history of abdominal swelling for less than 24 months where as 43% has the same complain for more than 24 months. Most of them

had developed constipation after index surgery. Defect size was ≤10 cm in 63% patients and >10 cm in 33% patients (ranging from 3 to 15 cm at maximum diameter).

Table III: Distribution of the patients according to per operative findings (N=30)

Variable	Frequency (n)	Percentage (%)
Duration of operation (minutes)		
≤120	19	63.33
>120	11	37
Excessive bleeding during operation	00	00
Difficulties during dissection	06	20

Table III shows, in 63.33% patients time required for surgery was not more than 120 minutes. But in 37% patients it required more than 120 minutes. There

was no history of excessive bleeding during operations but difficulties were faced during dissection in six cases (20%).

Table IV: Distribution of the patients according to postoperative outcome (N=30)

Variable	Frequency (n)	Percentage (%)
Post-operative pain after 96 hours (as per NPRS)		
0 (no pain)	05	16.66
1-3 (Mild pain)	17	56.66
4-6 (moderate pain)	06	20.0
7-10 (severe pain)	02	6.66
Subcutaneous seroma formation	02	6.66
Wound infection	00	00
Mesh reaction	00	00
Paralytic ileus	00	00
Drain removal time (days)		
≤4	23	76.66
>4	07	23.33
Post-operative hospital stays(days)		
≤4	21	70
>4	09	30
Recurrence (up to 24 months)	00	00

Regarding postoperative findings, only 02 patients (6.66%) experienced severe pain after 96 hours where as 56.66% (17 patients) complained mild pain as per NPRS. Subcutaneous seroma was found only 6.66% cases. In most cases drain removal time was ≤4 days

(76.66%) and postoperative hospital stay was also ≤4 days in 70% patients. None of our patients developed wound infection, mesh reaction or paralytic ileus as an early postoperative complication and none had developed recurrence up to 24 months follow up.

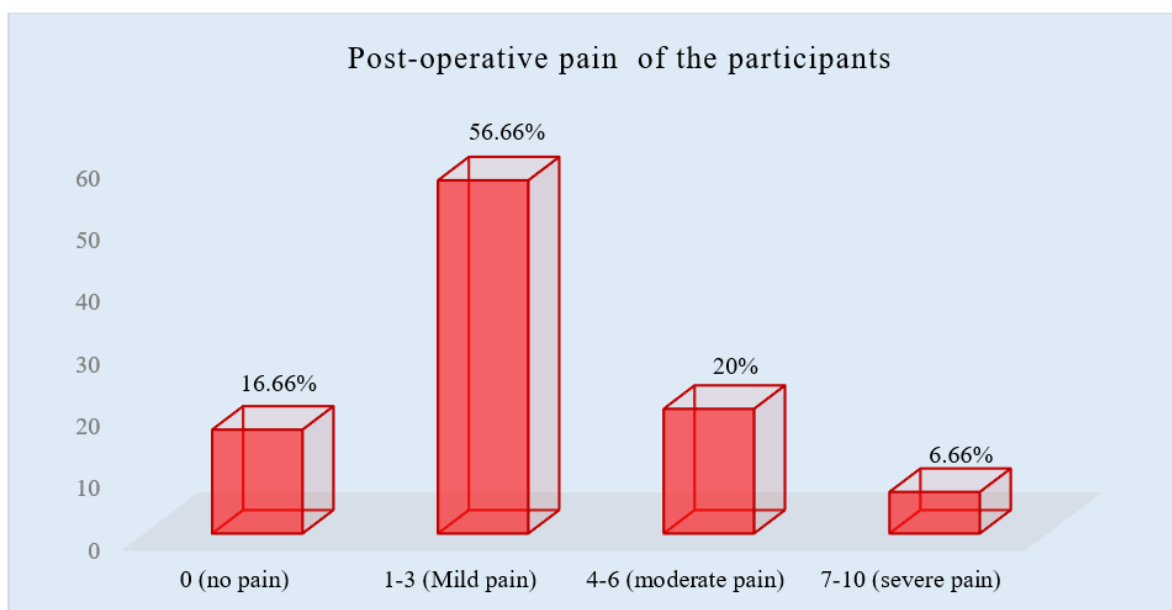


Figure 4: Column chart showed post-operative pain after 96 hours (N=30)

DISCUSSION

Incisional hernia repair is one of the challenging surgical operations over time. Mesh repair methods are generally considered safe and effective procedures to correct hernias [6]. Several surgical techniques for mesh repair have been described (onlay, inlay, sublay, and underlay). It is suggested that sublay mesh repair has the lowest recurrence and surgical site infection in open anterior abdominal wall hernia repair techniques. Prosthetic mesh can be used for reinforcement of the fascia and this reduces recurrence rate associated with CST alone. In same article it is stated that component separation being rectus abdominis advancement flap is a valuable, functional abdominal wall reconstructing technique with good aesthetic results. Another benefit of component separation technique is that multiple defects can be detected and repaired by its use as missing defect can lead to recurrence [7]. But unfortunately, limited local data was available to establish the acceptance of component separation with sublay (retro muscular) mesh repair regarding complications. Therefore, we designed and conducted this study to evaluate the outcome of sublay (retro muscular) mesh repair in terms of early postoperative complications and recurrence among patients undergoing hernioplasty by this method. In our study, regarding age most of the patients (80%) were below 60 years (5th to 6th decade) which is similar with other studies [4, 8-10]. Female to male ratio of 2.3:1. In another study it was found 4:1, which is consistent with our result [9,11]. The high female preponderance can be attributed to the majority of index operations being Gynaecological operations with a Pfannenstiel or lower midline incisions and thin rectus sheath, which result in incisional hernia. 63.3% patients were overweight and 60% were moderately heavy worker. Almost similar result was shown in a study published by Mushtaq U. *et al.*, 2019 which shows a correlation of increased BMI with development of incisional hernia [8]. Postoperative deposition of abdominal fat may also lead to hernia development due to decrease in muscle strength. Smoking habit was evident in 33.3% patients (mostly male). About 86% females had more than 2 children. Regarding history and examination findings, 57% patients had the history of abdominal swelling for less than 24 months where as 43% has the same complain for more than 24 months. but in similar type of another study in association with swelling some patients also have the complaints of dragging pain in the swelling which is consistent with other studies [9]. Most of them (43%) had developed constipation after index surgery. Long-standing increased intraabdominal pressure (e.g., strain, constipation, chronic cough) weakens the local tissues and leads to microscopic tears, predisposing to hernia formation. Post abdominal surgeries, the tissue strength can only regain 80% of its maximum tensile power. This 80% predicted tensile strength is under perfect conditions, assuming no evidence of malnutrition or infectious complications. Thus, each abdominal surgery is a predisposing factor for incisional hernia [2]. Defect size was ≤ 10 cm in 63% patients and >10 cm in 33%

patients (ranging from 3 to 15 cm at maximum diameter). In 63.33% patients the in this study time taken to complete the surgery from incision to skin closer through dissection of layers of abdomen, placement of mesh and its fixation and placement of a vacuum drain was not more than 120 minutes. But in 37% patients it required more than 120 minutes. A comparative study by Nagaraja. A.L. *et al.*, noted that mean duration of operation in sublay group (63.15 ± 15 min) is more than onlay group (49.35 ± 8.29 min) with insignificant p value [12]. This time requirement may vary with expertise of the surgeon as well as the quality of dissection plane. In our study There was no history of excessive bleeding during operations but difficulties were faced during dissection in six cases (20%). Regarding postoperative findings, only 02 patients (6.66%) experienced severe pain after 96 hours where as 56.66% (17 patients) complained mild pain as per NPRS. In other comparative and observational studies pain was also found significantly low in sublay (retro muscular) group [13]. Subcutaneous seroma was found only 6.66% cases. Chances of seroma formation was less with this procedure as there was less dead space, little fat and high lymphatics which decreases the incidence of seroma formation [3]. In most cases drain removal time was ≤ 4 days (76.66%) and postoperative hospital stay was also ≤ 4 days in 70% patients. Postoperative hospital stay was also found relatively less regarding retro muscular repair in other studies [14]. None of our patients developed wound infection, mesh reaction or paralytic ileus as an early postoperative complication. This is possibly because the surgeries were performed by the expert hands of a senior surgeon, adequate pre-operative preparation of the patients, preparation of the operative site and meticulous postoperative care. Significant difference was found here with other studies [3,7,15-18]. Our study shows 0% recurrence rate up to 24 months follow up which is comparable with the study by Alobaidi *et al.*, and Hameed *et al.*, [19] So, placement of the mesh in the retro muscular plane seems to be a reasonable alternative. First, this plane is highly vascular, hence, it prevents infection, and if any infection occurs in the subcutaneous plane, it will not affect the mesh, as the mesh is in a deeper plane. Second, the prosthesis in this plane cannot be dislodged or ruptured by intra-abdominal pressure, but instead is held in place by the same force that caused the hernia. Third, the prosthesis adheres early to the posterior rectus sheath and renders it inextensible, permitting no further herniation. Finally, the retro muscular space is an already existing anatomical plane, requiring no dissection, and the bare posterior surface of the of the rectus muscles is rich in lymphatics capable to absorb any collecting seroma [17].

CONCLUSION

Retro rectus mesh repair for adults is a very safe and effective way for treating incisional hernias. Placement of mesh in different positions or layers of abdominal wall yield different results. Our study aimed at determining the component separation along with

sublay (retro muscular) placement of mesh as an acceptable technique with minimal morbidity and maximum benefit in terms of early post-operative outcome as well as recurrence of hernia, depending on which this procedure can be considered as a good alternative for the treatment of all forms of incisional hernia.

LIMITATIONS

Although optimum care has been taken in every step of this study, still some limitations existed: This is a single center study, so the study population might not represent the whole community. The study's duration and the size of the sample may limit the generalizability of the findings.

RECOMMENDATIONS

Future research should focus on longer-term follow-up and larger patient cohorts to validate these results.

REFERENCE

- Schembari, E., Sofia, M., Lombardo, R., Randazzo, V., Coco, O., Mattone, E., ... & Latteri, S. (2020). Is the sublay self-gripping mesh effective for incisional ventral hernia repair? Our experience and a systematic review of the literature. *Updates in surgery*, 72, 1195-1200.
- Issa, M., Noureldin, K., Elgadi, A., Abdelaziz, A., Badawi, M., & Makram, M. (2021). Evaluation of the sublay mesh repair outcomes in different types of ventral hernia. *Cureus*, 13(12).
- Hameed, F., Ahmed, B., Ahmed, A., & Dab, R. H. (2009). Incisional hernia repair by preperitoneal (sublay) mesh implantation. *Annals of Punjab Medical College*, 3(1), 27-31.
- Dhaigude, B. D., Sugunan, A., Panbhai, S. V., Francis, M., Patel, K., & Metta, V. (2018). Comparative evaluation of sublay versus onlay meshplasty in incisional and ventral hernias. *International Surgery Journal*, 5(1), 187-192.
- Al-Tai, A. H. (2019). Evaluation of "sublay" versus "onlay" mesh hernioplasty in ventral hernial repair. *Journal of Pharmaceutical Sciences and Research*, 11(4), 1313-1318.
- Khawaja, F. G., Mahmood, K., Gul, U. J., Aslam, A., Saeed, F., & Nayyar, A. (2023). Comparison of sublay and onlay mesh repair in terms of post-operative complications. *Pakistan Armed Forces Medical Journal*, 73(3), 686-89.
- Rashid, S. (2021). Anterior component separation with sublay polypropylene mesh placement: An ideal way to deal with large ventral abdominal hernias. *The Professional Medical Journal*, 28(05), 731-736.
- Mushtaq, U., Gilkar, I. A., Peer, J. A., Jeelani, S., Aziz, A., Nowreen, F., ... & Peer, D. (2019). Open Underlay Mesh Reinforced Large Incisional Hernia Repair—Prospective Observational Hospital Based Study. *Surgical Science*, 10(3), 94-105.
- Lee, T. H. J., Ulisney, K. L., Choudhuri, A. K., Swiger, J. L., & Gibeily, G. J. (2019). Understanding the patient perspective after ventral hernia repair. *Hernia*, 23, 995-1001.
- Baracs, J., Sajjadi, G. S., Kelemen, D., Horvath, O. P., Vereczkei, A., & Vereczkei, A. (2016). Open treatment of abdominal wall hernias: mesh repair is superior to suture repair and onlay mesh is better than sublay mesh-five-year multicentric, prospective, randomised clinical trial. *Surgery Curr Res*, 6(270), 2161-76.
- Naz,A., Abid,K., Sayed,AA., Baig,NN., Umer,F.M. Mehdi,H., et al. J Pak Med Assoc.2018, Vol.68, No.
- Manimegalai, Avvait, et al. (2019). A comparative study between onlay and subway mesh repair in the treatment of ventral hernia, *Iaim journal*, 6(3), 217-222.
- Babar, Y., Shah, M., & Ullah, R. (2024). Comparison of Efficacy and Safety in Sublay versus Onlay Mesh Repair for Para-Umbilical Hernia: A Randomized Controlled Trial. *Journal of Health and Rehabilitation Research*, 4(1), 19-22.
- Ali, I. M., Shetty, S., & Shetty, V. (2024). A Clinical Study of Anterior Abdominal Wall Hernias and Its Management: A Medical College Experience. *Cureus*, 16(8), e67209.
- Shah, D. K., Patel, S. J., Chaudhary, S. R., & Desai, N. R. (2023). Comparative study of onlay versus sublay mesh repair in the management of ventral hernias. *Updates in Surgery*, 75(7), 1991-1996.
- Köckerling, F., Lammers, B., Weyhe, D., Reinhold, W., Zarras, K., Adolf, D., ... & Krüger, C. M. (2021). What is the outcome of the open IPOM versus sublay technique in the treatment of larger incisional hernias?: A propensity score-matched comparison of 9091 patients from the Herniated Registry. *Hernia*, 25, 23-31.
- Nagaraja, A.L., Raj, P., Surendran. (2019). A Comparative Study of Onlay Vs Sublay Mesh Repair In Incisional Hernias, *Journal cmpr*, 4(5), 3300-3302.
- Ahmed, M., & Mehboob, M. (2019). Comparisons of onlay versus sublay mesh fixation technique in ventral abdominal wall incisional hernia repair. *J Coll Physicians Surg Pak*, 29(9), 819-822.
- Alobaidi, M. H., & Alammar, N. R. (2019). Comparative Study between the "sublay" versus "onlay" techniques of mesh hernioplasty in Ventral hernias. *Int J Adv Res Biol Sci*, 6(4), 127-138.