

## Laparoscopic Appendectomy: Prospective Study

Haissoune Ahmed<sup>1\*</sup>, Tirizite Nabil<sup>1</sup>, Ahchari Kawtar<sup>1</sup>, Tamour Hicham<sup>1</sup>, Habbab Adil<sup>1</sup>, Hamri Asma<sup>1</sup>, Natjis Youssef<sup>1</sup>, Benelkhaïat Benomar Ridouan<sup>1</sup>

<sup>1</sup>Department of Surgery, Faculty of Medicine and Pharmacy, Ibn Tofail Hospital, Mohamed VI University Hospital, Cadi Ayad University, Marrakech 40000, Morocco

DOI: <https://doi.org/10.36347/sasjs.2025.v11i02.016>

| Received: 26.12.2024 | Accepted: 03.02.2025 | Published: 20.02.2025

\*Corresponding author: Haissoune Ahmed

Department of Surgery, Faculty of Medicine and Pharmacy, Ibn Tofail Hospital, Mohamed VI University Hospital, Cadi Ayad University, Marrakech 40000, Morocco

### Abstract

### Original Research Article

Appendectomy is the chosen treatment for patients with acute appendicitis and laparoscopic approach for these cases is an option to have in mind. The main purpose of this paper is to analyze the clinical aspects, describe surgical technique, its advantages, surgery results and the evolution during and after the operation in 73 cases of laparoscopic appendectomy. All the patients with diagnosed appendicitis were submitted to laparoscopic appendectomy on Beneficen in Ibn Tofail Hospital, between April 2020 and April 2023, using a specific protocol. There was a predominance in young adults, sex ratio was 1,35, having a classic clinical finding of acute appendicitis in 73% of the cases, high leucocytosis in 84% and by anatomic pré-ileal site of vermiform appendix in 75%. The appendectomy realised with full laparoscopy "IN" required three ports (Fig 1), to secure the appendix base, the appendix was doubly ligated after a good appendix meso dissection by electrocautery. The specimen is removed without endobag through camera port, thereby saving the cost of endostapler and an endobag. Our technique was Low-Cost Technique. The mean time taken by the operation was 40 minutes with a conversion rate of 0%. In hospital period was 48 hours with 5 days to return to normal activities. The laparoscopic appendectomy is nowadays the technique of choice for the treatment of acute appendicitis.

**Keywords:** Appendicitis, appendectomy, videosurgery.

Copyright © 2025 The Author(s): This is an open-access article distributed under the terms of the Creative Commons Attribution 4.0 International License (CC BY-NC 4.0) which permits unrestricted use, distribution, and reproduction in any medium for non-commercial use provided the original author and source are credited.

## 1. BACKGROUND

Acute appendicitis (AA) is the most frequent cause of acute abdominal pain [1]. Appendectomy has been the treatment of choice for AA since it was described by McBurney in 1894. Semm described the laparoscopic approach for treating AA over 20 years ago [2]. The peak incidence of acute appendicitis is between 10 and 30 years of age; if left untreated, acute appendicitis may lead to complications, leading to inflammatory mass, appendix abscess, or rupture, with generalized peritonitis. The diagnosis of acute appendicitis is mainly clinical and presentation of acute appendicitis may be typical or atypical.

## 2. METHODS

This was a prospective observational study of patients over 15 years old (as 15 years is a lower age cut-off for admission), diagnosed less than 48 hours and treated by laparoscopy technique for acute appendicitis at Ibn Tofail Hospital, Department of General Surgery from April 1st 2020 to April 1st 2023. Patients files were reviewed on admission and after discharge. Data

retrieved included patients demographics, clinical presentation, duration of symptoms before presentation to the hospital, results of diagnostic investigations, laparoscopic surgery advantages and evidence of complicated disease at presentation, length of hospital stay and mortality rate.

## 3. OUTCOMES

A total of 73 patients were diagnosed with acute appendicitis. The male to female ratio was 1.35 and their mean age was 35 years. The duration of symptoms was 36 hours and 39% of the patients presented more than two days after the onset of symptoms. Overall, the complicated appendicitis rate was 7%. Common presenting symptoms were right iliac fossa (RIF) pain (73%), vomiting and nausea (48%), fever (85%) and late mensturation in two case, physical examination RIF defense (68,5%).

The following investigations were undertaken: high whitecell count (WCC) in 84%, positive C-reactive protein (CRP) in 49% (performed in 43 patients),

BetaHCG test negative was performed in two case, abdominal ultrasound in 100%, CT scan in 4 cases.

The majority of our patients were operated on soon after admission by laparoscopic technique. After conditioning of the associated morbidity (diabetes equilibration, analgesic, antibiotic). Operating room step up and patient positioning are important for a successful outcome of surgery: Dorsal decubitus, legs are in extension position, the right arm alongside the body, a slight roll to the left, laparoscopy column was at the patient right in front of the surgeon (first aid on the right, second one on the surgeon's left), gas pressure (10-12mmgh) and the surgery was made under general anesthesia. Surgical

Exploration: preileal (75%), retrocecal (13%), postileal (8%), and pelvic (4%); uncomplicated appendicitis (90,3%), complicated appendicitis (abscess 5,6%, peritonitis 4.1%).

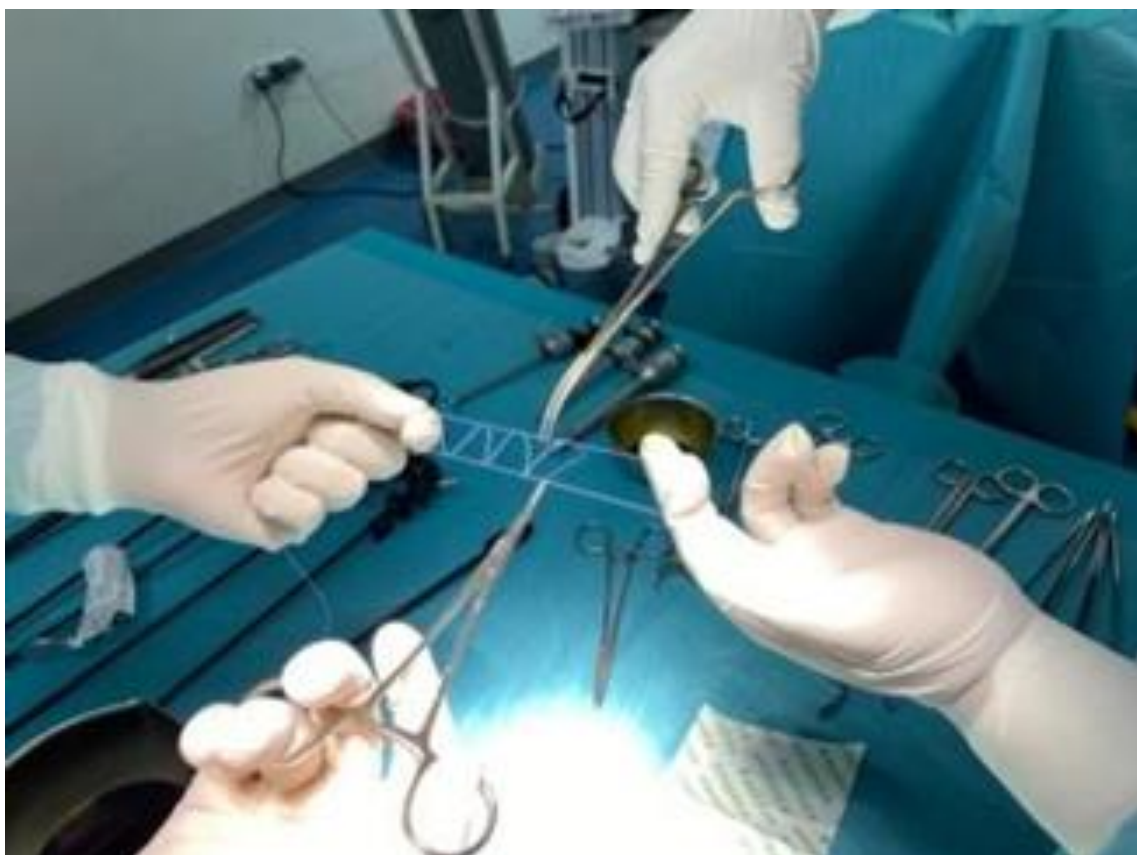
The medium timing of surgery was 40minutes, realised with full laparoscopy "IN" which required three ports in the form of a triangle (10mm umbilical trocar, 5mm left hypocondrium, , the last one 5mm, 2cm above the anteriosuperior iliac spine) (Fig 2), to secure the appendix base, the appendix was doubly ligated (pursestring suture, prepared before surgery (Fig 1)),

after the appendix identification, we proceeded with a good appendix meso dissection by electrocautery monopolar (appendicular mesentery not bulky, easy to extract through the trocar after appendicular section) (Figs 3-5). The appendix base was doubly ligated (Fig 6), and the appendix section was done by scissors (Fig 7). The alignment of camera trocar must be done with the forceps taking the appendix trocar (2cm above the anteriosuperior iliac spine) to guide the under visual control for a sure extraction (Fig. 8). The specimen is removed without endobag through camera trocar (Figs 9 and 10).

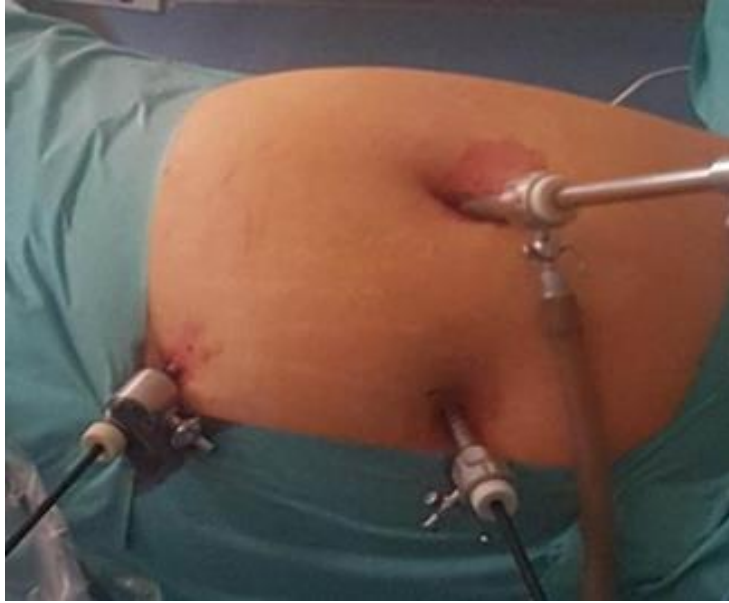The appdicular stump, peritoneal lavage and systematic drainage follow the lap appendicectomy (Figs 11 and 12), thereby saving the cost of endostapler and an endobag. Our technique was a Low Cost Technique.

Histology results showed perforated appendix in 6 patients (7%) and not perforated appendix in 93% of cases (catarrhalis, ulcerative, phlegmonosa), without sign of malignancy or specificity.

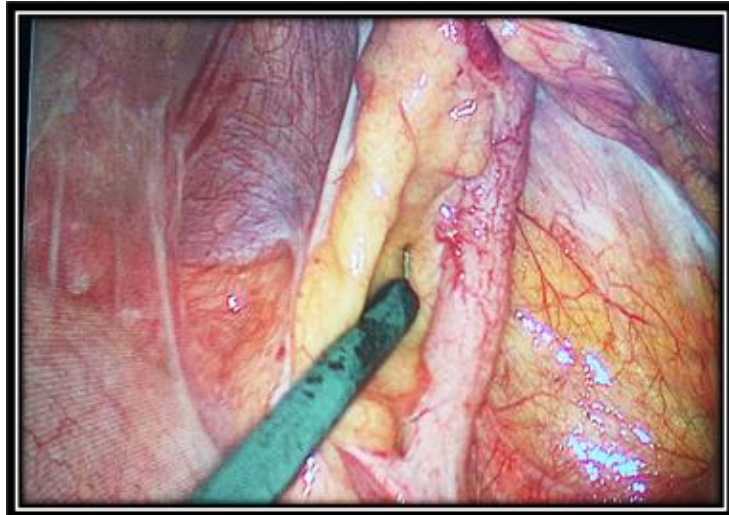
Post operatively, the patients were systematically put on antibiotics and analgesics. The mortality rate was 0%. The average length to stay was 48 hours. The follow up was without particularity.



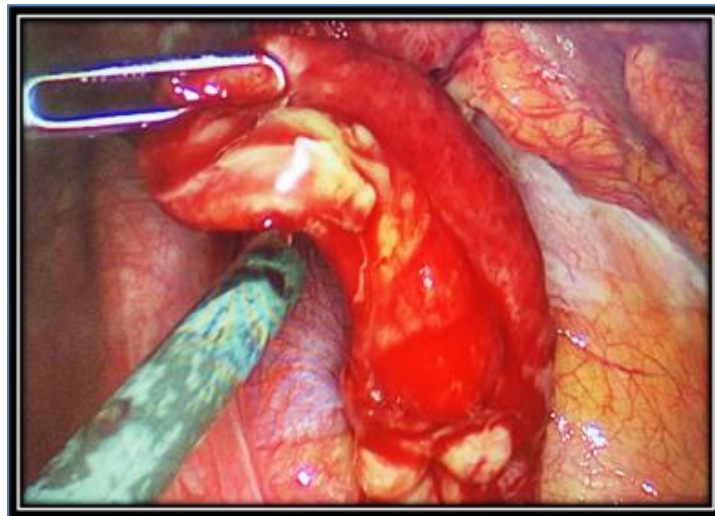
**Fig 1: Pursestring suture preparation**



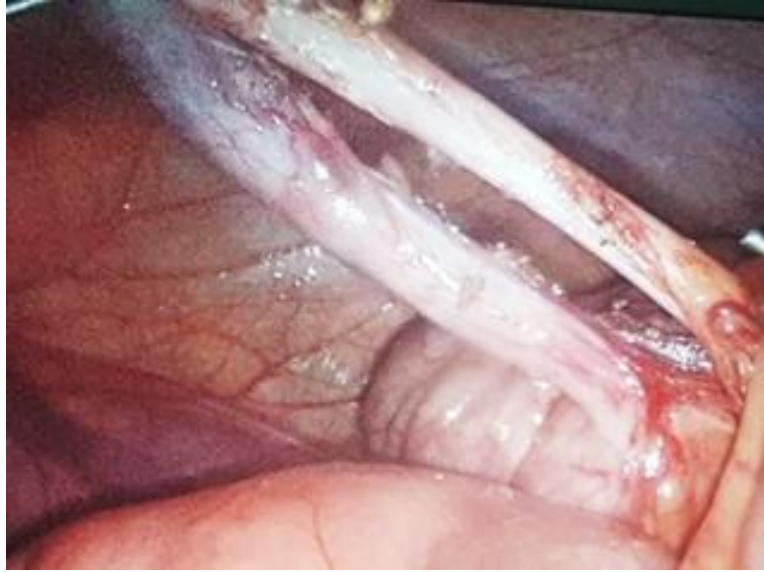**Fig 2: Three port lap appendectomy technique**



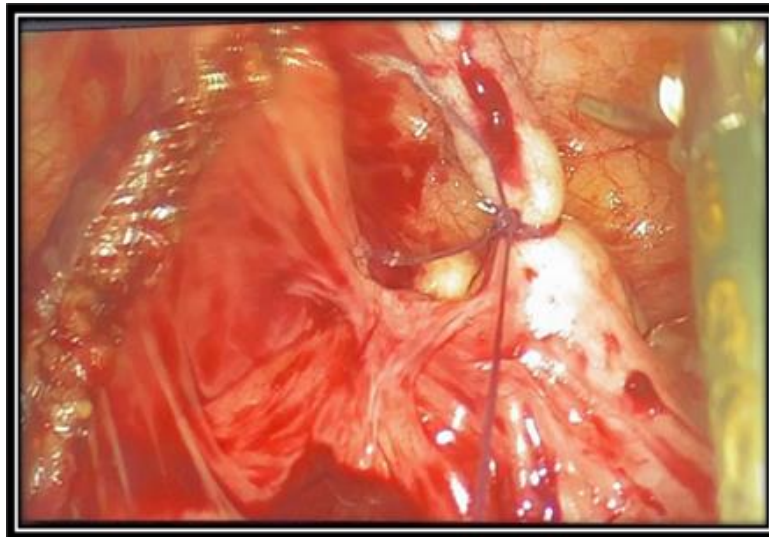**Fig 3: Appendix identification (Acute appendicitis)**



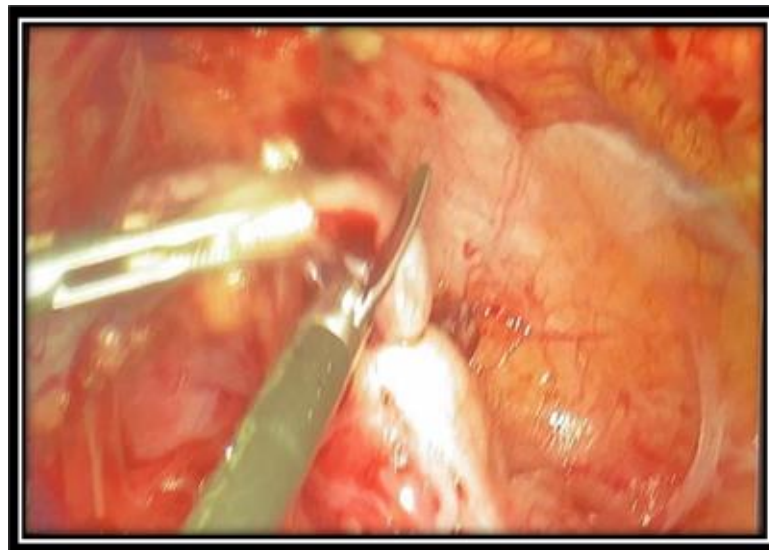**Fig 4: Appendix dissection with monopolar electrocautery**



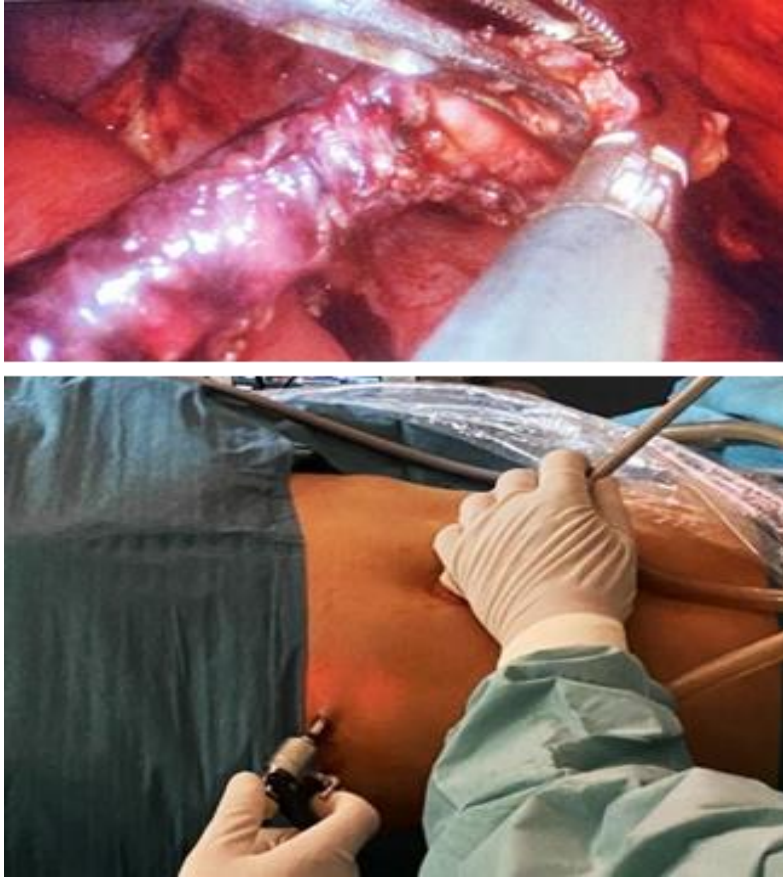
**Fig 5: After a good appendix meso dissection by electrocautery monopolar (appendicular mesentery not bulky)**



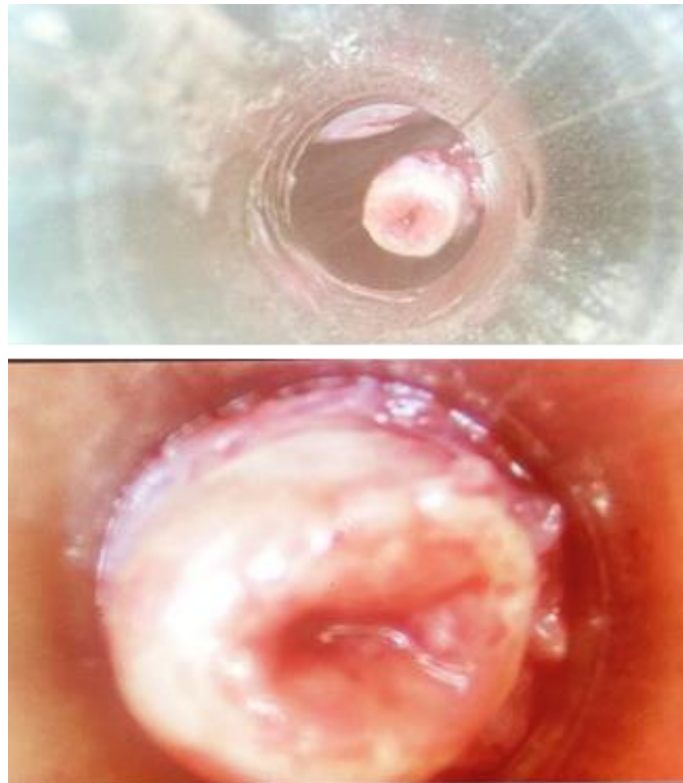
**Fig 6: Pursestring suture with 2-0 vicryl (double knots ligation)**



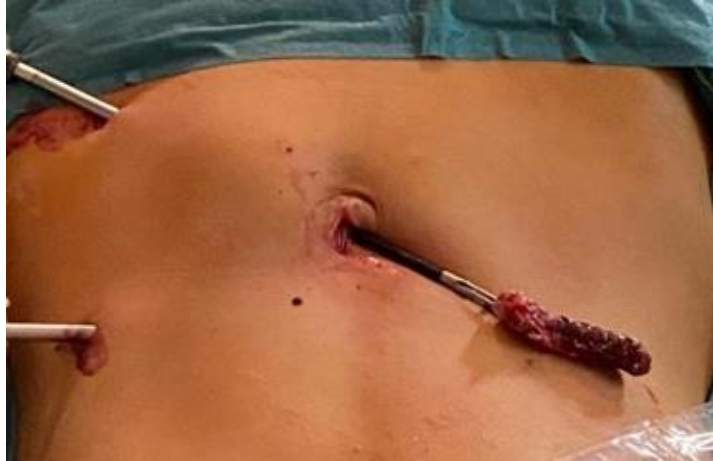**Fig 7: Scissors appendix (base) section**



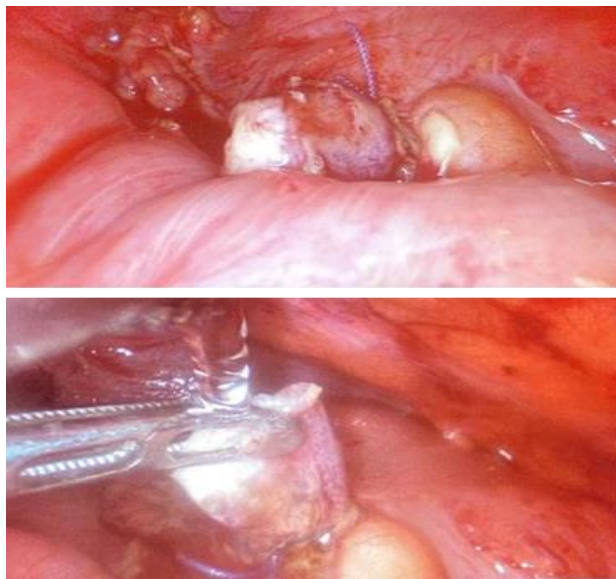
**Fig 8: Alignment of camera trocar with the forceps taking the appendix trocar to guide the under visual control extraction**



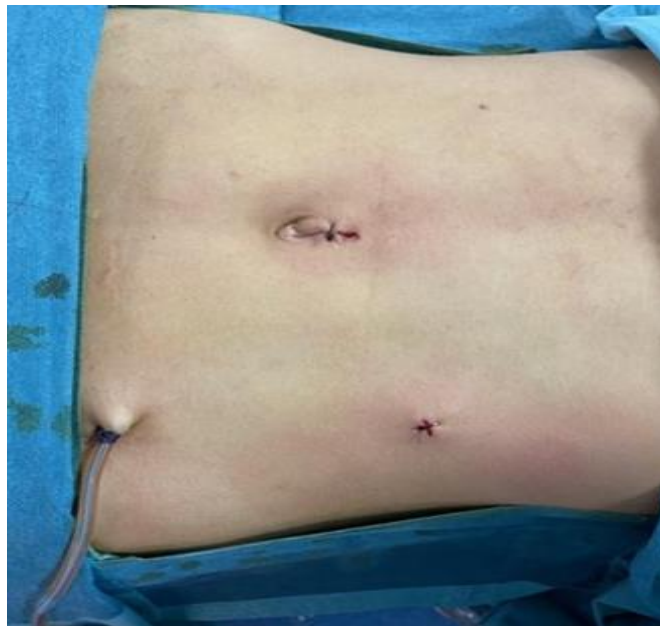
**Fig 9: The under visual control (camera) extraction.**



**Figure 10: Appendicular extraction through the umbilical torcar.**



**Fig 11: The appdicular stump and peritoneal lavage**



**Fig 12: Systematic drainage**

#### 4. DISCUSSION

Acute appendicitis (AA) is a clinical diagnosis [1, 2]. The first appendectomy was performed in New York in 1886 [1], and thereafter, appendectomy was considered the most common emergency surgery [2-4]. Prompt appendectomy has long been the standard of care for AA because of the risk of progression to advanced pathophysiology [3]. Currently, laparoscopic appendectomy (LA) is available as the first therapeutic choice for AA [1, 3]. However, surgeons on call, when a patient is admitted is an important factor for determining whether a patient can receive an advantageous LA or conventional open surgery [3]. Additionally, a poor clinical course in a hospital with an unfavorable combination for emergent laparoscopic surgery is a critical matter [3]. In brief, factors of hospitals and physicians affect the severity of AA which develops in a progressive and irreversible manner, even if the clinical course of AA can be temporarily modified by intentional medications. Reliable and real-time diagnosis of AA can be made based on findings of the white blood cell count and enhanced ultrasonography or computed tomography. Emergent laparoscopic appendectomy (LA) is considered as the first therapeutic choice for AA. Laparoscopic surgery is a major surgical advance that has enabled surgeons to decrease hospital and total recovery times for patients. Many laparoscopic series report lower infection and complication rates as compared with the equivalent open procedures [4].

#### 5. CONCLUSION

The laparoscopic appendectomy can be useful in male and female, at any age, in all the phases of acute appendicitis and in all anatomic sites of vermiform appendix.

#### REFERENCES

1. Costa-Navarro, D., Jiménez-Fuertes, M., & Illán-Riquelme, A. (2013). Laparoscopic appendectomy: quality care and cost-effectiveness for today's economy. *World Journal of Emergency Surgery*, 8, 1-5.
2. Durai, R., Thomas, D., & Doughan, S. (2014). Fishing method of appendix extraction during laparoscopy. *The Annals of The Royal College of Surgeons of England*, 96(3), 247-247. doi: 10.1308/rcsann.2014.96.3.247a.
3. Dai, L., & Shuai, J. (2017). Laparoscopic versus open appendectomy in adults and children: a meta-analysis of randomized controlled trials. *United European gastroenterology journal*, 5(4), 542-553.
4. Shalak, F., AlMulhim, S. I., Ghantous, S., & Yazbeck, S. (2009). Laparoscopic appendectomy: burden or benefit? A single-center experience. *Journal of Laparoendoscopic & Advanced Surgical Techniques*, 19(3), 427-429.