

Tuberculous Peritonitis

Mahad Abdillahi^{1*}, Gaspard Nizigiyimana¹, Kamal Khadija¹, Majdabdessamad¹, Ettaoussi Abdelhak¹, Bouali Mounir¹, Abdelilah Elbakouri¹, El Hattabi Khalid¹, Ridha Allali²

¹Department of General Surgery, Ibn Rochd University Hospital, Hassan II University, Faculty of Medicine and Pharmacy of Casablanca, Morocco

²Department of Anatomic Pathology, Ibn Rochd University Hospital, Hassan II University, Faculty of Medicine and Pharmacy of Casablanca, Morocco

DOI: <https://doi.org/10.36347/sasjs.2025.v11i03.001>

| Received: 18.01.2025 | Accepted: 26.02.2025 | Published: 01.03.2025

*Corresponding author: Mahad Abdillahi

Department of General Surgery, Ibn Rochd University Hospital, Hassan II University, Faculty of Medicine and Pharmacy of Casablanca, Morocco

Abstract

Case Report

Peritoneal tuberculosis is a rare form of abdominal tuberculosis, ranking fourth among extrapulmonary tuberculosis. We report the case of a 23-year-old man from Guinea who presented acute abdominal pain, vomiting, and fever. The clinical examination revealed signs of generalized peritonitis. Laboratory tests showed leukocytosis and anemia, and the biopsy confirmed necrotizing granulomatous inflammation, indicating peritoneal tuberculosis. Despite surgical management, the patient rapidly died after the operation. This case underscores the importance of considering peritoneal tuberculosis as a differential diagnosis in patients presenting with acute peritonitis, especially in populations of the regions where tuberculosis is endemic.

Keywords: Peritonitis, tuberculosis, surgery.

Copyright © 2025 The Author(s): This is an open-access article distributed under the terms of the Creative Commons Attribution 4.0 International License (CC BY-NC 4.0) which permits unrestricted use, distribution, and reproduction in any medium for non-commercial use provided the original author and source are credited.

INTRODUCTION

Tuberculosis is an infectious disease caused by a bacterium called *Mycobacterium tuberculosis* [1]. According to the World Health Organization, it is responsible of 1.5 million people death worldwide. Peritoneal tuberculosis, defined by infection of the peritoneal serosa by this bacterium, accounts for 3.7% of abdominal tuberculosis cases [2]. We report the case of a patient with peritoneal tuberculosis that presented with a clinical presentation of generalized peritonitis.

OBSERVATION

The patient was a 23-year-old immigrant from Guinea, with no significant medical history, who presented with 3 days of diffuse abdominal pain starting in the peri-umbilical area, associated with bilio-food vomiting without any externalized digestive hemorrhage or digestive transit disorders. The patient had a fever and overall malaise.

Clinically, the patient was conscious and hemodynamically stable with a generalized abdominal tenderness. Rectal examination was painful then revealed a Douglas' sign.

The biology noticed a leukocytosis of 10,290/mm³, hypochromic normocytic anemia at 9.3 g/dl, and 160 mg/l of C-reactive protein.

An abdominal-pelvic computed tomography scan revealed a large pneumoperitoneum, more marked in the submesocolic region. There was a large peritoneal effusion with liquid density, encapsulated appearance, causing encapsulation of the small bowel loops, which were agglutinated and dilated, measuring up to 27 mm in diameter.

The patient underwent surgery with a median laparotomy. Surgical exploration revealed a large peritoneal effusion composed of digestive fluid which was evacuated after a sample collected, multiple adhesions between the omentum and the small bowel, small bowel and small bowel, and small bowel and the anterior parietal peritoneum, as well as necrotic spots and diffuse granulomas throughout the peritoneal cavity with the appearance of peritoneal tuberculosis. A 0.5 cm perforation of the small bowel with sclerosed edges was identified and sealed at the left iliac fossa. The procedure included a lateral non-terminal ileostomy, peritoneal cleaning, multiple biopsies from the edges of the perforation, greater omentum, and anterior parietal peritoneum, and drainage of the Douglas pouch with a

Salem tube. Unfortunately, the patient died 5 hours after surgery.

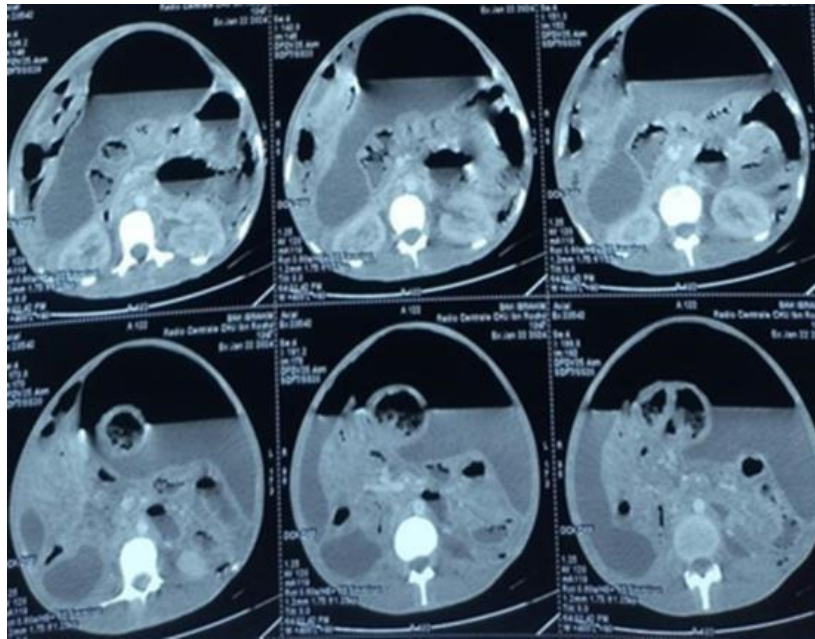


Figure 1: Computed tomography scan image

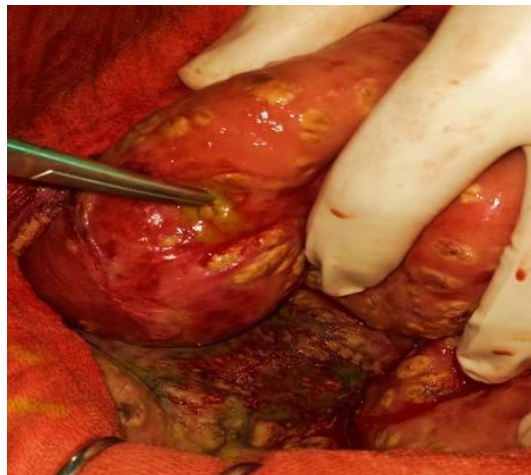


Figure 2: Perioperative image showing the perforation

Histopathological analysis of the biopsies revealed necrotizing granulomatous tuberculoid inflammation.

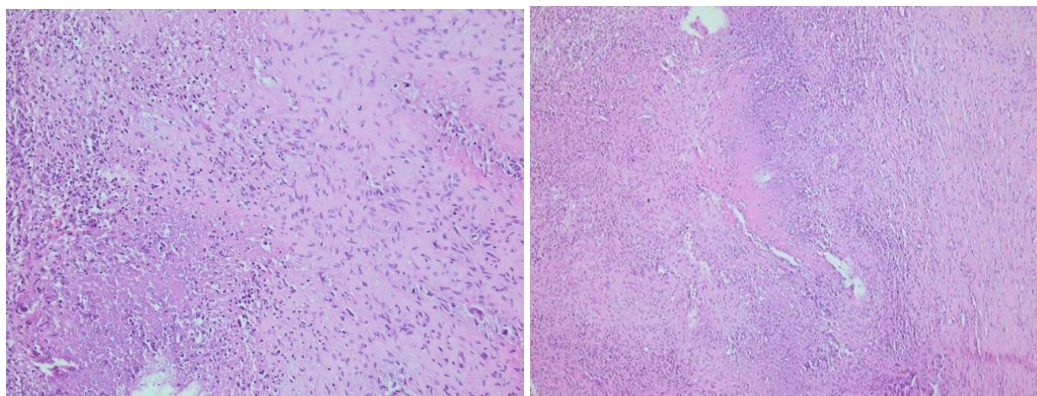


Figure 3: Histological images of the surgical specimen

Tuberculoid necrotizing granulomatous Tuberculoid necrotizing granulomatous inflammation (x100) inflammation (x200).

DISCUSSION

The incidence of tuberculosis in Morocco is 0.09% per year [3]. It can manifest in various clinical forms, ranging from acute peritonitis to insidious and chronic ascites, which makes its diagnosis difficult.

This condition is more common in developing countries, where it remains endemic. The main risk factors include immunosuppression especially Human Immunodeficiency Virus infection, but also malnutrition, chronic renal failure, and prolonged use of corticosteroids [4]. In the reported case, the patient did not present any notable risk factors, emphasizing that peritoneal tuberculosis can occur even in individuals who appear to be in good health.

The clinical presentation of peritoneal tuberculosis is often non-specific, with symptoms such as abdominal pain, fever, weight loss, and a general deterioration condition [5]. In this case, the patient presented with acute diffuse abdominal pain, vomiting, and fever, suggesting a generalized peritonitis. This presentation is unusual and often confused with other acute surgical conditions such as perforated appendicitis, intestinal perforation, or complicated diverticulitis.

The diagnosis of peritoneal tuberculosis relies on a combination of clinical, biological, radiological, and histopathological data. The leukocytosis and elevated C-reactive protein observed in the patient are non-specific signs but indicative of a severe infection or inflammation. The diagnosis is confirmed by peritoneal biopsy [6], which typically reveals necrotizing granulomatous inflammation, as it is in this case.

Abdominal computed tomography and ultrasound imaging can show suggestive signs of peritoneal tuberculosis, such as peritoneal thickening, peritoneal nodules, and ascites [7, 8]. However, these signs are not specific and may be confused with other abdominal pathologies.

The management of tuberculous peritonitis primarily involves two main components. The first involves stabilizing the patient with peripheral venous access, rehydration solutions, antibiotic therapy, surgical exploration, and peritoneal cleaning [9, 10]. The second component concerns standard antituberculous treatment for at least 6 months, typically involving isoniazid, rifampicin, ethambutol, and pyrazinamide [2]. Unfortunately, despite adequate surgical and medical management, the patient passed away in the hours

following the operation, highlighting the potential severity of this condition when not diagnosed and treated early.

CONCLUSION

Peritoneal tuberculosis should be considered as a differential diagnosis in cases of acute peritonitis, especially in endemic areas or among patients immigrating from such regions. Rapid recognition and appropriate treatment are essential to improve clinical outcomes, as a delayed diagnosis can lead to high morbidity and mortality, as demonstrated in this case. It is crucial to raise awareness among clinicians about this atypical presentation of tuberculosis.

REFERENCES

- Jabri, H., Lakhdar, N., El Khattabi, W., & Afif, H. (2016). *Revue de pneumologie clinique*, 72(5), 320-325.
- Diallo, I., Omar Soko, T., Rajack Ndiaye, A., & Klotz, F. (2020). *Tuberculose abdominale*, EMC gastro-entérologie, 2020.
- Bouchaib, A. E., Drissi, J., Babahabib, A., Elhassani, M. E. M., & Kouach, J. (2022). Tuberculose péritonéale pseudo tumorale: à propos d' une série de 14 cas. *Pan African Medical Journal*, 43(1), 130.
- Aazri, L., Aitbatahar, S., & Amro, L. *Revue des Maladies Respiratoires Actualités*, 2020-01-01, 12(1), 264-264.
- Priya, B. S., Adithya, C., & Christina, Y. Murray & Nadel's Textbook of Respiratory Medicine, 53, 692-707.e5.
- Gdoura, H., Massanou, S., Chtourou, L., Moalla, M., Mnif, L., Amouri, A., Boudabous, M., & Tahri, N. *La Revue de Médecine Interne*, 2022-12-01, 43, A462A463.
- Souissi, S., Nadia, B. M., Ben Safta, N., Hafi, M., Monia, F., Boubaker, J., Laabidi, A., & Serghini, M. *La Revue de Médecine Interne*, 2022-06-01, 43, A165-A165.
- Ndiaye, A., Mbengue, A., Diouf, C. T., Soko, T. O., Niang, A., & Diakhaté, I. C. (2009). *Dakar – Sénégal, Journal De Radiologie*, 2009.
- Yang, T. Y., Tian, Y. C., Yen, T. H., Chang, M. Y., Lin, C. Y., & Liu, S. H. (2023). Tuberculous peritonitis in patients on peritoneal dialysis: a 35-year experience from a large medical center in Northern Taiwan. *Renal Failure*, 45(1), 2153064.
- Mousa, H., Abdel-Kader, S., & Abu-Zidan, F. M. (2021). Management of abdominal tuberculosis in a community-based hospital in a high-income developing country. *World Journal of Emergency Surgery*, 16(1), 25.