

Challenges Faced Along the Learning Curve of Performing Laparoscopic Surgery to Manage Acute Cholecystitis

Dr. Farhana Iftekhar Bonnie^{1*}, Dr. Masuda Joya², Prof. Dr. Samiron K. Mandol³, Prof. Dr. Shormishta Roy⁴

¹Registrar, Department of Surgery, BIRDEM General Hospital & Ibrahim Medical & Dental College, Dhaka, Bangladesh

²Registrar, Department of Surgery, BIRDEM General Hospital & Ibrahim Medical & Dental College, Dhaka, Bangladesh

³Professor & Head, Department of Surgery, BIRDEM General Hospital & Ibrahim Medical & Dental College, Dhaka, Bangladesh

⁴Professor, Department of Surgery, BIRDEM General Hospital & Ibrahim Medical & Dental College, Dhaka, Bangladesh

DOI: <https://doi.org/10.36347/sasjs.2025.v11i03.014>

| Received: 22.01.2025 | Accepted: 26.02.2025 | Published: 10.03.2025

*Corresponding author: Dr. Farhana Iftekhar Bonnie

Registrar, Department of Surgery, BIRDEM General Hospital & Ibrahim Medical & Dental College, Dhaka, Bangladesh

Email: iftekharfarhana@gmail.com

Abstract

Original Research Article

Background: Laparoscopic cholecystectomy (LC) is the standard treatment for acute cholecystitis (AC), but the procedure poses significant challenges during the learning curve, especially in complex cases. This study evaluates the difficulties encountered by surgeons at the beginning while performing Laparoscopic surgery in AC. **Objective:** To assess the challenges faced by beginner surgeons initially while performing LC for AC. **Methods:** This prospective study was conducted at BIRDEM General Hospital from July 2023 to June 2024, involving 97 patients with AC who underwent LC. Patients aged 25–72 years with AC were included, while those with severe comorbidities (ASA III or higher), chronic cholecystitis, gallbladder polyps, choledocholithiasis, pancreatitis, or a history of previous laparotomy were excluded. Data were analyzed by MS Office tools. **Results:** Among the 97 patients with acute cholecystitis, 47.4% had a single episode before surgery, 34.0% had two episodes, and 19.6% had repeated attacks. Per-operative findings highlighted challenges such as varying degrees of pericholecystic adhesion, with 58.7% having none to minimal adhesion in single-episode patients. Surgical procedures were predominantly completed within 2 hours (51.5%), while a few cases needed more than 2 hours and active assistance from expert senior surgeons. Here the findings emphasize the complexities faced during the learning curve of laparoscopic cholecystectomy for acute cholecystitis and some tips and tricks to acquire expertise and better patients outcome. **Conclusion:** The learning curve for laparoscopic cholecystectomy in acute cholecystitis is steeper due to patient-related factors and technical challenges. However, with preparation, skill acquisition, teamwork, and continued training, surgeons can overcome these obstacles and achieve excellent outcomes.

Keywords: Acute cholecystitis, Complications, Difficulties, Learning curve, Laparoscopic surgery.

Copyright © 2025 The Author(s): This is an open-access article distributed under the terms of the Creative Commons Attribution 4.0 International License (CC BY-NC 4.0) which permits unrestricted use, distribution, and reproduction in any medium for non-commercial use provided the original author and source are credited.

INTRODUCTION

Laparoscopic cholecystectomy (LC) is the most performed surgery worldwide and is the established gold standard for treating acute cholecystitis (AC) due to its numerous advantages as a minimally invasive surgery. However, it requires a high level of technical skill and experience to perform safely and effectively. In this article, we are going to share our journey along the learning curve of laparoscopic surgery, especially in managing AC, and provide some tips and tricks that may help other surgeons who want to learn and master this procedure. The introduction of LC has significantly reduced postoperative pain, hospital stay, and overall recovery time compared to open cholecystectomy, making it the preferred approach for gallbladder diseases [1]. Despite these benefits, LC for AC remains

technically challenging, particularly for surgeons in training, due to the presence of inflamed and friable tissues, adhesions, and distorted anatomy [2,3]. The learning curve for LC is influenced by multiple factors, including the surgeon's previous experience, patient selection, and intraoperative difficulties, which can impact operative time, complication rates, and conversion to open surgery [4]. Several studies have suggested that at least 50–100 procedures are required for a surgeon to achieve proficiency in LC [5]. During this learning phase, complications such as bile duct injuries, excessive bleeding, and prolonged operative times are more common, highlighting the need for structured training and expert supervision [6,7]. The difficulty level of LC further increases in patients with recurrent AC, diabetes, or delayed presentation, as

Citation: Farhana Iftekhar Bonnie, Masuda Joya, Samiron K. Mandol, Shormishta Roy. Challenges Faced Along the Learning Curve of Performing Laparoscopic Surgery to Manage Acute Cholecystitis. SAS J Surg, 2025 Mar 11(3): 326-332.

inflammation leads to severe adhesions and an increased risk of complications [8]. To overcome these challenges, various techniques have been proposed, such as early LC within 72 hours of symptom onset, fundus-first dissection, subtotal cholecystectomy, and the use of intraoperative imaging to prevent bile duct injury [9]. Simulation-based training, mentor ship programs, and gradual skill acquisition through supervised surgeries have also been recommended to enhance surgical competency and ensure patient safety [10]. This study aimed to assess the challenges faced by surgeons while performing LC for AC at early stages of their learning curves independently with unscrubbed expert supervision. By analyzing our experience, we hope to provide insights that can help optimize the technical challenges and overcome and improve expertise in new laparoscopy surgeons.

METHODOLOGY

This prospective study was conducted at BIRDEM General Hospital over one year, from July 2023 to June 2024, involving 97 patients diagnosed with acute cholecystitis (AC) who underwent laparoscopic cholecystectomy (LC). The procedures were performed by two surgeons under the direct supervision of an unscrubbed senior trainer.

Inclusion and Exclusion Criteria

Patients aged between 25 and 72 years with AC, irrespective of sex, were included in the study. Exclusion criteria comprised patients with severe comorbidity classified as ASA III or higher, those undergoing LC for indications other than AC, such as chronic cholecystitis, adenomyomatosis, or gallbladder polyps. Additionally, patients with AC complicated by choledocholithiasis, pancreatitis, those requiring other surgical interventions, and those with a history of previous laparotomy were excluded.

Patient Classification

Among the 97 patients, 46 (47.42%) presented with a single episode of AC, 33 (34.02%) had a recent history of an acute attack, and 18 (18.56%) had recurrent episodes. A significant proportion of the patients were diabetic.

Surgical Procedure

All patients underwent LC within three days of symptom onset. The procedures were performed in a standardized manner, following institutional protocols to ensure consistency and minimize complications. The surgeons in training performed the surgeries under real-time guidance, with the senior trainer supervising without direct intraoperative participation.

Data Collection and Analysis

Relevant clinical and perioperative data, including patient demographics, disease history, intraoperative challenges, complications, and outcomes, were recorded. Data were analyzed using MS Office tools to evaluate the learning curve, difficulties encountered, and patient outcomes.

RESULT

Among the 97 patients who underwent laparoscopic cholecystectomy for acute cholecystitis, 46 (47.4%) had a single episode before surgery, 33 (34.0%) had two episodes, and 19 (19.6%) experienced repeated attacks. Per-operative findings for patients with a single episode revealed pericholecystic adhesions varying in severity: 27 (58.7%) had none to minimal adhesions, 16 (34.8%) had moderate adhesions, and 3 (6.5%) had gross adhesion. Gallbladder wall characteristics included 16 (34.8%) with normal thickness, 26 (56.5%) with mild thickening, and 14 (30.4%) with edematous thickening. Gallbladder lumen analysis showed 15 (32.6%) with mucocele, 5 (10.9%) with empyema, and 10 (21.7%) with thick lithogenic bile. In patients with two episodes, adhesions were more pronounced. Only 2 (6.1%) had none to minimal adhesions, 20 (60.6%) had moderate adhesions, and 11 (33.3%) had gross adhesions. Gallbladder wall thickening was observed in 17 (51.5%) with mild thickening and 14 (42.4%) with edematous thickening. Regarding gallbladder lumen, 11 (33.3%) had mucocele, 5 (15.2%) had empyema, and 3 (9.1%) had thick lithogenic bile. In patients with recurrent episodes, pericholecystic adhesions were more severe: 11 (57.9%) had moderate adhesions, 5 (26.3%) had gross adhesions, and 3 (15.8%) had severe adhesions leading to distorted anatomy. Gallbladder wall changes included 6 (31.6%) with mild thickening, 10 (52.6%) with edematous thickening, and 3 (15.8%) with a gangrenous gallbladder wall. Gallbladder lumen analysis showed 10 (52.6%) with mucocele and 4 (21.1%) with emphysema. During the procedures, 42 (43.3%) cases required aspiration before dissection, and 60 (61.9%) cases used graspers or toothed forceps. Cystic artery and duct control was achieved with Hemo-clips in 94 (96.9%) cases. Bile leakage occurred in 4 (4.1%) cases. Hemostasis was primarily achieved with gauze pressure in 85 (87.6%) cases. Peritoneal wash was performed in 79 (81.4%) cases, and all gallbladders were extracted through the umbilical port. The majority of procedures (51.5%) were completed in less than 2 hours. Post-operatively, 73 (75.3%) patients were discharged on the first day, and 21 (21.6%) on the second day, with 3 (3.1%) requiring a third day for discharge.

Table 1: Number of acute attacks before operation (N=97)

Status	n	%
Single episode of acute episode	46	47.4%
After 2 episodes of attack	33	34.0%
After repeated attack	19	19.6%

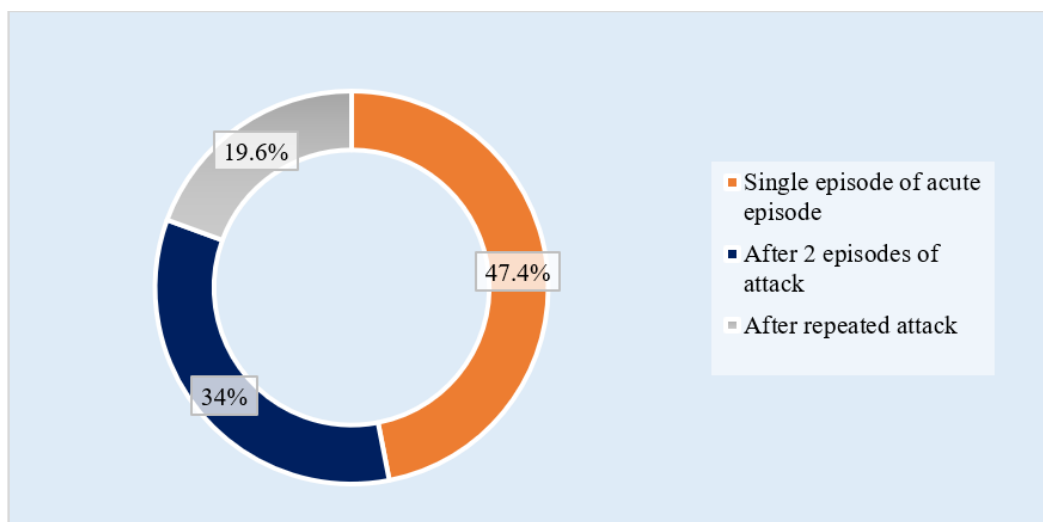


Figure I: Ring chart showed number of acute attacks before operation among patients (N=97)

Table 2: Patients with single episode of acute attack as per-operative findings (n=46)

Findings	n	%
Pericholecystic adhesion		
None to minimum pericholecystic adhesion	27	58.7%
Moderate adhesions	16	34.8%
Gross adhesion	3	6.5%
Gall bladder wall		
Normal thickness	16	34.8%
Mildly thickened	26	56.5%
Oedematose thick	14	30.4%
Gall bladder lumen		
Mucocele of gall bladder	15	32.6%
Empyema	5	10.9%
Thick lithogenic bile	10	21.7%
Multiple small stones with thick bile	2	4.3%
Large multiple stones	8	17.4%
Single large stone	6	13.0%

Table 3: Patients with two episodes of acute attack as per operative findings (n=33)

Findings	n	%
Pericholecystic adhesion		
None to minimum pericholecystic adhesion	2	6.1%
Moderate adhesions	20	60.6%
Gross adhesion	11	33.3%
Gall bladder wall		
Normal thickness	2	6.1%
Mildly thickened	17	51.5%
Oedematose thick	14	42.4%
Gall bladder lumen		
Mucocele of gall bladder	11	33.3%
Empyema	5	15.2%
Thick lithogenic bile	3	9.1%
Multiple small stones with thick bile	4	12.1%
Large multiple stones	7	21.2%
Single large stone	3	9.1%

Table 4: Patients with recurrent episodes of acute attacks per operative findings (n=19)

Findings	n	%
Pericholecystic adhesion		
Moderate adhesions	11	57.9%
Gross adhesion	5	26.3%
Severe adhesion with distorted anatomy	3	15.8%
Gall bladder wall		
Mildly thickened	6	31.6%
Oedematose thick	10	52.6%
Gangrenous wall	3	15.8%
Gall bladder lumen		
Mucocele of gall bladder	10	52.6%
Empyema	4	21.1%
Large multiple stones	2	10.5%
Single large stone	3	15.8%

Table 5: Procedure-related Information (N=97)

Procedure	n	%
Thick-walled gall bladder needed aspiration before dissection	42	43.3%
Grasper or toothed forceps to hold the gallbladder	60	61.9%
Use only electro-cautery to dissect	30	30.9%
Alternate blunt dissection and electro cautery used in	66	68.0%
Only Blunt dissection applied	17	17.5%
Cystic artery and duct secured with Hemo-clip	94	96.9%
Cystic duct secured with suture	3	3.1%
Bile leakage from hepatic fossa of liver	4	4.1%
From aberrant accessory right duct	1	1.0%
Oozing managed by gauge pressure	85	87.6%
Suturing of the liver bed required	15	15.5%
Peritoneal wash with warm NS	79	81.4%
Gallbladder extraction via Endo bag through umbilical port	97	100.0%
Intra-abdominal drain kept for 24 hours	44	45.4%
Intra-abdominal drain kept for 48 hours	3	3.1%

Table 6: Operative time (N=97)

Operative time	n	%
< 2 hours	50	51.5%
2 hours	42	43.3%
> 2 hours	5	5.2%

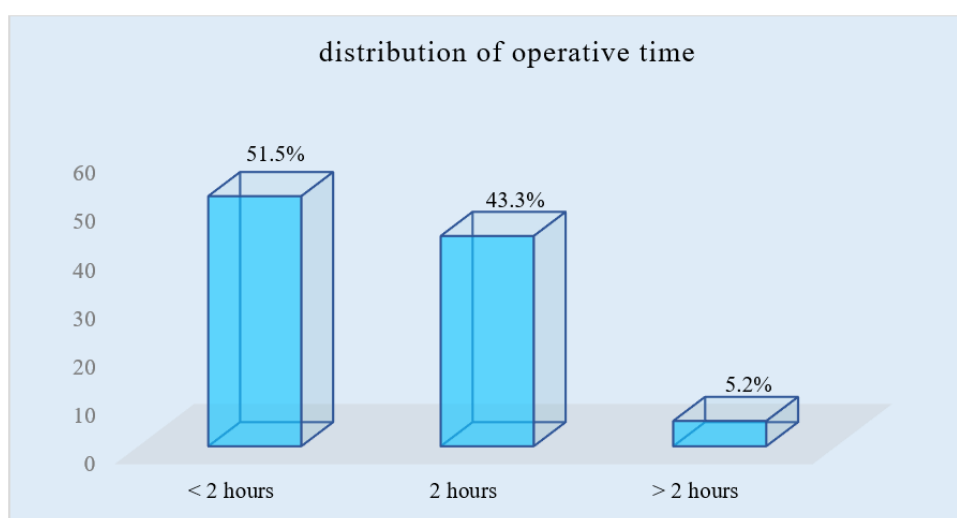
**Figure II: Column chart showed operative time of the of the participants (N=97)**

Table 7: Post-operative outcomes (N=97)

Post-operative Outcome	n	%
Discharged on 1 st post-op day	73	75.3%
Discharged on 2 nd post-op day	21	21.6%
Discharged on 3 rd post-op day	3	3.1%

DISCUSSION

Laparoscopic cholecystectomy (LC) has become the gold standard for treating gallstone disease due to its advantages, including reduced postoperative pain, quicker recovery, and shorter hospital stays, compared to open cholecystectomy [11]. However, the learning curve associated with performing LC, particularly in cases of acute cholecystitis (AC), presents several challenges due to technical difficulties and patient-related factors. Despite these challenges, laparoscopic surgery remains a superior approach, offering less invasive management and better recovery outcomes than open surgery [12,13].

Patient-Related Factors

In AC, inflammation causes distortion and adherence of the hepatocystic triangle and surrounding structures, making it difficult to identify critical structures such as the cystic duct and artery. This results in a more technically challenging surgery [14]. Our findings align with other studies indicating that severe adhesions and changes in the gallbladder wall, such as thickening and edema, contribute to surgical difficulties [15]. In our cohort, patients with recurrent episodes of AC showed significantly more severe adhesions and gallbladder wall changes, consistent with reports that chronic inflammation exacerbates surgical difficulty [16].

Technical Challenges

In our study, 61.9% of the surgeries required the use of graspers or toothed forceps for retraction, highlighting the difficulty of visualizing and manipulating the gallbladder, especially in the presence of adhesions. Gross adhesions, as seen in 33.3% of patients with two episodes of AC and 26.3% of those with recurrent attacks, often obscure critical anatomical landmarks and compromise the safety of dissection [17,18]. Our experience of thick, edematous gallbladders and the need for aspiration to facilitate dissection reflects similar challenges reported in the literature [19]. Furthermore, neovascularization resulting from inflammation led to increased bleeding in some cases, obscuring the surgical field. This finding is consistent with the challenges reported by other authors, emphasizing the need for careful control of bleeding and judicious use of electro-cautery [20]. Creating the "critical view of safety" (CVS) in the hepatocystic triangle, as described by Strasberg *et al.*, was essential in avoiding bile duct injury and other complications, which proved to be time-consuming during our early cases [21].

Skill Acquisition and Training

Building proficiency in laparoscopic surgery for AC requires both technical skills and knowledge. Early in the learning curve, handling thick, inflamed tissues, managing adhesions, and maintaining visualization were particularly challenging [22]. Our findings suggest that preparation, such as familiarization with gallbladder anatomy, as well as simulation training, is crucial for skill acquisition [23]. By starting with simple cases and progressively handling more complicated ones, the surgeon can build confidence and competence over time [24]. Our study also highlighted the importance of team dynamics, effective communication, and collaboration with senior surgeons. This is consistent with the findings of other studies that emphasize the role of teamwork in overcoming the challenges faced during the learning curve of laparoscopic surgery [25].

Psychological Barriers and Systemic Challenges

The fear of complications, particularly bile duct injury, can cause anxiety and affect a surgeon's performance, especially early in the learning curve. Our experience reflects the psychological barriers observed in other studies, where fear of complications led to hesitancy in performing difficult dissections [26]. However, as one gains more experience, the confidence to handle such challenges increases. Systemic challenges, such as a lack of advanced laparoscopic tools and balancing training with service demands, also hinder the smooth acquisition of laparoscopic skills. Similar concerns have been raised in other studies, where resource limitations were identified as significant barriers to mastering laparoscopic techniques.

LIMITATIONS

The limitations of this study include its single-center design, limiting generalization. The sample size of 97 patients may not capture rare complications or outcomes. The findings reflect the experiences of two surgeons, which may not represent a broader range of skill levels. Long-term outcomes were not assessed, limiting comprehensive analysis.

CONCLUSION

This study highlights the challenges faced during the learning curve of performing laparoscopic cholecystectomy for managing acute cholecystitis. Variations in pericholecystic adhesions, gallbladder wall changes, and lumen characteristics presented surgical complexities, particularly in patients with repeated episodes. Despite these challenges, most procedures were completed within 2 hours, and the majority of

patients had a smooth post-operative recovery. This experience underscores the importance of continuous training and adapting techniques to improve outcomes while navigating the learning curve of laparoscopic surgery.

RECOMMENDATIONS

Future studies should involve larger, multi-center cohorts to enhance generalizability. Training programs should emphasize early hands-on experience with simpler cases to build confidence. Access to advanced laparoscopic tools and simulation-based training should be prioritized to shorten the learning curve and improve outcomes in managing acute cholecystitis.

REFERENCES

1. Strasberg, S. M. (2008). Acute calculous cholecystitis. *New England Journal of Medicine*, 358(26), 2804-2811.
2. Okamoto, K., Suzuki, K., Takada, T., Strasberg, S. M., Asbun, H. J., Endo, I., ... & Yamamoto, M. (2018). Tokyo Guidelines 2018: flowchart for the management of acute cholecystitis. *Journal of Hepato-biliary-pancreatic Sciences*, 25(1), 55-72.
3. Giger, U. F., Michel, J. M., Opitz, I., Inderbitzin, D. T., Kocher, T., Krähenbühl, L., ... & Group, T. S. S. (2006). Risk factors for perioperative complications in patients undergoing laparoscopic cholecystectomy: analysis of 22,953 consecutive cases from the Swiss Association of Laparoscopic and Thoracoscopic Surgery database. *Journal of the American College of Surgeons*, 203(5), 723-728.
4. MacFadyen, B. V., Vecchio, R., Ricardo, A. E., & Mathis, C. R. (1998). Bile duct injury after laparoscopic cholecystectomy: the United States experience. *Surgical endoscopy*, 12, 315-321.
5. Hori, T., Tokumura, H., ... & Yamamoto, M. (2017). Laparoscopic cholecystectomy for acute cholecystitis: a nationwide survey conducted by the Japan Society for Endoscopic Surgery. *Surg Endosc*. 31(11), 4876-83.
6. Gupta, V., & Jain, G. (2019). Safe laparoscopic cholecystectomy: Adoption of universal culture of safety in cholecystectomy. *World journal of gastrointestinal surgery*, 11(2), 62.
7. Flum, D. R., Cheadle, A., Prael, C., Dellinger, E. P., & Chan, L. (2003). Bile duct injury during cholecystectomy and survival in medicare beneficiaries. *Jama*, 290(16), 2168-2173.
8. Elshaer, M., Gravante, G., Thomas, K., Sorge, R., Al-Hamali, S., & Ebdewi, H. (2015). Subtotal cholecystectomy for "difficult gallbladders": systematic review and meta-analysis. *JAMA surgery*, 150(2), 159-168.
9. Bittner, R., Bain, K., Bansal, V. K., Berrevoet, F., Bingener-Casey, J., Chen, D., ... & Yao, Q. (2019). Update of Guidelines for laparoscopic treatment of ventral and incisional abdominal wall hernias (International Endohernia Society (IEHS))—Part A. *Surgical endoscopy*, 33, 3069-3139.
10. Aggarwal, R., Mytton, O. T., Derbrew, M., Hananel, D., Heydenburg, M., Issenberg, B., ... & Reznick, R. (2010). Training and simulation for patient safety. *BMJ Quality & Safety*, 19(Suppl 2), i34-i43.
11. Cuschieri, A. (2018). The history of laparoscopic surgery. *World J Surg*. 2019;43(1):1-10. 2
12. Targarona EM, et al. Laparoscopic cholecystectomy: state of the art. *Am J Surg*. 216(5), 927-933.
13. Gagner, M. (2020). Laparoscopic Duodenal Switch. *Foregut Surgery: Achalasia, Gastroesophageal Reflux Disease and Obesity*, 265-272.
14. Broderick, R. C., Omelanczuk, P., Harnsberger, C. R., Fuchs, H. F., Berducci, M., Nefa, J., ... & Horgan, S. (2015). Laparoscopic cholecystectomy using a novel single-incision surgical platform through a standard 15mm trocar: initial experience and technical details. *Surgical endoscopy*, 29, 1250-1256.
15. Popivanov G, et al. Laparoscopic cholecystectomy for acute cholecystitis: a review of complications. *Surgical Practice*. 2020;24(3):201-206.
16. Liu, X. X., Ma, Y. Q., Kong, L. Y., Su, Y. Z., Robinson, N., & Liu, J. P. (2024). Unveiling the therapeutic role of Dachaihu decoction in acute cholecystitis: a comprehensive systematic review and meta-analysis of its efficacy and safety. *Frontiers in Pharmacology*, 15, 1497072.
17. Ismail H, et al. (2020). Laparoscopic cholecystectomy: complications and their management. *J Minimal Access Surg*. 16(2), 128-132.
18. Chen Z, et al. (2021). Challenges and solutions in laparoscopic cholecystectomy for acute cholecystitis. *J Surg Res*. 26(4):12-17.
19. Greenstein AJ, et al. Laparoscopic cholecystectomy in the setting of acute cholecystitis: a review. *J Gastrointest Surg*. 2018;22(5):985-991.
20. Strasberg, S. M. (2017). A perspective on the critical view of safety in laparoscopic cholecystectomy. *Annals of Laparoscopic and Endoscopic Surgery*, 2(5).
21. Palanivelu, C., et al. (2019). A critical view of safety in laparoscopic cholecystectomy. *Surgical Endoscopy*. 33(5), 1283-1291.
22. Loureiro, D., et al. (2020). Laparoscopic cholecystectomy training and the learning curve: simulation and real cases. *Surg Endosc*. 34(2), 763-769.
23. Kim, M., et al. (2018). Simulation-based training for laparoscopic surgery. *Surgical Practice*. 23(3), 15-20.
24. Rives, J., et al. (2021). Surgical training in laparoscopic cholecystectomy: challenges and strategies. *Am J Surg*. 213(4), 820-826.
25. Worrell, S., et al. (2020). The importance of teamwork in laparoscopic surgery. *J Laparoendosc Adv Surg Tech A*. 30(3), 304-309.

25. Gillman L, et al. psychological aspects of laparoscopic surgery training. *Surgical Practice*. 2018;22(4):224-228.
26. Ellis H, et al. Surgical challenges and limitations in laparoscopic cholecystectomy: a global perspective. *World J Surg*. 2022;46(10):2950-2957.
27. Gallaher, Jared R., and Anthony Charles. "Acute cholecystitis: a review." *Jama* 327.10 (2022): 965-975.
28. Bansal, V. K., Misra, M. C., Agarwal, A. K., Agrawal, J. B., Agarwal, P. N., Aggarwal, S., ... & Kapoor, V. K. (2019). SELSI consensus statement for safe cholecystectomy—prevention and management of bile duct injury—part A. *Indian Journal of Surgery*, 1-19.
29. Soper, N.J., et al. (2020). "Techniques of laparoscopic cholecystectomy: Challenges and solutions." *Surgical Endoscopy*.
30. Collaborative, A. M. B. R. O. S. E. "30-day Morbidity and Mortality after Cholecystectomy for Benign Gallbladder Disease (Hussain, 2011) (AMBROSE)." (2024).