

## Surgical Management of an Intraocular Foreign Body Incarcerated in the Iridocorneal Angle

Soufiane Droussi<sup>1\*</sup>

<sup>1</sup>CHU Mohammed VI, Tangier, Morocco

DOI: <https://doi.org/10.36347/sasjs.2026.v12i06.007>

| Received: 21.04.2026 | Accepted: 08.06.2026 | Published: 19.06.2026

\*Corresponding author: Soufiane Droussi

CHU Mohammed VI, Tangier, Morocco Email: [soufiane.droussi94@gmail.com](mailto:soufiane.droussi94@gmail.com).

### Abstract

### Case Report

Intraocular foreign bodies (IOFBs) are severe complications of open-globe injuries and may lead to irreversible visual impairment. Early diagnosis and timely surgical intervention are essential to reduce complications, particularly endophthalmitis. We report a 25-year-old man presenting four days after ocular trauma caused by a vegetal agent. Slit-lamp examination revealed an IOFB incarcerated within the iridocorneal angle. Surgical extraction using viscoelastic-assisted mobilization and capsulorhexis forceps resulted in complete visual recovery (10/10). This case highlights that favorable outcomes may still be achieved despite delayed presentation when prognostic factors are favorable.

**Keywords:** Intraocular Foreign Body, Open-Globe Injury, Iridocorneal Angle, Ocular Trauma, Endophthalmitis, Surgical Extraction, Viscoelastic.

**Copyright © 2026 The Author(s):** This is an open-access article distributed under the terms of the Creative Commons Attribution 4.0 International License (CC BY-NC 4.0) which permits unrestricted use, distribution, and reproduction in any medium for non-commercial use provided the original author and source are credited.

## INTRODUCTION

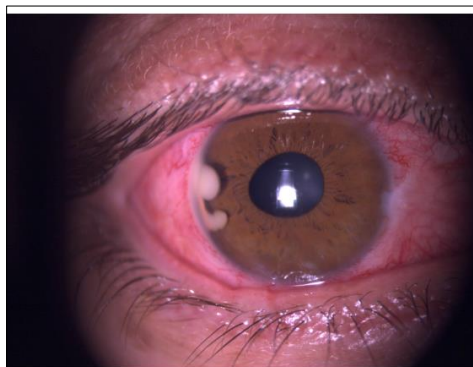
Ocular trauma is the leading cause of vision loss in young individuals. Intraocular foreign bodies (IOFBs) are found in 16% to 29.6% of open-globe injuries. Prompt management is crucial in determining the functional prognosis.

## CASE PRESENTATION

A 25-year-old patient with no significant past medical history presented to the ophthalmic emergency department with a red, painful right eye associated with decreased visual acuity, following ocular trauma caused by a vegetal agent four days prior.

Ophthalmologic examination of the right eye revealed a best-corrected visual acuity of 4/10. Anterior segment examination showed diffuse conjunctival hyperemia and the presence of an intraocular foreign body (IOFB) incarcerated in the iridocorneal angle between the 8 and 10 o'clock positions, surrounded by fibrin (Figure 1). The lens was clear, and fundus examination was unremarkable.

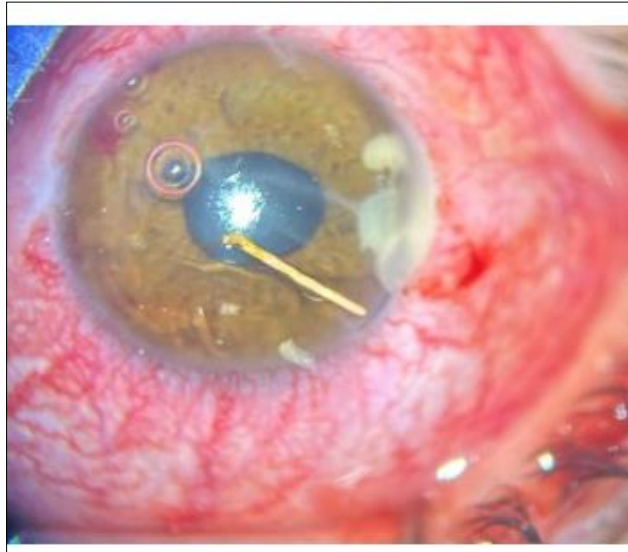
The foreign body was clearly visualized on slit-lamp examination, allowing direct surgical management without preoperative imaging.



**Figure 1:** Slit-lamp photograph showing an intraocular foreign body incarcerated in the iridocorneal angle (8 to 10 o'clock), surrounded by fibrin.

Following surgical exploration, a punctiform limbal wound at the 10 o'clock position was identified. The eye is stabilized by closing the open wound first.

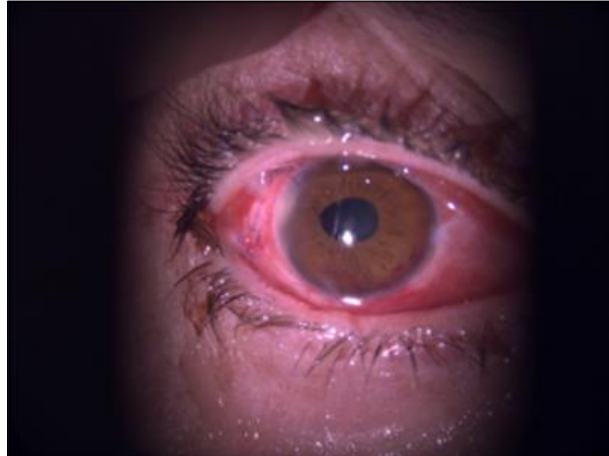
The intraocular foreign body, of vegetal origin (wood), was gently mobilized using a viscoelastic substance, then released and extracted using capsulorhexis forceps (Figure 2).



**Figure 2: Intraoperative image demonstrating mobilization and extraction of a vegetal intraocular foreign body.**

Postoperatively, the patient received broad-spectrum topical antibiotic therapy associated with anti-inflammatory treatment, given the high infectious risk related to the vegetal nature of the IOFB.

After three days of follow-up, visual acuity improved to 10/10, with a well-formed anterior chamber, a clear lens, and a normal fundus (Figure 3).



**Figure 3: Postoperative day three showing a quiet anterior segment with complete recovery**

At 3-month follow-up, ultrasound biomicroscopy (UBM) confirmed restoration of a normal iridocorneal angle, with no evidence of residual foreign material or angle damage.

## DISCUSSION

Intraocular foreign bodies (IOFBs) remain a major cause of visual morbidity following open-globe injuries, particularly in young adults. Visual prognosis depends on multiple factors, including the timing of intervention, the nature and location of the foreign body, associated ocular damage, and the occurrence of

infectious complications. Prompt diagnosis and appropriate management are therefore essential to optimize functional outcomes.

The present case is notable because of the unusual incarceration of a vegetal intraocular foreign body within the iridocorneal angle, associated with delayed presentation four days after injury. Despite these potentially unfavorable prognostic factors, complete visual recovery was achieved following surgical extraction.

The management of IOFBs depends largely on their anatomical location. Accurate identification of whether the foreign body is situated anterior or posterior to the iris is critical, as surgical approaches differ accordingly. For anterior chamber IOFBs without lens involvement, pupillary dilation should be avoided to minimize the risk of iatrogenic lens injury. Primary wound closure and stabilization of the globe remain essential steps before attempting foreign body removal.

Maintenance of adequate anterior chamber depth is particularly important during surgical extraction. Viscoelastic agents facilitate safe mobilization of the foreign body by preserving chamber stability, protecting the corneal endothelium, and minimizing additional intraocular trauma. In our patient, viscoelastic-assisted mobilization enabled atraumatic extraction of the foreign body while preserving adjacent ocular structures.

Early surgical intervention, ideally within 12–24 hours after injury, is widely recommended to reduce the risk of endophthalmitis and improve visual outcomes. Delayed presentation is traditionally associated with poorer prognosis, especially in the presence of organic foreign bodies. However, despite a 4-day delay, our patient achieved an excellent visual outcome. This favorable evolution may be explained by the anterior segment localization of the IOFB, the absence of posterior segment involvement, limited inflammatory response, and preservation of the lens. This observation suggests that delayed presentation does not invariably predict poor prognosis and that selected cases may still achieve favorable outcomes when managed appropriately.

Furthermore, the excellent visual outcome observed in our patient is consistent with the prognostic factors incorporated in the Ocular Trauma Score (OTS). Presenting visual acuity was relatively preserved (4/10), and no retinal detachment, endophthalmitis, lens damage, or posterior segment involvement was identified. These favorable characteristics would correspond to a high OTS category and likely contributed to the complete visual recovery achieved after surgery despite the delayed presentation.

The vegetal nature of the IOFB represents an additional concern because organic materials are associated with an increased risk of bacterial and fungal endophthalmitis. Consequently, these cases require careful postoperative surveillance and adequate antimicrobial therapy. In our patient, postoperative topical antibiotic treatment may have contributed to the absence of infectious complications. The potential role of prophylactic intravitreal antibiotics in high-risk situations, including delayed presentation and organic IOFBs, remains debated, although recent studies suggest possible benefit.

Finally, most IOFB-related injuries are preventable and frequently occur in occupational settings, emphasizing the importance of protective eyewear and preventive strategies to reduce ocular trauma incidence.

## CONCLUSION

Early diagnosis and prompt management of intraocular foreign bodies are essential to optimize visual outcomes. Even in delayed presentations, favorable results can be achieved when the foreign body is located in the anterior segment and appropriately managed. Organic IOFBs require particular attention due to their higher infectious risk.

## REFERENCES

1. Lima-Gómez V, García-Pacheco JM. Functional prognosis in ocular trauma. Does visual deficiency help in localizing the injuries that cause it?. *Cir Cir*. 2004;72(6):447-452.
2. Baillif-Gostoli S, Paoli S. Posterior segment wounds and foreign bodies. *EMC Ophthalmology*. 2020.
3. Essex RW, Yi Q, Charles PG, Allen PJ. Post-traumatic endophthalmitis. *Ophthalmology*. 2004 Nov;111(11):2015-22. doi: 10.1016/j.ophtha.2003.09.041. PMID: 15522366.
4. Colyer MH, Weber ED, Weichel ED, Dick JS, Bower KS, Ward TP, Haller JA. Delayed intraocular foreign body removal without endophthalmitis during Operations Iraqi Freedom and Enduring Freedom. *Ophthalmology*. 2007 Aug;114(8):1439-47. doi: 10.1016/j.ophtha.2006.10.052. Epub 2007 Feb 28. PMID: 17331579.
5. Liang Y, Liang S, Liu X, Liu D, Duan J. Intraocular Foreign Bodies: Clinical Characteristics and Factors Affecting Visual Outcome. *J Ophthalmol*. 2021 Jun 18;2021:9933403. doi: 10.1155/2021/9933403. PMID: 34239723; PMCID: PMC8235961.
6. Xing X, Liu F, Qi Y, Li J, Yu B, Wan L. Clinical Characteristics and Prognostic Factors of Patients with Intraocular Foreign Bodies from a Tertiary Eye Center in North China. *Clin Ophthalmol*. 2024 Dec 7;18:3635-3643. doi: 10.2147/OPHTH.S492986. PMID: 39664783; PMCID: PMC11633304.
7. Ohlhausen M, Menke BA, Begley J, Kim S, Debiec MR, Conrady CD, Yeh S, Justin GA. Advances in the management of intraocular foreign bodies. *Front Ophthalmol (Lausanne)*. 2024 Sep 2;4:1422466. doi: 10.3389/fopht.2024.1422466. PMID: 39285858; PMCID: PMC11402607.
8. Pelletier J, Reagan K, McLeod S, Kronk N, Dickson K, Ohman K, Santos M. Epidemiology of ocular trauma in limited-resource settings: a narrative review. *Front Med (Lausanne)*. 2025 Aug 25;12:1585527. doi: 10.3389/fmed.2025.1585527. PMID: 40927196; PMCID: PMC12415046.