

# Spontaneous Uterine Rupture in First Trimester Pregnancy: A Case Report

Laraichi A\*, Aalalou H, Saoud K, Mamouni N, Errarhay S, Bouchikhi C, Banani A

Obstetric gynecology department I. CHU Hassan II Fez Morocco

DOI: [10.36347/sasjs.2020.v06i12.005](https://doi.org/10.36347/sasjs.2020.v06i12.005)

| Received: 25.11.2020 | Accepted: 07.12.2020 | Published: 26.12.2020

\*Corresponding author: Amine Laraichi

## Abstract

## Case Report

Uterine ruptures are defined as non-surgical solutions of continuity of the wall of the pregnant uterus, due to a weakening factor and / or excessive tension on the uterine wall. We report the case of a spontaneous uterine rupture occurring in a young patient with in first trimester pregnancy.

**Keywords:** Uterine rupture, first trimester pregnancy.

Copyright © 2020 The Author(s): This is an open-access article distributed under the terms of the Creative Commons Attribution 4.0 International License (CC BY-NC 4.0) which permits unrestricted use, distribution, and reproduction in any medium for non-commercial use provided the original author and source are credited.

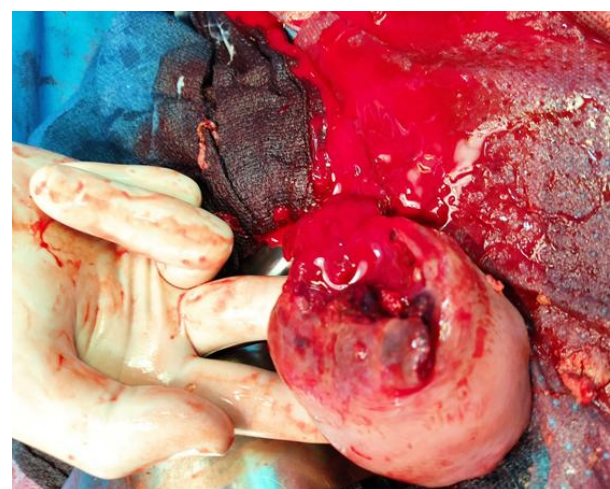## INTRODUCTION

Uterine rupture (UR), which is one of the most serious accidents that can occur during labor or at the end of pregnancy, is a major contributor to maternal and fetal mortality in developing countries. Its risk factors are a history of cesarean section or gynecological surgeries (myomectomy), uterine malformations, excessive use of uterotonics, etc. Most usually occur during labor in pregnant women with the risk factors. Of these spontaneous uterine ruptures, only 17% appear before the onset of labor. When the symptoms appear early in the pregnancy, the diagnosis made before laparotomy is that of late abortion. When an ultrasound is done either it is normal and the diagnosis remains uncertain, or it shows the hemoperitoneum and then the discussion is between obstetric hemorrhage and surgical hemorrhage (spontaneous splenic rupture, vascular rupture of other origins). However, its incidence in the 1st and 2nd trimester of pregnancy is rare. Faced with this real diagnostic problem, we report a case of uterine rupture in an open book during a 12-week pregnancy in a pregnant woman with a history of hemostatic curettage.

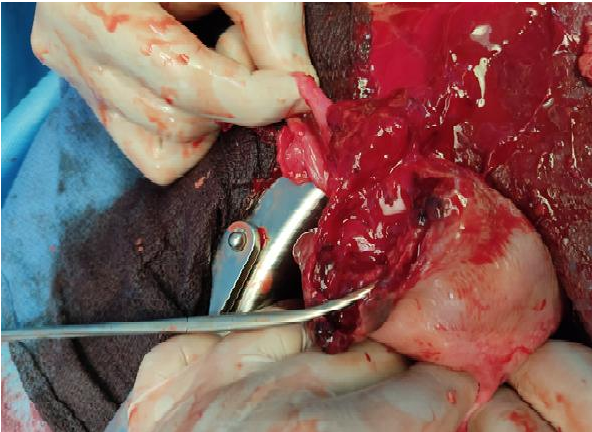
## CLINICAL OBSERVATION

This is a 32-year-old patient, G5P3 (3 live children delivered vaginally and a miscarriage one year ago curetted), without a notable pathological history, who presented to the gynecological emergency department of our training. For abdominopelvic pain evolve for two days over a 12-week pregnancy associated with vomiting and hemodynamic instability. Clinical examination reveals generalized abdominal

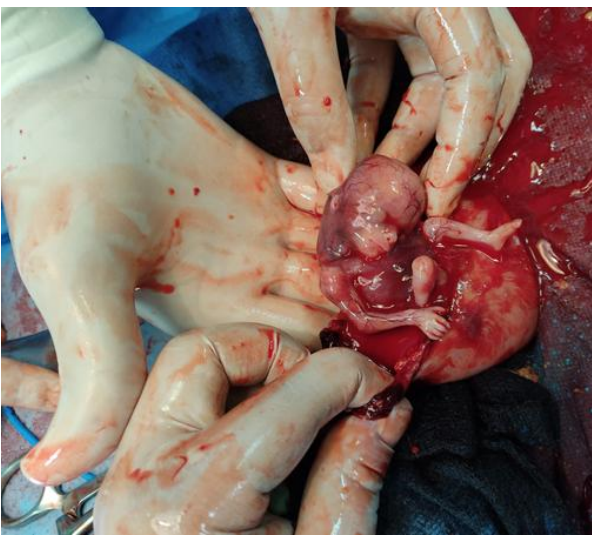defense with gynecological examination a gravid cervix without bleeding from the endocervix and an enlarged uterus, painful on mobilization with cries of Douglas-fir. A pelvic ultrasound performed objectifying a stopped pregnancy of 12 weeks with abundant effusion. Faced with the diagnostic difficulty and hemodynamic instability, an emergency exploratory laparotomy performed revealing a fundic uterine rupture arriving at the left horn with disinsertion of the left tube (figures 1, 2 and 3), thus conservative treatment carried out associated with a left salpingectomy, then the patient was transfused by 3 red blood cells and transferred to intensive care unit, the postoperative consequences were unremarkable then the patient was declared discharged on day 5.



**Fig-1: Fundal uterine rupture arriving at the left horn**



**Fig-2: Fundal uterine rupture with disinsertion of the left tube**



**Fig-3: Fundal uterine rupture in 12-week pregnancy**

## DISCUSSION

Uterine rupture, which remains a concern of the obstetrician in Africa, is defined as any non-surgical solution to the continuity of the uterine wall occurring during pregnancy or during labor. It is conventional to distinguish on the one hand the complete uterine rupture characterized by a total rupture of the uterine wall putting the uterine cavity and the peritoneum in communication (the membranes may or may not be intact) and on the other hand the incomplete uterine rupture. (dehiscence) which is characterized by a rupture of the endometrium and myometrium without involvement of the visceral peritoneum. Its incidence is low in industrialized countries (0.2 - 0.8%). Yet in our developing countries despite all the health practices implemented, uterine ruptures remain frequent.

Uterine rupture can occur at any gestational age, but it occurs in 75 to 80% of cases during labor when attempting a vaginal birth after cesarean section and in the second half of pregnancy. A uterine rupture in a young pregnancy at the start of the 1st trimester therefore remains exceptional in the literature. We are

therefore interested in this type of rupture. Premature uterine rupture (during the 1st trimester) occurs in specific situations (cornual or interstitial pregnancy, history of perforation, pregnancy on a cesarean scar, history of curettage, etc.), however the small number of observations collected would not allow not defining reliable risk factors.

However, in young pregnancies as presented here, its symptomatology remains variable. On the other hand, the occurrence of metrorrhagia would be less frequent but the signs of hemoperitoneum almost constant.

The main interest of abdomino-pelvic ultrasound is to highlight the hemoperitoneum and the diagnosis will only be confirmed intraoperatively during the laparotomy. On this, the methods of surgical repair (hysterectomy or conservative treatment) depend on the anatomical lesions observed, age, parity, socio-economic level, ethnicity, experience of the operator, etc.

Although abdominal pain and vomiting are among the classic signs of UR, it was difficult to think about it given the precocity and nonspecific nature of these symptoms which can also be seen with peritonitis and other syndromes. Ultrasound had a limited role in identifying peritoneal effusion and finally the diagnosis was not made until after laparotomy. Given the young age of the patient, the desire for motherhood, conservative treatment was therefore undertaken although the risk of recurrence at the next pregnancy is of the order of 4 to 19%.

The patient has consented to the publication of these images.

Conflicts of Interest: The authors declare no conflicts of interest.

## REFERENCES

1. Nyengidiki TK, Allagoa DO. Rupture of the gravid uterus in a tertiary health facility in the Niger Delta region of Nigeria: a 5 year review. *Niger Med J.* 2011 Oct;52(4):230–4.
2. Abbas AM, Reda SH, Mustafa NA. Spontaneous first trimester posterior uterine rupture in a multiparous woman with scarred uterus: A case report. *Middle East fertility society journal.* 2018;23:81–83.
3. Bretones S, Cousin C, Gualandi M, Mellier G. Rupture utérine. A propos d'un cas de rupture spontanée à 30 SA chez une primipare. *J Gynecol Obstet Biol Reprod (Paris).* 1997;26(3):324–7.
4. De Tourris H, Henrion R, Delecour M. *Abrégé illustré de Gynécologie Obstétrique.* Masson. 1994;6:506–509.
5. Hofmeyr GJ, Say L, Gülmezoglu AM. Systematic Review: WHO systematic review of maternal

- mortality and morbidity: the prevalence of uterine rupture. *BJOG*. 2005;112:1221–1228.
6. Sentilhes L, Vayssière C, Beucher G, Deneux-Tharoux C, Deruelle P, Diemunsch P. Delivery for women with a previous cesarean: guidelines for clinical practice from the French College of Gynecologists and Obstetricians (CNGOF) *Eur J Obstet Gynecol Reprod Biol*. 2013 Sep;170(1):25–32. Epub 2013 Jun 28.
  7. Eden RD, Parker RT, Gall SA. Rupture of the pregnant uterus: a 53-year review. *Obstet gynecol*. 1986;68:671–674.
  8. Gautier G, Vanbell Y, Vanbogaert LJ. Rupture utérine: réflexion à propos d'un cas spontané à mi grossesse. *J Gynecol Obstet Biol Reprod*. 1985;14:201–209.
  9. Diallo FB, Idi N, Vangeenderhuysen, Baraka D, Hadiza I, Garba M. La rupture utérine à la maternité centrale de référence de Niamey: aspects épidémiologiques et stratégies de prévention. *Dakar Med*. 1998;43(1):74–8.
  10. Parant O. Rupture utérine: prédiction, diagnostic et prise en charge. *J Gynecol Obstet Biol Reprod (Paris)* 2012 Dec;41(8):803–16. Epub 2012 Nov 1.
  11. Kayem G, Raiffort C, Legardeur H, Gavard L, Mandelbrot L, Girard G. Critères d'acceptation de la voie vaginale selon les caractéristiques de la cicatrice utérine. *J Gynecol Obstet Biol Reprod (Paris)* 2012 Dec;41(8):753–71. Epub 2012 Nov 9.
  12. Fitzpatrick KE, Kurinczuk JJ, Alfirevic Z, Spark P, Brocklehurst P, Knight M. Uterine rupture by intended mode of delivery in the UK: a national case control study. *PLoS Med*. 2012;9(3):e1001184. Epub 2012 Mar 13.
  13. Cayrac M, Faillie JL, Flandrin A, Boulot P. Second- and third-trimester management of medical termination of pregnancy and fetal death in utero after prior caesarean section. *Eur J Obstet Gynecol Reprod Biol*. 2011 Aug;157(2):145–9. Epub 2011 Apr 20.
  14. Barger MK, Weiss J, Nannini A, Werler M, Heeren T, Stubblefield PG. Risk factors uterine rupture among women who attempt a vaginal birth after a previous cesarean: a case control study. *J Reprod Med*. 2011 Jul-Aug;56(7-8):313–20.
  15. Mozurkewich EL, Hutton EK. Elective repeat cesarean delivery versus trial of labor: a meta-analysis of the literature from 1989 to 1999. *Am J Obstet Gynecol*. 2000 Nov;183(5):1187–97.
  16. Dewane JC, Mac Cubbin JH. Spontaneous rupture of an unscarred uterus at 19 weeks gestation. *Am J Obstet Gynecol*. 1981 Sep 15;141(2):222–3.
  17. Voogd LB, Wood HB, Powell DV. Ruptured uterus. *Obstet Gynecol*. 1956 Jan;7(1):70–7.
  18. Margulies D, Crampazona JT. Rupture in the intact uterus. *Obstet Gynecol*. 1966 Jun;27(6):863–8.
  19. Chibber R, El-Saleh E, Al Fadhli R, Al Jassar W, Al Harmi J. Uterine rupture and subsequent pregnancy outcome-how safe is it? A 25-year study. *J Matern Fetal Neonatal Med*. 2010 May;23(5):421–4.
  20. O'Connor RA, Gaughan B. Pregnancy following simple repair of the ruptured gravid uterus. *Br J Obstet Gynaecol*. 1989 Aug;96(8):942–4.