

Strangled Rectal Prolapse in Young Adult Treated with the Altemeier Technique: 1 Case Report

Abderrahim Ait Abderrhim^{1*}, Saad Bensliman¹, Tarik Souiki¹, Karim Ibn Mjdoub¹, Imane Toughrai¹, Khalid Mazaz¹

¹Service de Chirurgie Viscérale B, CHU Hassan II Fès, Maroc

DOI: [10.36347/sasjs.2021.v07i10.008](https://doi.org/10.36347/sasjs.2021.v07i10.008)

| Received: 20.08.2020 | Accepted: 29.08.2020 | Published: 12.10.2021

*Corresponding author: Abderrahim Ait Abderrhim

Abstract

Case Report

Rectal prolapse (RP) is an uncommon perineal disease. It is defined as a complete protrusion of the rectum through the anus. The main emergency is the strangulation of RP, which is rare. This complication requires emergent surgery. This case presentation aims to report on therapeutic management and the results of this disease.

Keywords: Strangled Rectal Prolapse Altemeier Technique.

Copyright © 2021 The Author(s): This is an open-access article distributed under the terms of the Creative Commons Attribution 4.0 International License (CC BY-NC 4.0) which permits unrestricted use, distribution, and reproduction in any medium for non-commercial use provided the original author and source are credited.

INTRODUCTION

Rectal prolapse (RP) is defined as a complete protrusion of the rectum through the anus [1, 2]. It concerns the early age of 1 to 3 years as well as the elderly [3]. Its occurrence in adults under the age of 30 is rare, as shown by all publications on the subject [4, 5]. Drug-induced constipation in patients with psychiatric disorders and atrophy or possible pelvic floor weakness in patients with prior pelvic surgery may be contributing factors to rectal prolapse [6,7]. This complication still presents a surgical emergency. This presentation aims to report surgical management and therapeutic outcomes of a strangled RP.

CASE PRESENTATION

This is a 35-year-old patient, followed for psychiatric disorders, who consulted in emergency for the management of rectal prolapse, painful and irreducible. The patient reports the notion of chronic constipation as well as The history of the disease has revealed multiple episodes of externalization reduced by digital maneuvers.

Physical examination; objectified a conscious patient, apyretic, with a slightly distended abdomen. BMI at 28 kg/m². There was no sign of peritonitis. At the anus, there was a prolapse, irreducible, edematous, without signs of ischemia or necrosis measuring 5*10 cm wide (Fig. 1). The lab tests showed a high white blood cell count (18.200/μl) and elevated C-reactive protein (85 mg/dl). After a failure of external manual reduction, the patient underwent emergent surgery.

The procedure consisted of a rectosigmoidectomy with coloanal anastomosis using a perineal approach according to the Altemeier technique. The rectum was sectioned just above the pectineal line (Fig. 2). The colon was descended through the anus (Fig. 2) and was also sectioned at the level of pectineal line. The coloanal anastomosis was manually performed (fig4).

The postoperative follow-up was uneventful. The patient was discharged at post-operative day seven. The patient was examined after a week. There were no physical or biological abnormalities.

DISCUSSION

Rectal prolapse is a rare proctological emergency that often affects women eight times more than men. In 80% of cases, it is associated with anal incontinence. Her onset warrants surgical treatment due to her functional disorders and potential complications.

Strangulation is a rare complication of RP. It occurs in 3-5% of cases, the Delorme procedure is difficult in this situation because of the presence of edema and in case of necrosis becomes a contraindication [8]. The immediate post-operative morbidity of the emergent Altemeier procedure is almost non-existent with a very low possibility of anastomotic leakage [9]. In the long term, however, the risk of recurrence remains higher than that of interventions with the abdominal approach [9].

CONCLUSION

Strangulated RP is a rare complication. Altemeier procedure remains the intervention of choice in this situation.

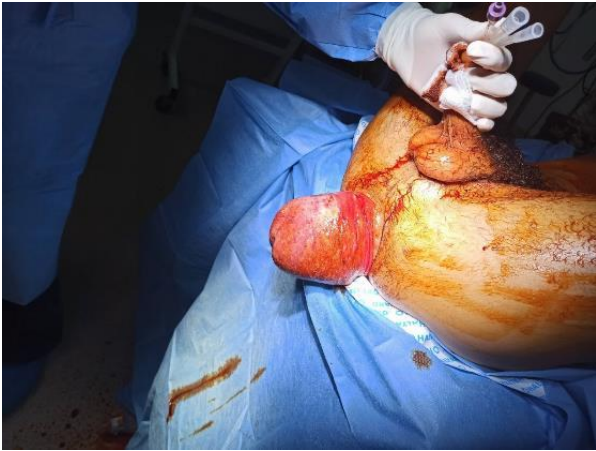


Fig-1: An irreducible and edematous rectal prolapse measuring 5*10 cm wide.

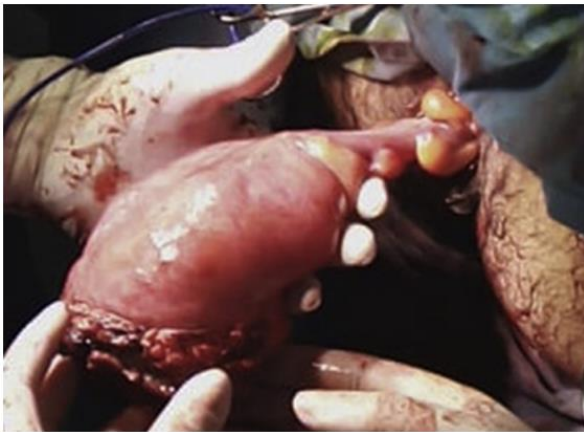


Fig-2 : The recto-sigmoid extraction

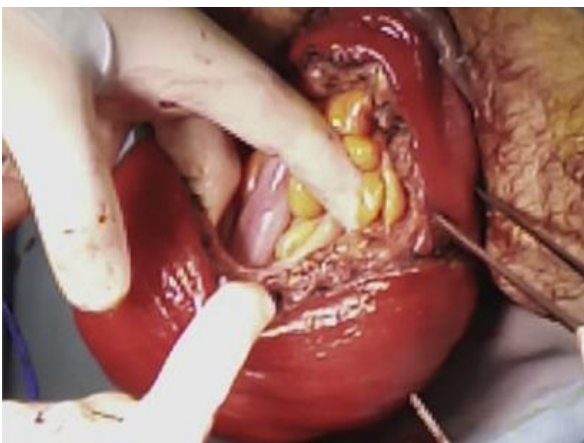

Fig-3: Recto-sigmoid résection

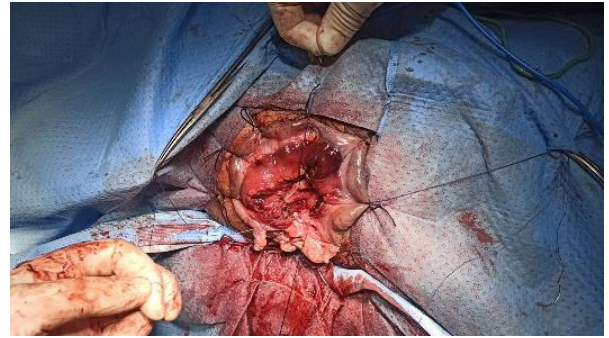

Fig-4: Manual colo-anal anastomosis

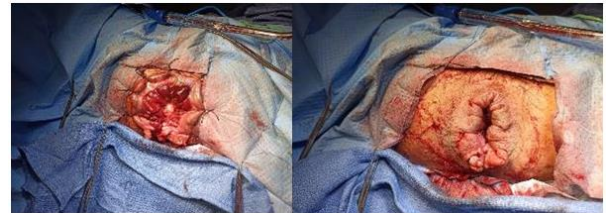

Fig-5: The final view

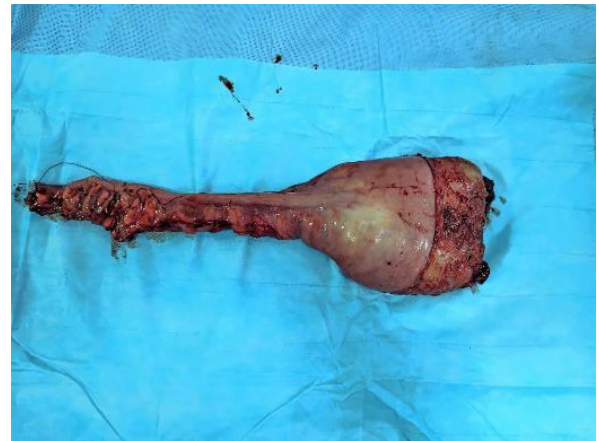

Fig-6: The operatory piece

REFERENCES

1. Yildirim, S., Köksal, H.M.A. (2001). Baykan, Incarcerated and strangulated rectal prolapse, *Int. J. Colorectal Dis*, 16(1); 60.
2. O'Brien, D.P. (2007). Rectal prolapse, *Clin. Colon Rectal Surg*, 20; 125–132 02.
3. Berney, C. R. (2010). Complicated incarcerated rectal prolapse: a surgical challenge in an elderly patient on antiplatelet agents. *Australasian Medical Journal (Online)*, 3(10), 691.
4. Voulimeneas, I., Antonopoulos, C., Alifierakis, E., & Ioannides, P. (2010). Perineal rectosigmoidectomy for gangrenous rectal prolapse. *World Journal of Gastroenterology: WJG*, 16(21), 2689.
5. Définition, O. B. J. E. C. T. I. F. S. (2018). Prolapsus génitaux et incontinence d'urine. *Gynécologie pour le praticien*, 137.
6. Vogel, J. D., de Campos-Lobato, L. F., Chapman, B. C., Bronsert, M. R., Birnbaum, E. H., & Meguid, R. A. (2020). Rectal prolapse surgery in males and females: an ACS NSQIP-based

- comparative analysis of over 12,000 patients. *The American Journal of Surgery*, 220(3), 697-705.
7. Samalavicius, N. E., Kavaliauskas, P., Simcikis, D., & Dulskas, A. (2020). Altemeier procedure for full-thickness rectal prolapse complicated by ischaemic stricture-a video vignette. *Colorectal disease: the official journal of the Association of Coloproctology of Great Britain and Ireland*, 22(7), 842-843.
 8. Liberman, H., Hughes, C., & Dippolito, A. (2000). Evaluation and outcome of the Delorme procedure in the treatment of rectal outlet obstruction. *Diseases of the colon & rectum*, 43(2), 188-192.
 9. Trompetto, M., Tutino, R., Luc, A. R., Novelli, E., Gallo, G., & Clerico, G. (2019). Altemeier's procedure for complete rectal prolapse; outcome and function in 43 consecutive female patients. *BMC surgery*, 19(1), 1-7.
 10. The SCARE. (2018). Statement: Updating consensus Surgical CAse REport (SCARE) guidelines