

## Fibromatosis Colli: What is the Role of Ultrasound?

Hamza Guezri<sup>1\*</sup>, Amina Beddi<sup>1</sup>, Dalale Laoudiyi<sup>1</sup>, Kamilia Chbani<sup>1</sup>, Siham Salam<sup>1</sup>, Lahcen Ouzidane<sup>1</sup>

<sup>1</sup>Department of Pediatric Radiology, IBN ROCHD Hospital, Faculty of Medicine and Pharmacy, Hassan II University, Casablanca 20000, Morocco

DOI: [10.36347/sasjs.2021.v07i10.013](https://doi.org/10.36347/sasjs.2021.v07i10.013)

| Received: 27.08.2021 | Accepted: 04.10.2021 | Published: 16.10.2021

\*Corresponding author: Hamza Guezri

### Abstract

### Case Report

Fibromatosis colli is a rare, usually self-limiting condition caused by a benign tumor in the sternocleidomastoid muscle. The tumor occurs most often during infancy and can be clinically associated with torticollis. Accurate diagnosis of fibromatosis colli is important to avoid unnecessary invasive interventions. Ultrasound is considered the radiological examination of choice for diagnosis, as it is noninvasive, inexpensive, and has 100% sensitivity. We discuss the case of a one-month old child who presented with a head tilt and had ultrasound imaging that favored diagnosis of fibromatosis colli.

**Keywords:** Fibromatosis colli, Sternocleidomastoid, Ultrasound.

Copyright © 2021 The Author(s): This is an open-access article distributed under the terms of the Creative Commons Attribution 4.0 International License (CC BY-NC 4.0) which permits unrestricted use, distribution, and reproduction in any medium for non-commercial use provided the original author and source are credited.

## INTRODUCTION

Fibromatosis colli is a rare, usually self-limiting condition caused by a benign tumor in the sternocleidomastoid (SCM) muscle, most commonly during infancy [1]. It usually appears in the first few weeks of life and can grow rapidly and result in torticollis [2].

We report a case of this disease, and describe the role of ultrasound in the diagnosis.

## CASE REPORT

A one-month-old boy was admitted to our structure with the complaint of cervical swelling, which had been noticed one week before. He was full-term baby and born to a healthy woman after a non

complicated pregnancy by spontaneous vaginal delivery. Birth weight was 3700 g.

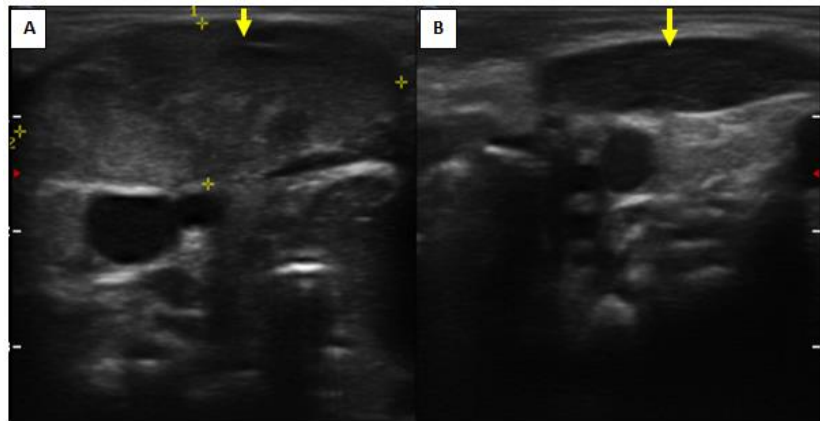
Physical examination found a hard mass of 2 cm in the right cervical region (Figure 1). This mass was responsible for a muscular torticollis.

Cervical ultrasound showed a hyperechoic fusiform enlargement of the right SCM muscle compared to the left SCM, measuring 34x14mm (Figure 2).

The findings of the clinical examination as well as the ultrasonographic appearance were in favor of a fibromatosis colli.

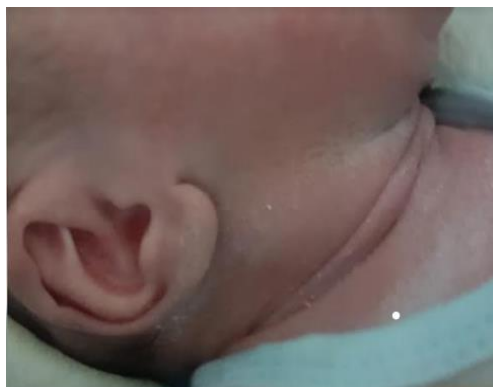

Figure 1: Mass in the right cervical region



**Figure 2:** Cervical ultrasound showed a hyperechoic fusiform enlargement of the right SCM muscle (A) Compared to the left SCM, (B), measuring 34x14mm

## DISCUSSION

Fibromatosis colli is a rare but benign infantile condition, with a reported incidence of 0.3–2% of live births [3]. The average age of presentation is 24 days, and there is a male predominance. It is rarely bilateral and, in 75% of cases, presents on the right [4]. With fibromatosis colli, the SCM muscle appears shortened with fusiform swelling/thickening. This results in torticollis and a subsequent head tilt toward the side of the lesion [1].

The aetiology of the condition is unclear, although an association with birth trauma has been suggested. Other theories include intrauterine malposition, venous occlusion and intramuscular haemorrhage [5].

Differential diagnoses for infants presenting with neck swelling or a head tilt include cervical lymphadenopathy, lymphoma, lipoma or cystic lesions such as lymphangioma or branchial cleft cysts [6]. Early diagnosis of fibromatosis colli is very important to avoid unnecessary invasive diagnostic interventions.

Ultrasound is considered the radiological examination of choice for diagnosis, as it is noninvasive, inexpensive, and has 100% sensitivity [7].

It is generally recommended in the first instance for evaluation of neck masses, especially in paediatrics. The normal sternocleidomastoid is visualized as a linear, hypoechoic structure containing echogenic lines representing normal muscular striations. The typical ultrasonographic aspect of fibromatosis colli is that of focal or diffuse enlargement of the sternocleidomastoid, which may appear homogeneous or heterogeneous [3]. In situations where the diagnosis is doubtful, CT or MRI imaging may offer additional information.

Treatment is usually conservative and consists of observation, passive stretching exercises,

repositioning procedures and physical therapy because the majority of cases resolve spontaneously [1]. For infants whose mobility did not improve after one year of treatment or those who presented at more than 12 months of age, surgical intervention in the form of tenotomy is recommended [3].

## CONCLUSION

Fibromatosis colli is a benign tumor occurring in the SCM muscle of infants. It can be confidently diagnosed with ultrasound, although CT and MRI are alternative options for diagnostic imaging. Treatment consist on conservative measures such as massage and active/passive stretching as well as and physical therapy.

## REFERENCES

1. Valentino, K., & Tothy, A. S. (2020). Fibromatosis Colli: A Case Report. *Advanced emergency nursing journal*, 42(1), 13-16.
2. Ekinçi, S., Karnak, I., & Tanyel, F. C. (2004). Infantile fibromatosis of the sternocleidomastoid muscle mimicking muscular torticollis. *J Pediatr Surg*, 39(9), 1424-1425.
3. Skelton, E., & Howlett, D. J. (2014). Fibromatosis colli: the sternocleidomastoid pseudotumour of infancy. *Paediatr Child Health*, 50(10), 833-835.
4. Tempark, T., Chatproedprai, S., Mahayosond, A., & Wananukul, S. (2012). Fibromatosis colli, overlooked cause of neonatal torticollis: A case report. *International Journal of Pediatric Otorhinolaryngology Extra*, 7(1), 15-17.
5. Rumack, C., Wilson, S., Charboneau, J., & Levine, D. (2011). *Diagnostic Ultrasound*, Vol. 2, 4th edn. St. Louis, MO, USA: Elsevier Mosby, 1721–1725.
6. Oliveira, J. C., Abreu, M. S., & Gomes, F. M. (2018). Sternocleidomastoid tumour in neonate: Fibromatosis colli. *Case Reports*, 2018, bcr-2017.
7. Maddalozzo, J., & Goldenberg, J. D. Pseudotumor of infancy—the role of ultrasonography. *Ear Nose & Throat Journal*, 75, 248–254.