

Left Colon Cancer Metastatic to the Gallbladder: A Case Report

Dr. Bourakkadi Idrissi Mehdi^{1*}, Dr. Layla Tahiri², Dr. Laila Chbani³, Dr. El Bouhaddouti Hicham⁴, Dr. Oussaden Abdelmalek⁵, Dr. Mouaqit Ouadii⁶, Dr. Ait Taleb Khalid⁷, Dr. Benjelloun El Bachir⁸

¹Hassan II University Hospital- Fès Morocco

²Sidi Mohamed Ben Abdellah University and division of Anatomico-pathology at the Hassan II university hospital- Fès Morocco

³Sidi Mohamed Ben Abdellah University and division of Anatomico-Pathology at the Hassan II University Hospital- Fès Morocco

⁴⁻⁸Sidi Mohamed Ben Abdellah University Morocco

DOI: [10.36347/sasjs.2021.v07i03.011](https://doi.org/10.36347/sasjs.2021.v07i03.011)

| Received: 26.02.2021 | Accepted: 20.03.2021 | Published: 25.03.2021

*Corresponding author: Dr. Bourakkadi Idrissi Mehdi

Abstract

Case Report

Gallbladder metastases (GBM) may be rare, but they are not exceptional. An autopsy series has found that up to 6% of cancer patients presented with GBM [1]. Different types of cancer can spread to the gallbladder. The most common primary cancer to is malignant melanoma, which may do so in up to 20% of cases [2]. Other tumors that show clinically significant metastasis to the gallbladder include renal cell carcinoma, adenocarcinoma of the breast, gastric cancer. Only a few cases of GBM were reported in patients with colon cancer. Here we present a case of a 62 years old female patient, admitted for a tumor in the left (descending) cancer, with a mild tenderness in the right hypochondrium. CT scan showed a stage II colon cancer, with gallbladder lithiasis. The case was managed with a laparoscopic colectomy along with a cholecystectomy. Histological examination of the gallbladder revealed an adenocarcinoma of colon origin. Only few cases of colon cancer metastasizing to the gallbladder were reported in English literature [3, 4].

Keywords: Left Colon Cancer Metastatic Gallbladder.

Copyright © 2021 The Author(s): This is an open-access article distributed under the terms of the Creative Commons Attribution 4.0 International License (CC BY-NC 4.0) which permits unrestricted use, distribution, and reproduction in any medium for non-commercial use provided the original author and source are credited.

INTRODUCTION

Metastasis from colon cancer usually affects the liver, the lungs or the peritoneum. Gallbladder metastases remain rather rare. Throughout the literature search we came upon 2 cases of transverse colon cancers with metastasis to the gallbladder masquerading as cholecystitis [3, 4] and one case of cecal cancer [5].

CASE PRESENTATION

A 62-year-old lady, presented with bowel disorder with a mild tenderness at the right hypochondrium. CT-scan objectivated a tumor located in the left colon, without signs of obstruction, alongside

a gallbladder lithiasis, with no signs of cholecystitis. Colonoscopy showed a budding tumor, 45cm up from the anal margin. The patient underwent a laparoscopic surgery for both the colon and the gallbladder. She benefited from a segment resection of the colon with an end-to-end manual anastomosis, and also a cholecystectomy.

The histological examination of the colon showed a poorly differentiated adenocarcinoma with a mucinous component estimated at 15%. However, the gallbladder histological profile corresponded to a secondary location of a colic adenocarcinoma.

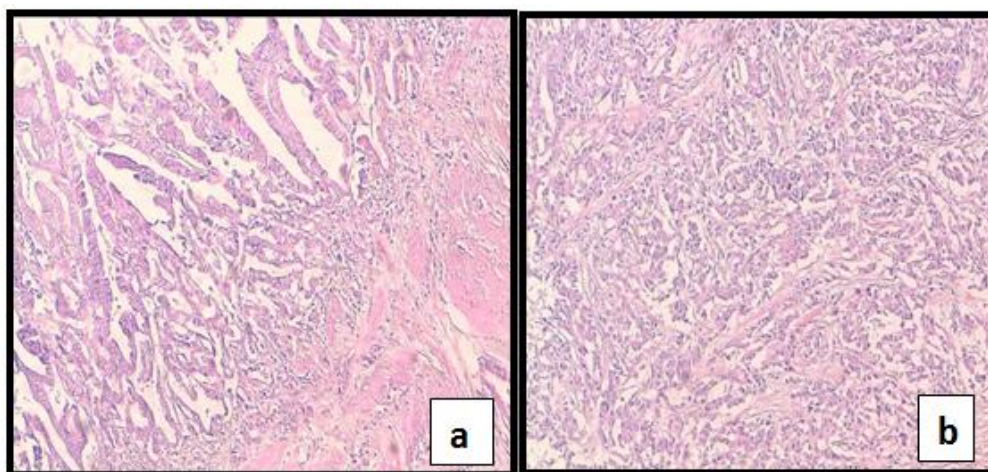


Fig-1: The vesicular wall is infiltrated with a carcinoma proliferation configured into tubes and cribriform architecture (a: HESx100/ b HESx 400)

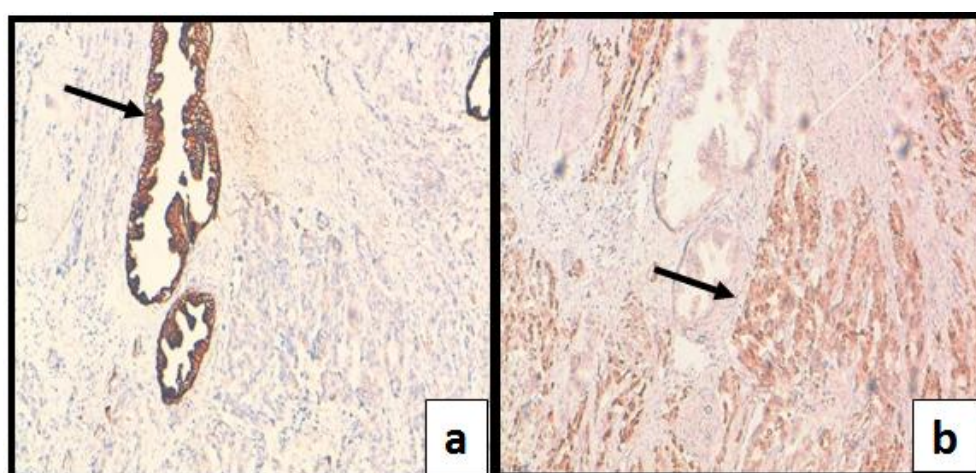


Fig-2: A. Immunolabeling for antibody specific for CK7 marked positive on the vesicular epithelium and negative on the tumor. B. Immunolabeling for antibody specific for CDX2 marked positive on the tumor, and negative on the surface epithelium

Thus, the tumor was classified using TNM staging classification: pT3N0M1. The patient was therefore treated with a protocol of adjuvant chemotherapy.

DISCUSSION

Colon cancer is associated with spread to the liver, the lungs or the peritoneum. This has to do with the fact that the intestinal tract venous drainage happens through the portal circulation. Therefore, the first site of hematogenous spread of colorectal cancer (CRC) is usually the liver, followed by the lungs, bone, and multiple other sites [6].

The gallbladder is a rare site of metastasis of the CRC. Through our search of English literature only a few cases were found [3-5].

Different types of cancer can spread to the gallbladder. The tumor most likely to metastasize to the gallbladder is malignant melanoma, which may do so in up to 20% of cases [7]. Other tumors that show clinically significant metastasis to the gallbladder

include renal cell carcinoma, adenocarcinoma of the breast, gastric cancer [14].

Most patients with gallbladder metastases are asymptomatic, and the metastases are detected on surveillance or staging imaging. Acute cholecystitis is the most common symptomatic presentation of gallbladder metastases, so right upper quadrant pain and a positive Murphy's sign may be present. Jaundice is also common. In our patient, no signs of cholecystitis were reported, only intermittent pain in the upper abdomen.

Adenocarcinomas are epithelial cancers arising in glandular tissues [8]. The etiological diagnosis of these epithelial cancers relies on the expression patterns of two important parameters: CK (7 and 20) and CDX20. CK are keratin proteins found in the cytoskeleton of the epithelium [9, 10]. CK7 is found in many ductal and glandular epithelial tissues, including breast, lung, ovary, and endometrium. CK20 is mainly expressed in the gastrointestinal epithelium, Merkel cells, and urothelium [9, 10].

CK20-positive/CK7-negative pattern is present in the majority of intestinal. Both CK7 positivity and CK20 positivity are present in gastric, pancreatic, and urothelial carcinoma [9, 10].

The homeobox protein-2 (CDX-2) test result was also helpful in our case to further distinguish colon adenocarcinoma from other gastrointestinal and hepatobiliary tumors (*Figure 2*). It is normally expressed within the nuclei of the intestinal epithelium, from the duodenum to the rectum, and it is a sensitive and specific marker of adenocarcinomas of intestinal origin [11, 12].

The CK7-negative/CK20-positive expression pattern with CDX2 positivity is consistent with colorectal primary, while gallbladder cancers tend to be both positive for CK7 and CK20.

Although the primary malignancy is often advanced at the time when gallbladder metastases are diagnosed, cholecystectomy may offer a survival benefit [13].

CONCLUSION

Colon adenocarcinoma metastasizing to the gallbladder is rather rare. Our experience and review of the published cases highlights the need for close screening of any abdominal symptom and a better surveillance of the gallbladder during imaging in cancer patients.

REFERENCES

1. Abrams HL, Spiro R, Goldstein N. Metastases in carcinoma; analysis of 1000 autopsied cases. *Cancer*. 1950; 3:74-85
2. Goldin EG. Malignant melanoma metastatic to the gallbladder. Case report and review of the literature. *Am Surg*. 1990; 56:369-73
3. Chen SC, Hsu CY, Wang SM, Tai TY. Adenocarcinoma of the transverse colon manifested as acute cholecystitis. *The American journal of emergency medicine*. 1994 May 1;12(3):386.
4. Munghate A, Kumar A, Singh H, Singh G, Singh B, Chauhan M. Carcinoma transverse colon masquerading as carcinoma gall bladder. *Journal of gastrointestinal oncology*. 2014 Apr;5(2):E40.
5. Bukhari N, Abdulkader M. Metastatic cecal adenocarcinoma to the gallbladder presenting with acute cholecystitis. *Case reports in oncological medicine*. 2018 Oct 21;2018.
6. Fichna J. *Introduction to Gastrointestinal Diseases Volume 1*. Springer Nature; 2017. <https://www.springer.com/gp/book/9783319490151>
7. Goldin EG. Malignant melanoma metastatic to the gallbladder. Case report and review of the literature. *Am Surg*. 1990; 56:369-73
8. Herrmann H, Bär H, Kreplak L, Strelkov SV, Aebi U. Intermediate filaments: from cell architecture to nanomechanics. *Nature reviews Molecular cell biology*. 2007 Jul;8(7):562-73.
9. Bayrak R, Haltas H, Yenidunya S. The value of CDX2 and cytokeratins 7 and 20 expression in differentiating colorectal adenocarcinomas from extraintestinal gastrointestinal adenocarcinomas: cytokeratin 7-/20+ phenotype is more specific than CDX2 antibody. *Diagnostic pathology*. 2012 Dec;7(1):1-1.
10. Shin JH, Bae JH, Lee A, Jung CK, Yim HW, Park JS, Lee KY. CK7, CK20, CDX2 and MUC2 Immunohistochemical staining used to distinguish metastatic colorectal carcinoma involving ovary from primary ovarian mucinous adenocarcinoma. *Japanese journal of clinical oncology*. 2010 Mar 1;40(3):208-13.
11. Werling RW, Yaziji H, Bacchi CE, Gown AM. CDX2, a highly sensitive and specific marker of adenocarcinomas of intestinal origin: an immunohistochemical survey of 476 primary and metastatic carcinomas. *The American journal of surgical pathology*. 2003 Mar 1;27(3):303-10.
12. <http://www.pathologyoutlines.com/topic/stainsck7.html>.
13. Buchanan MA, Levin B, Veness M. Non-melanoma skin cancer: primary non-surgical therapies and prevention strategies. In *Non-melanoma skin cancer of the head and neck 2015* (pp. 37-51). Springer, New Delhi.
14. Aoki T, Inoue K, Tsuchida A, Aoki T, Kasuya K, Kitamura K, Koyanagi Y, Shimizu T. Gallbladder metastasis of renal cell carcinoma: report of two cases. *Surgery today*. 2002 Jan;32(1):89-92.